

A prospective open-label study of endovascular treatment of chronic cerebrospinal venous insufficiency

Paolo Zamboni, MD,^a Roberto Galeotti, MD,^a Erica Menegatti, RVT,^a Anna Maria Malagoni, MD,^a Sergio Giancesini, MD,^a Ilaria Bartolomei, MD,^b Francesco Mascoli, MD,^a and Fabrizio Salvi, MD,^b *Ferrara and Bologna, Italy*

Objective: Chronic cerebrospinal venous insufficiency (CCSVI) is characterized by combined stenoses of the principal pathways of extracranial venous drainage, including the internal jugular veins (IJVs) and the azygous (AZY) vein, with development of collateral circles and insufficient drainage shown by increased mean transit time in cerebral magnetic resonance (MR) perfusion studies. CCSVI is strongly associated with multiple sclerosis (MS). This study evaluated the safety of CCSVI endovascular treatment and its influence on the clinical outcome of the associated MS.

Methods: Sixty-five consecutive patients with CCSVI, subdivided by MS clinical course into 35 with relapsing remitting (RR), 20 with secondary progressive (SP), and 10 with primary progressive (PP) MS, underwent percutaneous transluminal angioplasty (PTA). Mean follow-up was 18 months. Vascular outcome measures were postoperative complications, venous pressure, and patency rate. Neurologic outcome measures were cognitive and motor function assessment, rate of MS relapse, rate of MR active positive-enhanced gadolinium MS lesions (Gad+), and quality of life (QOL) MS questionnaire.

Results: Outpatient endovascular treatment of CCSVI was feasible, with a minor and negligible complication rate. Postoperative venous pressure was significantly lower in the IJVs and AZY ($P < .001$). The risk of restenosis was higher in the IJVs compared with the AZY (patency rate: IJV, 53%; AZY, 96%; odds ratio, 16; 95% confidence interval, 3.5-72.5; $P < .0001$). CCSVI endovascular treatment significantly improved MS clinical outcome measures, especially in the RR group: the rate of relapse-free patients changed from 27% to 50% postoperatively ($P < .001$) and of MR Gad+ lesions from 50% to 12% ($P < .0001$). The Multiple Sclerosis Functional Composite at 1 year improved significantly in RR patients ($P < .008$) but not in PP or SP. Physical QOL improved significantly in RR ($P < .01$) and in PP patients ($P < .03$), with a positive trend in SP ($P < .08$). Mental QOL showed significant improvement in RR ($P < .003$) and in PP ($P < .01$), but not in SP.

Conclusions: PTA of venous strictures in patients with CCSVI is safe, and especially in patients with RR, the clinical course positively influenced clinical and QOL parameters of the associated MS compared with the preoperative assessment. Restenosis rates are elevated in the IJVs but very promising in the AZY, suggesting the need to improve endovascular techniques in the former. The results of this pilot study warrant a subsequent randomized control study. (*J Vasc Surg* 2009;50:1348-58.)

The blood leaves the brain by using the back propulsion of the residual arterial pressure (*vis a tergo*), complemented by antegrade postural and respiratory mechanisms (*vis a fronte*).^{1,2} The latter consists of increased venous outflow during inspiration, thanks to increased thoracic negative pressure, which improves the aspiration of blood toward the right atrium. The supine position

favors cerebral venous outflow through the internal jugular veins (IJVs). In the upright position, blood is redirected through the vertebral veins (VVs) and the azygous (AZY) vein, which become the predominant pathways in that position.^{1,2}

The extracranial cerebrospinal veins compose a complex valveless system (Fig 1), with the exception of the IJVs. Although the presence of valves in the distal portion of the IJVs has been widely described by anatomists and pathologists, their existence remains underscored in the medical literature. Valves of the distal portion of the IJVs were found in 93% of postmortem studies. Ultrasound imaging easily demonstrated the valve leaflets in 87% of patients, all of which were observed in the distal portion of the IJVs.³

Chronic cerebrospinal venous insufficiency (CCSVI) is a vascular picture recently described and characterized by multiple stenoses of the principal pathways of extracranial venous drainage, especially in the IJVs and the AZY, with opening of collaterals clearly demonstrated by selective venography (Table I).⁴ Phlebographic studies of the IJVs

From the Vascular Diseases Center, University of Ferrara, Ferrara,^a and the Department of Neurology, Bellaria Hospital, Bologna.^b

Competition of interest: none.

This work was presented at the Thirty-first Charing Cross Symposium, London, United Kingdom, Apr 3-7, 2009.

Additional material for this article may be found online at www.jvascsurg.org.

Correspondence: Prof Paolo Zamboni, Director, Vascular Diseases Center, University of Ferrara, 44100 Ferrara, Italy (e-mail: zmp@unife.it).

The editors and reviewers of this article have no relevant financial relationships to disclose per the JVS policy that requires reviewers to decline review of any manuscript for which they may have a competition of interest.

0741-5214/\$36.00

Copyright © 2009 by the Society for Vascular Surgery.

doi:10.1016/j.jvs.2009.07.096

Table I. Venous glossary and abbreviations

CCSVI	Chronic cerebrospinal venous insufficiency
MS	Multiple sclerosis
ECD	Echo color Doppler
IJV	Internal jugular vein
VV	Vertebral vein
AZY	Azygous vein
DCV	Deep cerebral veins; includes internal cerebral vein, basal vein, Galen vein
RR	Relapsing remitting, secondary progressive, primary progressive; they are, respectively, the 3 main clinical course of MS
SP	
PP	
EDSS	Expanded disability status scale
MSFC	Multiple sclerosis functional composite, a score for expressing in a unique Z score the motor function of the upper and lower limb, and the cognitive function
VAS	Visual analog scale for postoperative pain assessment
Aim of physiologic cerebral venous drainage	To permit, by a monodirectional flow, a drainage of a volume of blood per unit of time adequate to the central nervous system. In CCSVI associated to MS the mean transit time calculated in magnetic resonance perfusion study is prolonged.
Reflux	Venous flow reversal to the physiologic direction for a duration >0.88 seconds in the extracranial pathways, and >0.50 seconds in the DCVs. Reflux in the present study was assessed in different body postures and never under Valsalva maneuver.

Fig 1. Schematic representation shows the extracranial cerebrospinal venous system, a complex freely communicating network, with the only valve placed in the proximal left (IJVL) or right internal jugular vein (IJVR). The arrows refer to physiologic flow direction. The percentage rate indicates the location and the prevalence of venous stenoses observed in course of chronic cerebrospinal venous insufficiency. AZY, azygous vein; IVC, inferior vena cava; L REN, left renal vein; LV, lumbar veins; PterPlex, pterygoid plexus, one of the major intra-extracranial venous collateral pathways; SVC, superior vena cava; VPlex, vertebral plexus; VV, vertebral vein.

and AZY systems demonstrated that venous stenoses were likely to be truncular venous malformations.⁵

CCSVI is strongly associated with multiple sclerosis (MS), a disabling neurodegenerative and demyelinating disease considered autoimmune in nature; however, CCSVI has not been linked with miscellaneous other neurologic conditions or in healthy controls.^{4,6}

In CCSVI, substitute circles are activated that bypass blocked veins and thereby reduce resistance to drainage, avoiding intracranial hypertension.^{4,6-8} The time of venous outflow is longer than normal, however, leading to insufficient venous drainage, as confirmed by the mean transit time measured in magnetic resonance (MR) perfusion studies, even in normally appearing white matter.⁷⁻⁹ Finally, MR venography¹⁰⁻¹³ and postmortem studies¹⁴ have

demonstrated a topographic correspondence between MS plaques and the cerebral venous system.

CCSVI can be noninvasively diagnosed by combined transcranial and extracranial echo color Doppler (ECD) that measures five variables indicative of CCSVI (Appendix, online only)^{4,6}:

1. reflux in the IJVs or in the VV, or both with the head in any position;
2. reflux in the deep cerebral veins;
3. high-resolution B-mode evidence of IJV stenoses;
4. flow not detected by Doppler in the IJVs or VVs, or both; and
5. reverted postural control of the main cerebral venous outflow pathways,

We previously reported that the CCSVI diagnosis needs to fulfil at least two of the five ECD indicators of CCSVI.^{4,6} The detection of two or more criteria in the same individual has not been observed in healthy controls, but perfectly overlapped with the diagnosis of clinically definite MS in a cross-sectional evaluation of patients with a median disease duration of 6 years.⁶

MS is classified into three main clinical courses: (1) relapsing remitting (RR), characterized by acute exacerbations of the disease, followed by complete or partial recovery ≤ 1 month; (2) secondary progressive (SP), characterized by progressive deterioration of neurologic function

after several years of the RR course; and (3) primary progressive (PP), characterized by the absence of attacks, with a progressive clinical course starting from the initial onset.^{15,16}

The hospital's ethical committee authorized phlebographic investigation of patients with positive ECD screening for CCSVI in February 2007, allowing for contemporaneous endovascular treatment of extracranial venous stenosing lesions if radiologically demonstrated. We treated 65 consecutive MS patients whose clinical, hemodynamic, and venographic characteristics have been previously reported.⁴

The purpose of this study was to evaluate the safety, feasibility, and vascular outcome of percutaneous transluminal angioplasty (PTA) in treating extracranial venous obstructive lesions, as well as the influence on the clinical outcome of associated MS with a mean follow-up of 18 months.

PATIENTS AND METHODS

We selected 65 consecutive patients affected by clinically defined MS diagnosed according to the revised McDonald criteria (Appendix, online only).¹⁶ The following selection criteria were used:

- age 18 to 65 years;
- Expanded Disability Scale Score (EDSS)¹⁷ ranging from 0 to 6.5 (Appendix, online only);
- diagnosis of MS according to the revised McDonald criteria (Appendix, online only)¹⁶;
- therapy with currently Food and Drug Administration (FDA)-approved disease-modifying treatments;
- evidence of more than two ECD parameters (listed above) of suspicious abnormal extracranial cerebral venous outflow^{4,6}; and
- normal renal function.

Exclusion criteria were:

- Relapse, disease progression, and steroid treatment in the 30 days preceding study entry (all conditions significantly modify clinical parameters, rendering unreliable any postoperative assessment);
- Pre-existing medical conditions known to be associated with brain pathology, including neurodegenerative disorder, cerebrovascular disease, and history of alcohol abuse;
- abnormal renal function; and
- refusal to undergo the endovascular treatment.

Hemodynamic study of cerebrospinal venous drainage.

The selected patients underwent a noninvasive and accurate screening test to ascertain the presence of CCSVI, based on an ECD investigation protocol previously described.^{4,6} MS patients undergoing ECD investigations of cerebrospinal venous return were positioned on a tilt bed. The investigation was focused on the detection of the five Doppler hemodynamics parameters as mentioned above (Appendix, online only).

Selective venography. Patients underwent selective venography of the lumbar, left renal, AZY, and IJVs by catheterization of the left iliac femoral venous axis.⁴ PTA was performed exclusively at the levels of AZY and IJVs when significant stenoses were detected. As previously reported, we considered a significant stenosis to be any venous lumen reduction >50%.^{4,18,19} Morphology malformations were defined as follows:

- Annulus refers to significant circumferential stenosis of the whole venous wall.
- Septum/valve malformation refers to anomalous valve apparatus causing significant flow obstacles at the level of the IJVs junction with the brachiocephalic/anonymus trunk.
- Hypoplasia refers to underdeveloped long venous segments.
- Twisting refers to severe stenoses in consequence of a twisted venous segment.
- Membranous obstruction refers to a membrane almost occluding a vein.
- Agenesis refers to the complete anatomic absence of a venous segment

PTA of the AZY and IJV. The angiographic catheter (5F Head Hunter, 90-cm-long, Terumo Europe, Leuven, Belgium) was moved from the inferior to the superior vena cava, and venous pressure was measured with a manometer. Catheterization proceeded to the AZY outlet into the superior vena cava for a few millimeters, and retrograde contrast medium was injected manually to view any possible downward reflux in the vein.

With the help of a hydrophilic guidewire (0.035-inch diameter Radiofocus Guide Wire M, Terumo Europe), the catheter was moved inside the AZY until it neared the confluence with the hemi-AZY, and venous pressure was measured. A subtractive digital selective phlebography of the AZY was done, with a right posterior oblique projection (range, 15°-25°) and contrast medium (IOMERON 300 mg/mL, Bracco s.p.a. Italia) flow (3 mL/s) and quantity (10 mL) aimed at respecting the normal antegrade flow of the vein and at identifying any refluxes or stenoses corresponding with the AZY arch.

A more complete, retrograde morphologic study of the AZY can be performed with greater flows (8 mL/s) and quantities (30 mL). In this way it is possible to achieve complete opacification of the system of origin of the AZY and hemi-AZY veins up to the ascending lumbar veins.

The presence of anatomic obstructive anomalies such as membranous obstruction, annulus, or twisting required an endovascular correction (Fig 1 and 2). As the first procedure, we always attempted PTA using compliant-type balloon catheters because their greater flexibility allowed for insertion in the narrow arch of the AZY. Balloons (Opta Pro, Cordis Europa, Roden Netherlands) that are 8 to 10 mm in diameter and 2-, 4-, and 6-cm in length were used and inflated to a maximal pressure of 6 atm. Inflation was maintained for 30 to 60 seconds and repeated several times. At the end of the therapeutic procedure, the postoperative

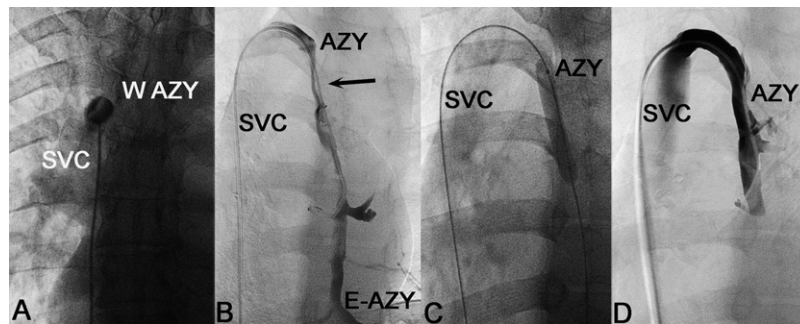


Fig 2. **A**, Selective venography shows a membranous obstruction of the outlet of the azygos (*W-AZY*) vein into the superior vena cava (*SVC*). **B**, In the same patient, the outflow is further hampered by a hypoplasia below the arch (*arrow*), with a long reflux extended downward the hemiazygos (*E-AZY*). **C**, Endovascular percutaneous transluminal angioplasty. **D**, Postoperative results show reflux disappearance and restored venous calibre.

venous pressure measurement and selective phlebography of the AZY or IJVs, or both, were repeated to document the immediate outcome of the treatment (Fig 2).

The same Head Hunter catheter used for the AZY was reinserted for the selective phlebography of both the IJVs, using the hydrophilic guidewire to pass through the distal often-stenotic IJV outlet. IJVs phlebography (flow, 3 mL/s; quantity, 10 mL) was then initiated in anteroposterior projection, sometimes completed with an oblique view, to detect the presence of stenoses or other more specific pathologies such as osseous compression and valves malformation.

The first attempt for the endovascular dilatation of stenoses in the IJV was always made by using the Opta Pro compliant balloon, with a diameter of 10 to 12 mm and a length of 4 mm, supporting a dilation pressure of 6 atm. A high-pressure balloon (Blue Max, Boston Scientific/Mediatech, Natick, Mass), 10 × 2 mm, 18 to 20 atm, was subsequently used in case of annulus if the operators considered the result achieved with the first attempt was unsatisfactory.

Vascular outcome measures. Vascular outcome measures are described separately from the neurologic outcome measure of the associated MS, which was independently assessed by our neurologic team. We evaluated the following vascular variables:

1. venous pressure expressed in cm H₂O measured preoperatively and postoperatively by means of a manometer in the superior vena cava, in the AZY, and in both IJVs;
2. the postoperative course and rate of complications; in particular, we assessed patients' tolerance to the procedure, investigated pain by the means of the validated visual analogue scale (VAS),²⁰ and also postoperative thrombosis, major and minor bleeding, and adverse effects from contrast media; and
3. patency rate by using a ECD surveillance at 1, 3, 6, 12, 15, and 18 months, assessing the same preoperative variables.^{4,6} At the end of the 18 months of follow-up, patients with ECD-suspected restenosis underwent venography as well as an eventual second PTA treatment

Neurologic outcome. Neurologic outcome was assessed by the nonblinded team of neurologists who followed up the clinical course of associated MS. The outcome measures are those usually used in clinical trials evaluating MS treatment:

1. Disease severity. When a treatment evaluation is contemplated, MS severity should be scored by means of the Multiple Sclerosis Functional Composite (MSFC)^{21,22} instead of the widely used but insufficiently detailed EDSS.¹⁷ The MSFC gives the comprehensive index Z for scoring the motility of upper and lower extremities as well as cognitive function (Appendix, online only). The same physician (A. M.) performed the MSFC preoperative and postoperative assessment always at the same hour and in the same location and condition.
2. Relapse in RR patients. This clinical variable is expressed by the proportion of patients who were relapse-free at 1 year and by the annualized relapse rate compared with that reported during the 2 years preceding PTA.²³⁻²⁵
3. Quality of life (QOL). This was evaluated by using a validated 54-item questionnaire, the Multiple Sclerosis Quality of Life-54 Instrument, addressed to MS patients and subdivided in two parts evaluating physical and mental status.²⁶

Statistical analysis. Data are expressed as mean and standard deviation. Differences in preoperative and postoperative pressure were assessed with the two-tailed Mann-Whitney test. Differences in QOL and MSFC were assessed with one-way analysis of variance. Differences in the annualized relapse rate and in rate of patients relapse free, as well as in the number of contrast gadolinium positive (Gad+) lesions were assessed by means of two-tailed Fisher exact test. Finally, analysis of recurrent stenoses in the AZY and in the IJVs was performed by the survival curve and Kaplan-Mayer estimation. Values of *P* < .05 were considered to be significant.

Table II. Patient demographics

Variable	All patents (n = 65)	MS progression		
		RR (n = 35)	SP (n = 20)	PP (n = 10)
Age, y	41.7 ± 12.2	34.8 ± 8.3	46.8 ± 9.7	55.6 ± 12.2
Sex				
Male/female	30/35	16/19	9/11	5/5
Male, %	46	46	45	50
MSFC	-0.0003 ± 0.6	5.5e-18 ± 0.7	0 ± 0.8	-0.001 ± 0.5
EDSS	3 ± 2.3	1.7 ± 0.9	5 ± 2.2	4.7 ± 2
Disease duration, y	8.6 ± 7.1	5.1 ± 4.4	14 ± 7.8	9.3 ± 6.3

5.5e-, Infinitesimal negative baseline value of the MSFC; EDSS, Expanded Disability Status Scale; MS, multiple sclerosis; MSFC, Multiple Sclerosis Functional Composite; RR, relapsing-remitting; SP, secondary progressive; PP, primary progressive.

Table III. Morphology and location of the stenosing venous truncular malformations

Location	Normal segment	Annulus	Septum/valve malformation	Hypoplasia ^a	Twisting	Membranous obstruction	Agnesia
AZY, No.	9	0	9	6	0	31	0
Distal AZY, No. ^b	50	0	0	3	12	0	0
Lumbar, No.	59	0	0	1	0	0	5
IJV-r, No.	13	18	30	4	0	0	0
IJV-l, No.	4	34	28	4	0	0	0

AZY, Azygous; IJV-l, internal jugular vein, left; IJV-r, internal jugular vein, right.

^aHypoplasia can be combined with other malformations in the AZY and in the IJV-l.

^bDistal AZY is intended below the arch.

RESULTS

Patient population. Demographics of the patients and baseline MSFC and EDSS scores are given in Table II.

Feasibility and safety of the procedure. All procedures were performed in day surgery and under local anesthesia. The procedure was well tolerated, with a mean VAS score of 3.4 ± 0.3 . No operative or postoperative complications, including vessel rupture, thrombosis, or side effects to the contrast media, were recorded. Minor hemorrhages with hematomas at the vascular access sites occurred occasionally. Six patients reported postoperative headache that was transitory and spontaneously resolved. Postprocedural observation lasted an average of 4 hours, and patients were discharged with a compressive dressing in the left groin, the preferred site of vascular access. All patients were administered a prophylactic dose of low-molecular-weight heparin for the subsequent 3 weeks.²⁷

Results of selective venography. In MS patients, venous stenoses in the main cerebrospinal outflow pathways were never found to be isolated. Rather, they were combined in the IJVs, AZY, and lumbar systems, defining four main patterns of distribution⁴:

Type A pattern (30%) is characterized by significant stenosis of the proximal AZY or of one of the two IJVs, with a compensatory contralateral IJV that appears with an ample cross-sectional area; it was observed in 10 of 35 RR patients, in five of 20 SP patients, but never in PP patients.

Type B pattern (38%) is characterized by significant stenoses of both IJVs and the proximal azygous; it was

observed in 19 of 35 RR patients, in nine of 20 SP patients, and in one of 10 PP patients.

Type C pattern (14%) is characterized by bilateral stenosis in both IJVs, with a normal AZY system; it was observed in four of 35 RR patients, in five of 20 SP patients, but never in PP patients.

Type D pattern (18%) is characterized by the multilevel involvement of the AZY and lumbar systems. Association with the IJVs was observed in approximately 50% and caused an additional obstruction in these patients. It was observed in two of 35 RR patients, in one of 20 SP patients, and in nine of 10 PP patients.

Table III reports the phlebographic morphology of the truncular venous malformations. Membranous obstructions of the outlet of the AZY into the superior vena cava were the most frequent presentation in this segment (Fig 2). Twisting in the AZY was observed in 12 of 65 patients (Fig 3). Most stenoses in the IJVs were morphologically related to the presence of annulus (Fig 4). Septum was the second most frequent presentation, which also includes malformations of the jugular valve leaflets (Fig 5). In fact, valve cusps were sometimes fixed and immobile, or even inverted with respect to the heart position (Fig 5). Finally, the lumbar veins were rarely affected, and the most frequently observed malformation was agnesia.⁴

Vascular outcome. Values of venous pressure in segments showing a stenosis were more elevated but not significantly different from those that showed a normal venogram. In contrast, postoperative pressure values were significantly lower in all segments ($P < .0001$). Figure 6

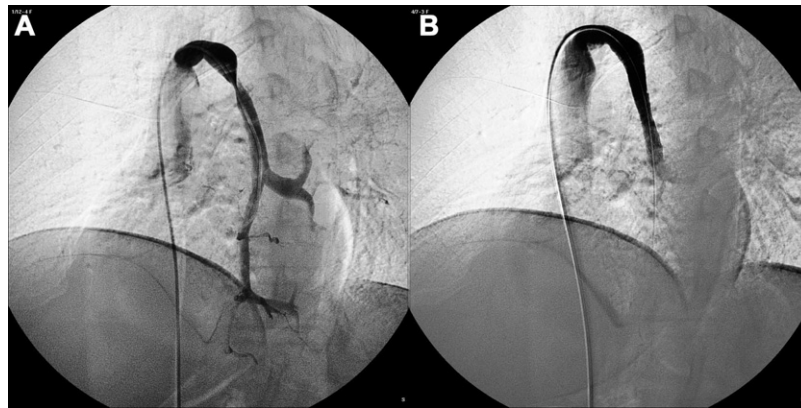


Fig 3. Selective venography shows (A) a dramatic twisting of the azygous vein just below the arch with reflux toward the spine and (B) endovascular correction by stent insertion and reflux disappearance.

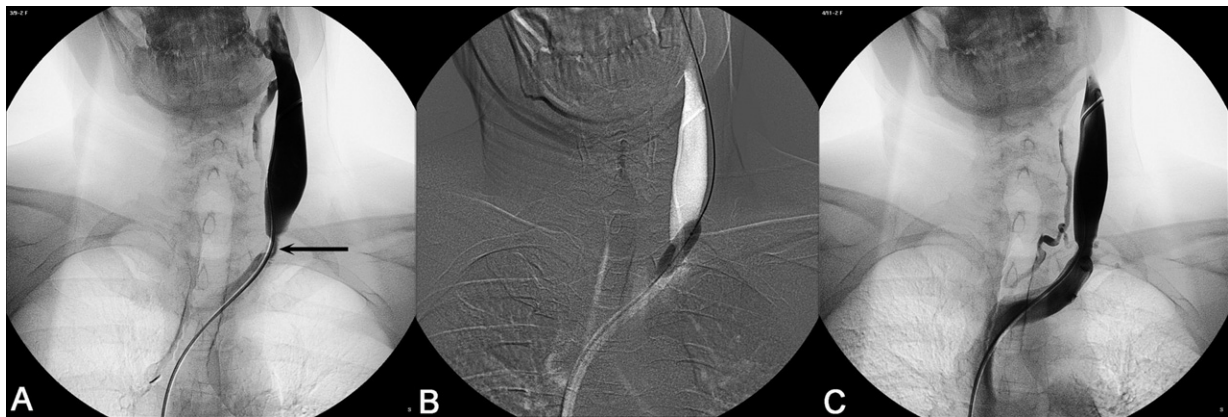


Fig 4. A, Selective venography shows a closed annular stenosis of the proximal left internal jugular vein (*arrow*). B, Percutaneous transluminal angioplasty was performed by road map facility. C, Selective venography shows the postoperative result.

lists the preoperative and postoperative pressure values measured in cm H₂O in the AZY and in both IJVs.

The patency rate was strictly dependent on the type and location of the truncular venous malformations that have been described. PTA showed the best outcome in the AZY, with a cumulative rate of 96%, including procedures for membranous obstructions, twisting, and hypoplasia (Fig 7). Particularly, membranous obstructions showed 100% patency rate (Fig 1). Twisting was observed in 12 of 65 patients, and in one patient was not successfully resolved by means of simple PTA but required placement of a metallic, self-expanding stent having a diameter of ≥ 12 mm and a length that varied according to the patient's anatomy picture (Fig 3), whereas a second case retwisted. Hypoplasia favorably responded in five of six patients (Fig 2).

The real problem was primary patency after the PTA technique at the level of the IJVs. The survival curve of Fig 7 shows the cumulative distribution of restenosis at 18 months (47%), with an overall patency rate of 53%. The curve indicates the peak of restenosis occurrence at about 8

to 9 months after the procedure. The risk of restenosis in the IJVs was 16-fold higher compared with the AZY after PTA in CCSVI cases (odds ratio [OR], 16; 95% confidence interval [CI], 3.5-72.5 $P < .0001$).

Venography, performed at the end of the 18 months of follow-up in patients with ECD-suspected restenosis, confirmed in 100% of cases the rate of restenosis reported above.

Neurologic outcome. Outcomes for disease severity, relapse in RR patients, MRI outcome measures, and QOL were evaluated:

- Disease severity: In RR patients, the MSFC showed highly significant improvement at 18 months ($P < .008$; Table IV). MSFC showed significant although limited improvement after the first 6 months in both PP and in SP clinical courses, but at 18 months showed no improvement respect to baseline (Table V).
- Relapse in RR patients: The rate of patients who were relapse-free in the year preceding endovascular treat-

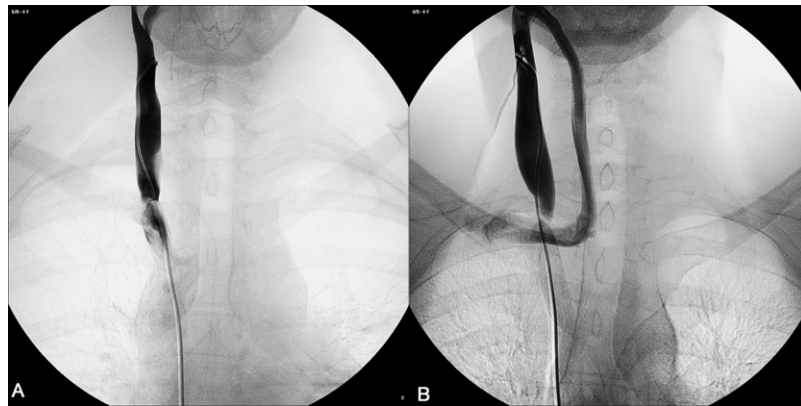


Fig 5. Selective venograph shows (A) the septum of the right internal jugular vein and (B) the septum of the right internal jugular vein with a significant collateral circle.

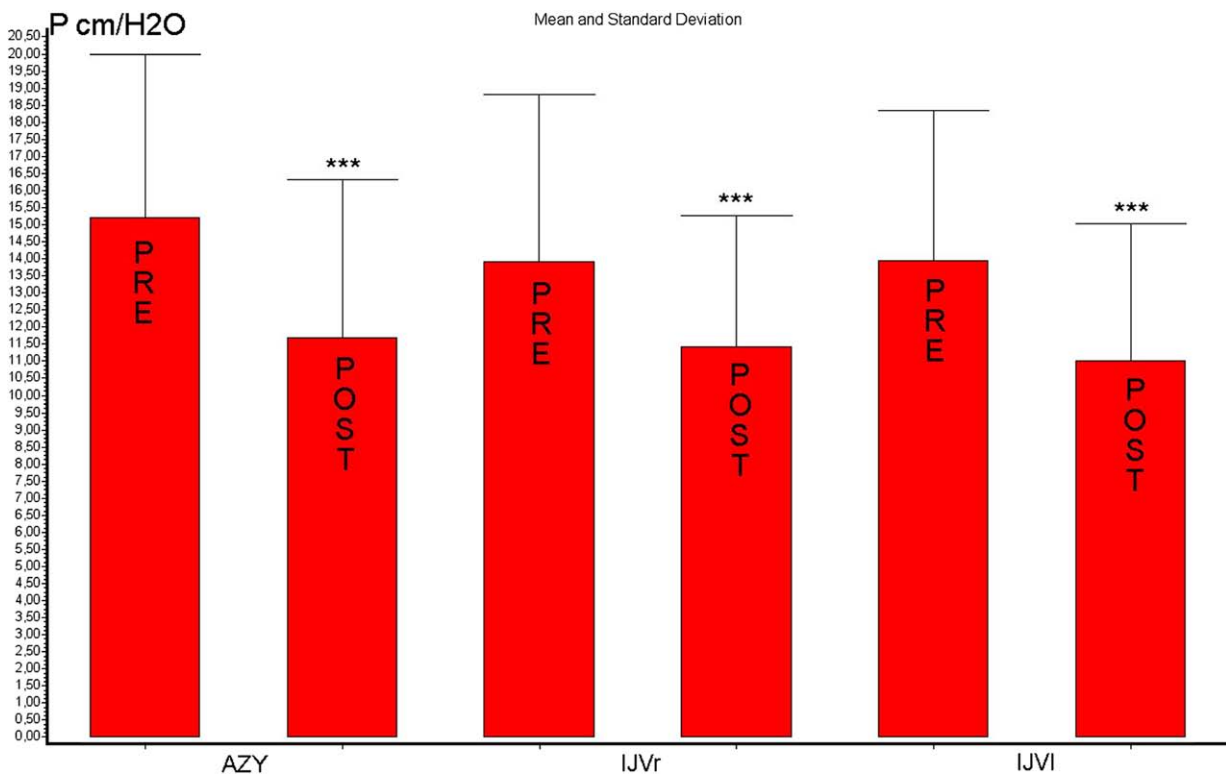


Fig 6. Venous pressure decreased significantly postoperatively. Values are expressed as mean and standard deviation (error bars). *** $P < .001$.

ment was only 27%, highly significantly different from the 50% assessed in the postoperative outcome (Table IV), whereas the annualized relapse rate (comparing rate of relapse before and after PTA) was not significantly different in the RR patients (Table IV). Finally, all RR patients with postprocedural patency of the IJVs and AZY were always relapse-free.

- MRI outcome measure: The rate of patients with active gadolinium-enhanced lesions at MRI decreased significantly from 50% to 12% ($P < .0001$; Table IV).

- QOL: In RR patients, mental and physical QOL improved significantly ($P < .001$ and $P < .003$, respectively; Table IV). In PP and SP patients, QOL showed limited mental and physical improvement after the first 6 months but not at 18 months (Table V).

DISCUSSION

Chronic venous diseases and CCSVI associated with MS have many similarities in the molecular and physiologic mechanisms involved in iron-mediated disease develop-

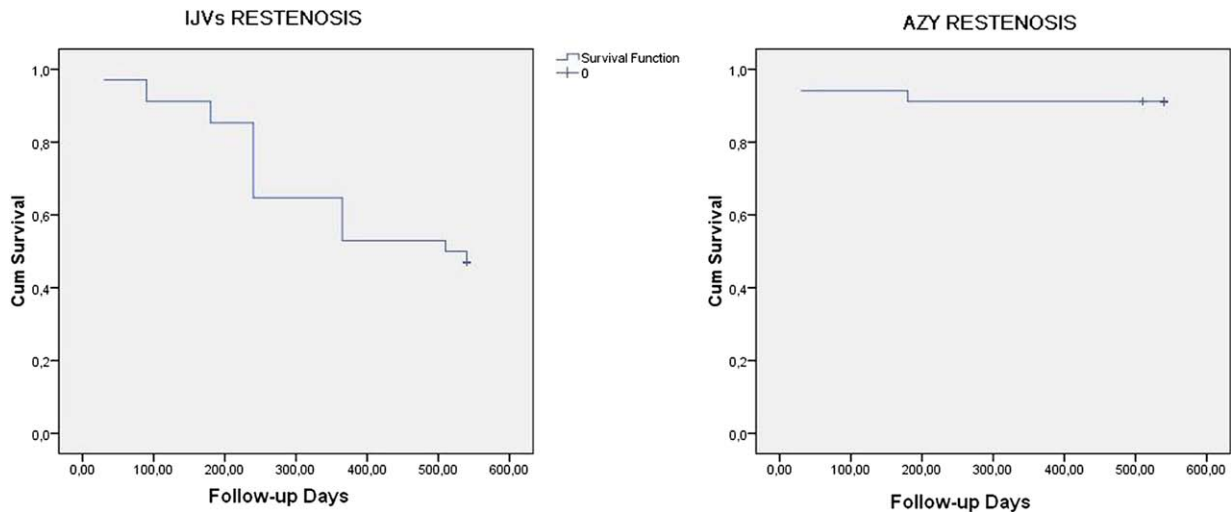


Fig 7. Kaplan-Meier estimates show the (Left) cumulative patency rate detected in the internal jugular veins (IJVs) and (Right) at the azygous (AZY) vein at 18 months of follow-up.

Table IV. Preprocedural and postprocedural changes in clinical, magnetic resonance imaging, quality of life, and disability scale in relapsing remitting patients

Variable	Pre-PTA	18-month FU	P
Annualized relapse rate	0.9 ± 0.8	0.7 ± 1	.11
Patients free of relapse, %	27	50	<.0014
Patients with MRI Gad+ lesions, % ^a	50	12	<.0001
MSQOL PHC, mean ± SD ^b	66 ± 18	84 ± 16	.0097
MSQOL MHC, mean ± SD ^c	61 ± 22	82 ± 13	.003
MSFC, mean ± SD ^d	5.5e-18 ± 0.7	0.65 ± 0.5	.008

5.5e-, Infinitesimal negative baseline value of the MSFC; FU, follow-up; NS, not significant; PTA, percutaneous transluminal angioplasty.

^aMagnetic resonance imaging-active gadolinium-enhanced lesions.

^bMSQOL PHC: Score of physical health component of the Multiple Sclerosis Quality of Life 54-item Instrument.

^cMSQOL MHC: Score of mental health component of the Multiple Sclerosis Quality of Life 54-item Instrument.

^dMSFC: Multiple Sclerosis Functional Composite a disability scale expressed by the Zeta score, which integrates evaluation of the motility of the upper and lower extremities with cognitive function.

ment. In chronic venous disease, the chain is triggered by altered venous hemodynamics with consequent disturbed microcirculation, bringing about erythrocyte extravasation as a primary source of iron stores. In CCSVI associated with MS, extracranial venous obstruction presumably overloads cerebral microcirculation because histology confirms erythrocyte extravasation in brain plaques of MS just at the perivenular level.^{28,29}

CCSVI is a vascular picture characterized by venous obstructive lesions affecting the main extracranial cerebral venous outflow pathways. Selective venography enabled us to perform a first treatment of the identified venous obstructive lesion at the time of the diagnostic evaluation by

Table V. Preprocedural and postprocedural changes in measure of quality of life and of disability in secondary progressive (SP) and primary progressive patients (PP)

Status	Pre-PTA	18-month FU	P
SP			
MSQOL PHC ^a	47 ± 12	62 ± 16	<.08
MSQOL MHC ^b	65 ± 3	70 ± 18	>.10
MSFC ^c	0 ± 0.8	0.5 ± 0.6	>.10
PP			
MSQOL PHC	53 ± 13	66 ± 12	<.03
MSQOL MHC	60 ± 15	78 ± 9	<.01
MSFC	-0.001 ± 0.5	0.04 ± 0.6	>.10

FU, Follow-up; NS, not significant; PP, primary progressive course; PTA, percutaneous transluminal angioplasty; SP, secondary progressive course.

^aMSQOL PHC: Score of physical health component of the Multiple Sclerosis Quality of Life 54-item Instrument.

^bMSQOL MHC: Score of mental health component of the Multiple Sclerosis Quality of Life 54-item Instrument.

^cMSFC: Multiple Sclerosis Functional Composite, a disability scale expressed by the Zeta score, which integrates evaluation of the motility of the upper and lower extremities with cognitive function.

means of balloon angioplasty in 65 consecutive patients affected by CCSVI.⁴ We observed the patients for 18 months, monitoring the vascular and neurologic outcomes of associated MS. The main finding of our study is that endovascular treatment of CCSVI by means of simple PTA is feasible and safe. The procedure is well tolerated and produces a negligible rate of minor complications.

Venous pressure measurement is a key point in our study. With patients supine, values of pressure recorded in segments showing a stenosis were more elevated but not significantly different from those registered in segments with a normal venogram. This result is not surprising. All patients presented stenoses, although differently located, in a freely communicating venous tree. Presumably, this af-

fects the measurements in venous segments with no evidence of stenoses.

In contrast, pressure in the AZY and in the IJVs was previously measured as being significantly higher in patients vs controls, testifying to the hemodynamic significance of venous obstruction.⁴ In the present study, PTA significantly decreased venous pressure in all the treated segments (Fig 6), immediately correcting one of the more obvious hemodynamic variables.

Our findings are consistent with a role of venous hypertension in the complex pathogenesis of MS, which has only been hypothesized to date.^{30,31} Raised venous pressure can stretch vein walls sufficiently to separate the tight junctions between the endothelial cells that form the blood–brain barrier.³² Colloids and erythrocytes can then pass through the exposed porous basement membranes and participate in the inflammatory process.^{28,29} Fibrin cuff, the histologic marker of venous hypertension in chronic venous insufficiency of the lower limbs,³³ has been also demonstrated in the veins of the plaques of MS.^{28,29}

In addition, as previously reported, the four patterns of venous obstruction are differently distributed among the categories of MS patients. A distribution among the A, B, and C patterns of CCSVI was found in 83% of RR patients and 92% of SP patients, whereas type D was found in 90% of PP patients. Thus in the PP course of MS, characterized by a plaque topography in the spinal cord, the stenoses were found just in the veins draining the spinal cord.⁴ This suggests that the pattern of CCSVI influences the distribution of lesions and the clinical course of MS, contributing to also explain, as will be discussed, the different postoperative outcomes in the three subgroups of MS patients.

Second, the vascular outcome measure of the AZY treatment appears to be quite promising.

The subsequent long-term postoperative course depended on the segment and the morphology of the venous malformation. The AZY was affected in 86% of patients, mostly involving membranous obstruction of the junction with the superior vena cava or twisting, or less frequently, septum and hypoplasia (Table III). ECD showed reflux or outflow block, or both, in the VVs in such cases, confirmed by venography that documented the morphology of the AZY obstruction as well as a reflux directed downward and also towards the spine (Fig 2).⁴ Membranous obstruction of the outlet was observed in nearly half of the patients, and our study demonstrated an effective treatment by means of simple PTA, followed by an 18-month patency rate of 100%. The membranous obstructions morphologically resemble the membranous obstruction of the inferior vena cava described in patients with primary Budd-Chiari syndrome, and our results seem to be comparable with the successful rate reported after PTA at that level.^{18,19,34}

Similar venous strictures, sometimes complicated by subsequent venous thrombosis, have also been described and successfully treated in the inferior vena cava and in the iliac veins.¹⁹

As for their origin, this area is considered to be prone to developmental anomalies such as membranous obstruc-

tions and strictures. Parts of the formative venous network disappear or remain as embryonic rudiments; other parts are recognizable in the adult as named structures, such as the azygos, hemiazygos, accessory hemiazygos, and thoracolumbar veins.¹⁹

We need further studies to definitely elucidate if the malformations we observed can be considered of congenital or developmental origin. If this hypothesis should be confirmed, we cannot consider CCSVI as a simple disease association but rather a potential trigger for MS development.

AZY twisting is a venous malformation that has never been previously reported, to our knowledge. PTA was successful in reverting AZY twisting in 11 of 12 patients, whereas in one patient, stent insertion was required to eliminate and repair twisting (Fig 3). Among the remaining 11 patients, the AZY retwisted in one patient at 6 months. The patency rate was also satisfactory for PTA treatment of azygos hypoplasia in five of six patients, yielding a cumulative patency rate of 96% at 18 months (Fig 7).

In 12 patients, the AZY system presented stenoses at several points and even aspects of agenesis of the lumbar plexuses (18%). It is noteworthy that such presentation was significantly associated with the PP course, with MS plaques distributed in the spinal cord.⁴ This malformation, of course, was not treated, probably explaining the worse results obtained in these patients with respect to the RR course.

PTA results for primary patency at the level of the IJVs were much less positive. IJVs were stenosed unilaterally or bilaterally in 59 of 65 patients (91%). The stenoses were most frequently annulus (Fig 3), followed by septum/valve malformations (Fig 5). Restenosis recurred in 47% of patients overall. Cumulative survival curves demonstrate that such negative outcomes occurred more frequently 8 to 9 months after the initial procedure.

The logical alternative would be stent insertion.³⁴ However, we refrained from using this option due to the absence on the market of dedicated devices of the proper size and length. Adapting existing stents at the level of the IJVs could increase the risk of pulmonary migration and displacement, thus affecting venous outflow from the upper extremity.

We are currently evaluating the secondary patency in the same cohort in which we performed a second treatment at the end of the follow-up using a high-pressure (20 atm) balloon. Another possible option could be open surgery, especially in patients who experienced clinical and MRI benefits after PTA, followed by worsening or relapse, or both, with concomitant restenosis.

The third and very intriguing aspect of this study is the favorable neurologic outcome in associated MS. This was particularly evident in the RR group, who had a severely reduced MSFC score before the treatment. The MSFC results in this group improved significantly, which was confirmed by the parallel improvement in QOL. The rate of patients who were relapse-free increased significantly, whereas the annualized relapse rate did not (Table IV). It is

of great interest and should be emphasized that no relapses were detected in patients with satisfactory reversal of the CCSVI condition, in terms of stable patency either of the IJVs or of the AZY (Fig 7).

This favorable neurologic outcome was also confirmed by the significant reduction in Gad+ lesions on the 1-year MRI; however, our open-label design requires caution in evaluating this finding. MRI was not always performed with the same instrument, followed the same protocol, or was at the same intervals. This shortcoming is linked with the open-label design of our study and also that we treated patients at the time of diagnostic venography.

Another influential factor of the favorable outcome of our RR group could be the continuing immunomodulating treatment, which is well known to be capable of significantly reducing relapse rates as well as MRI-detectable Gad+ lesions.^{35,36} It does, however, appear that endovascular treatment of concomitant CCSVI may have an additional benefit on lesions activity.

The neurologic outcomes in the PP and SP groups were certainly less significant and promising. However, because PP currently lacks any effective treatment, the significant improvement in physical QOL warrants further evaluation.

It will be interesting to know, when available, the evaluation of secondary patency in the group of 30 patients who underwent PTA a second time due to restenosis of the IJV.

The major shortcoming of our study is that is not a blinded study. There is a great possibility that bias could be playing an important role in trying to find hope for the treatment of this chronic disease. However, these data will be fundamental in planning a multicenter randomized, controlled trial, with blinded assessors of the neurologic outcome. This trial should compare two groups of RR patients, one arm treated pharmacologically, and the other in which endovascular treatment of the associated CCSVI is added to the pharmacologic treatment.

AUTHOR CONTRIBUTIONS

Conception and design: PZ, FS
Analysis and interpretation: PZ, RG, FS
Data collection: PZ, RG, EM, AM, SG, IB, FS
Writing the article: PZ, RG, AM
Critical revision of the article: PZ, RG, FM, FS
Final approval of the article: PZ, RG, EM, AM, SG, IB, FM, FS
Statistical analysis: PZ, AM
Obtained funding: PZ, FM
Overall responsibility: PZ

REFERENCES

- Schaller B. Physiology of cerebral venous blood flow: from experimental data in animals to normal function in humans. *Brain Res Rev* 2004;46:243-60.
- Menegatti E, Zamboni P. Doppler haemodynamics of cerebral venous return. *Curr Neurovasc Res* 2008;5:260-5.

- Lepori D, Capasso P, Fournier D, Genton CY, Schnyder P. High-resolution ultrasound evaluation of internal jugular venous valves. *Eur Radiol* 1999;9:1222-6.
- Zamboni P, Galeotti R, Menegatti E, Malagoni AM, Tacconi G, Dall'ara S, et al. Chronic cerebrospinal venous insufficiency in patients with multiple sclerosis. *J Neur Neurosurg Psychiatry* 2009;80:392-9.
- Lee BB, Laredo J, Lee TS, Huh S, Neville R. Terminology and classification of congenital vascular malformations. *Phlebology* 2007;22:249-52.
- Zamboni P, Menegatti E, Galeotti R, Malagoni AM, Tacconi G, Dall'ara S, et al. The value of cerebral Doppler venous haemodynamics in the assessment of multiple sclerosis. *J Neurol Sci* 2009 15;28221-7.
- Franceschi C. The unsolved puzzle of multiple sclerosis and venous function. *J Neurol Neurosurg Psychiatry* 2009;80:358.
- Zamboni P, Consorti G, Galeotti R, Ganesini S, Menegatti E, Tacconi G, et al. Venous collateral circulation of the extracranial cerebrospinal outflow routes. *Curr Neurovasc Res* 2009;6:204-12.
- Law M, Saindane AM, Ge Y, James SB, Glyn J, Lois JM, et al. Microvascular abnormality in relapsing-remitting multiple sclerosis: perfusion MR imaging findings in normal-appearing white matter. *Radiology* 2004;231:645-52.
- Ge Y, Zohrabian VM, Grossman RI. Seven-Tesla magnetic resonance imaging. New vision of microvascular abnormalities in multiple sclerosis. *Arch Neurol* 2008;65:812-6.
- Kermode AG, Thompson AJ, Tofts P, MacManus DG, Kendall BE, Kingsley DP, et al. Breakdown of the blood-brain barrier precedes symptoms and other MRI signs of new lesions in multiple sclerosis. Pathogenetic and clinical implications. *Brain* 1990;113:1477-89.
- Kidd D, Barkhof F, McConnell R, Algra PR, Allen IV, Revesz T. Cortical lesions in multiple sclerosis. *Brain* 1999;122:17-26.
- Tan IL, van Schijndel RA, Pouwels PJ. MR venography of multiple sclerosis. *Am J Neuroradiol* 2000;21:1039-42.
- Fog T. The topography of plaques in multiple sclerosis with special reference to cerebral plaques. *Acta Neurol Scand Suppl* 1965;15:1-161.
- Noseworthy JH, Lucchinetti C, Rodriguez M, Weinshenker BG. Multiple sclerosis. *N Engl J Med* 2000;343:938-52.
- Polman CH, Reingold SC, Edan G, Filippi M, Hartung HP. Diagnostic criteria for multiple sclerosis: 2005 revisions to the "McDonald Criteria". *Ann Neurol* 2005;58:840-6.
- Kurtzke JF. Rating neurological impairment in multiple sclerosis: an expanded disability scale (EDSS). *Neurology* 1983;33:1444-52.
- Lee BB, Villavicencio L, Kim YW, Do YS, Koh KC, Lim HK, et al. Primary Budd-Chiari syndrome: outcome of endovascular management for suprahepatic venous obstruction. *J Vasc Surg* 2006;43:101-8.
- Raju S, Hollis K, Neglen P. Obstructive lesions of the inferior vena cava: clinical features and endovenous treatment. *J Vasc Surg* 2006;44:820.
- Viscusi ER, Reynolds L, Chung F, Atkinson LE, Khanna S. Patient-controlled transdermal fentanyl hydrochloride vs intravenous morphine pump for postoperative pain: a randomized controlled trial. *JAMA* 2004;17:1333-41.
- Cutter GR, Baier ML, Rudick RA, Cookfair DL, Fischer JS, Petkau J, et al. Development of a multiple sclerosis functional composite as a clinical trial outcome measure. *Brain* 1999;122:871-82.
- Fisher JS, Rudick R, Cutter G, Reingold SC. The Multiple Sclerosis Functional Composite measure (MSFC): an integrated approach to MS clinical outcome assessment. *Mult Scler* 1999;5:244-50.
- D'Souza M, Kappos L, Czaplinski A. Reconsidering clinical outcomes in multiple sclerosis: relapses, impairment, disability and beyond. *J Neurol Sci* 2008;274:76-9.
- Weinstock-Guttman B, Ramanathan M, Zivadinov R. Interferon-beta treatment for relapsing multiple sclerosis. *Expert Opin Biol Ther* 2008; 8:1435-47.
- Freedman MS, Hughes B, Mikol DD, Bennett R, Cuffel B, Divan V, et al. Efficacy of disease-modifying therapies in relapsing remitting multiple sclerosis: a systematic comparison. *Eur Neurol* 2008;60:1-11.
- Vickrey BG, Hays RD, Harooni R, Myers LW, Ellison GW. A health-related quality of life measure for multiple sclerosis. *Qual Life Res* 1995;4:187-206.
- Geerts WH, Bergqvist D, Pineo GF, Heit JA, Samama CM, Lassen MR, et al; American College of Chest Physicians. Prevention of

- venous thromboembolism: American College of Chest Physicians evidence-based clinical practice guidelines (8th edition). *Chest* 2008;133(6 suppl):381-453S.
28. Zamboni P, Lanzara S, Mascoli F, Caggiati A, Liboni A. Inflammation in venous disease. *Int Angiol* 2008;27:361-9.
 29. Zamboni P. The big idea: iron-dependent inflammation in venous disease and proposed parallels in multiple sclerosis. *J R Soc Med* 2006;99:589-93.
 30. Schelling F. Damaging venous reflux into the skull or spine: relevance to multiple sclerosis. *Med Hypotheses* 1986;21:141-8.
 31. Talbert DG. Raised venous pressure as a factor in multiple sclerosis. *Med Hypotheses* 2008;70:1112-7.
 32. West JB, Tsukimoto K, Matheu-Costello O, Prediletto R. Stress failure in pulmonary capillaries. *J Appl Physiol* 1991;70:1731-42.
 33. Browse NL, Burnand KG. The cause of venous ulceration. *Lancet* 1982;2:243-5.
 34. Xu K, He FX, Zhang HG, Zhang XT, Han MJ, Wang CR, et al. Budd-Chiari syndrome caused by obstruction of the hepatic inferior vena cava: immediate and 2-year treatment results of transluminal angioplasty and metallic stent placement. *Cardiovasc Intervent Radiol* 1996;19:32-6.
 35. Havrdova E, Galetta S, Hutchinson M, Stefoski D, Bates D, Polman CH, et al. Effect of natalizumab on clinical and radiological disease activity in multiple sclerosis: a retrospective analysis of the Natalizumab Safety and Efficacy in Relapsing-Remitting Multiple Sclerosis (AFFIRM) study. *Lancet Neurol* 2009;8:254-60.
 36. CAMMS223 Trial Investigators, Coles AJ, Compston DA, Selmaj KW, Lake SL, Moran S, et al. Alemtuzumab vs. interferon beta-1a in early multiple sclerosis. *N Engl J Med* 2008;359:1786-801.

Submitted Jun 11, 2009; accepted Jul 23, 2009.

Additional material for this article may be found online at www.jvascsurg.org.

CME Credit Now Available to JVS Readers

Readers can now obtain CME credits by reading selected articles and correctly answering multiple choice questions on the Journal website (www.jvascsurg.org). Four articles are identified in the Table of Contents of each issue and 2 questions for each are posted on the website. After correctly answering the 8 questions, readers will be awarded 2 hours of Category I CME credit.

Appendix (online only). Neurologic and Doppler outcome parameters

1. Revised McDonald Criteria In 2001, the International Panel on the Diagnosis of Multiple Sclerosis presented new diagnostic criteria for multiple sclerosis (MS) that have come to be known as the “McDonald Criteria.” The criteria became known internationally, and were rapidly adopted by the MS community.¹ The intent of the McDonald Criteria was to present a diagnostic scheme that practicing neurologists could use to better and more reliably diagnosis MS, balancing early diagnosis with the need to avoid a false-positive diagnosis. The International Panel reconvened in March 2005 in Amsterdam, nearly 5 years after the original panel met in London, to review progress since the original criteria were developed. The new guidelines help to demonstrate dissemination of lesions in time, to clarify the use of spinal cord lesions, and to simplify diagnosis of primary progressive disease.

The revised criteria for diagnosis of MS include the following:

- At least two attacks with objective clinical evidence of at least two lesions;
- At least two attacks with objective clinical evidence of one lesion plus dissemination in space shown on magnetic resonance imaging (MRI), or two or more MRI lesions consistent with MS plus positive cerebrospinal fluid (CSF) finding or second clinical attack;
- One attack with objective clinical evidence of at least two lesions plus dissemination in time on MRI or a second clinical attack;
- One attack with objective clinical evidence of one lesion, plus dissemination in space shown on MRI or two or more MRI lesions consistent with MS plus positive CSF finding and dissemination in time shown on MRI or second clinical attack;
- Insidious neurologic progression suggestive of MS plus 1 year of disease progression determined retrospectively or prospectively and two of the following: positive brain MRI result (nine T2 lesions or at least four T2 lesions with positive visual evoked potential), positive spinal cord MRI result with two focal T2 lesions, and positive CSF findings.

The revised MRI criteria for dissemination in time are detection of gadolinium enhancement at least 3 months after the onset of the first clinical event or detection of a new T2 lesion appearing at any time compared with a reference scan done at least 30 days after the onset of the initial clinical event.

The revised MRI criteria for dissemination in space are three of the following:

1. one or more gadolinium-enhancing lesions or nine T2 hyperintense lesions;
2. one or more infratentorial lesions; one or more juxtacortical lesions;
3. or three or more periventricular lesions.

2. Expanded Disability Status Scale The Kurtzke Expanded Disability Status Scale (EDSS) is a method of quantifying disability in MS. The EDSS categorizes a person’s level of disability. EDSS scores range from 0 to 10, with higher scores indicating more severe disability.² The EDSS is an important tool in clinical practice. It is widely used and it photographs the clinical situation. The EDSS score is based on neurologic testing and examination of functional systems, which are areas of the central nervous system that control bodily functions. The functional systems are:

- Pyramidal (ability to walk);
- Cerebellar (coordination);
- Brain stem (speech and swallowing);
- Sensory (touch and pain);
- Bowel and bladder functions;
- Visual;
- Mental;
- Other (includes any other neurologic findings due to MS).

These rankings are especially important in the “less severe” lower numbers of the scale, when a patient is still ambulatory yet experiencing some abnormal signs or disability in other areas.

A Kurtzke EDDS score of 0.0 indicates a normal neurologic examination, 1.0 to 4.5 documents MS patients who are fully ambulatory, and 5.0 to 9.5 defines impairment to ambulation:

- **EDSS 1.0-3.0:** Able to do regular activities normally.
- **EDSS 3.5-4.5:** Moderate disability that starts to impair daily functioning.
- **EDSS 5.0-5.5:** Unable to do full daily activities, but still able to walk without assistance.
- **EDSS 6.0-6.5:** Needs assistance to walk, such as a cane, crutch, or brace.
- **EDSS 7.0-8.0:** Needs a wheelchair most of the time but may still be able to walk a few steps around the home with assistance.
- **EDSS 8.5-9.5:** Bedridden most of the day; may have lost use of arms and ability to communicate effectively or eat.
- **EDSS 10.0:** Death due to MS.

3. Multiple Sclerosis Functional Composite The Multiple Sclerosis Functional Composite (MSFC) is a multi-dimensional clinical outcome measure consisting of quantitative timed tests of leg function/ambulation (Timed 25-Foot Walk [T25FW]), arm function (Nine-Hole Peg Test [9HPT]), and cognitive function (Paced Auditory Serial Addition Test [PASAT]) expressed as a single score along a continuous scale.³ Test were administrated using a standardized protocol according to MSFC guidelines⁴ and a definite order, as follows:

- T25FW: Patients were instructed to walk 25 feet as quickly as possible, but safely. The average time of two consecutive trials was recorded.

- **9-HPT:** Patients were instructed to pick up nine pegs one at a time as quickly as possible and put them in a block containing nine empty holes, and once they were in the holes, to remove them again as quickly as possible one at a time. The dominant and nondominant hands were both tested twice, and the average time for each hand was recorded.
- **PASAT:** The test was presented using a voice recording. Patients had to add a sequence of numbers presented every 3 seconds, each new one to the one immediately before it. The number of correct sums was recorded.

The MSFC score was derived from three components: (1) the average scores from the four trials on the 9-HPT (the two trials for each hand are averaged, converted to the reciprocals of the mean times for each hand and then the two reciprocals are averaged); (2) the average scores of two 25-F W trials; and (3) the number correct from the PASAT-3. For each component a *z* score was then created using tests results from the baseline visit. A *z* score is a standardized score obtained by subtracting the baseline mean from the test result then dividing by the baseline standard deviation. The composite score was calculated by adding the *z* scores obtained and dividing the sum by 3, as described in the formula: $MSFC\ score = (z_{arm, average} - z_{leg\ average} + z_{cognitive})/3.0$. The negative value of the 25-FW *z* score was used to make the direction of change the same as the other components.

A decrease or an increase in the MSFC score represents, respectively, deterioration or improvement in neurologic functions.

4. Echo color Doppler for investigation of cerebral venous return

- **Patient position:** The posture of the individual being examined by echo color Doppler (ECD) is crucial in determining the main route of cerebral outflow. For this reason, the person should be investigated at least in both supine and sitting positions (0° and 90°). This objective can be realized with the individuals being positioned on a tilt bed or chair.⁵⁻⁷
- **Equipment and transducers:** The investigation of the cerebral venous hemodynamics can envisage the contemporaneous analysis of both the intracranial and extracranial pathways by combining with the same ultrasound machine, respectively, the examination of the deep cerebral veins (DCVs) with that of the internal jugular veins-vertebral veins (IJVs-VVs) by means of the proper ultrasound probe. The transducer at the intracranial level is at low frequency, usually ≤ 2.5 Mhz, whereas a high frequency, 6- to 13-Mhz, linear or microconvex probe is used at the cervical level, according to the different depth of the veins respective to the body surface where the transducer is placed.⁵⁻⁷
- **DCVs flow direction assessment:** The transducer is placed at the level of the transtemporal bone window, and the depth of the insonation is adjusted to 10 cm. At an insonation depth of about 6 to 7 cm, it is possible to consistently identify the echolucent third ventricle, limited by two echogenic bright margins, as well as the two comma-shaped frontal horns of the lateral ventricles. Individuals can be examined both in sitting and supine positions, and the venous flow is enhanced by inviting the person to breathe, and setting the pulse repetition frequency of the instrument to lower values, ranging between 0.3 and 1.4. By using the transtemporal acoustic bone window, it is possible to insonate around the third ventricle at least one of the DCVs, or all three branches, including basal veins of Rosenthal (flow expected upward and toward the Galen vein), great vein of Galen (flow expected toward the occipital side into the straight sinus), and internal cerebral veins (flow expected downward and toward the Galen vein). Reflux is a reverse flow for a duration >0.5 seconds.⁵⁻⁷
- **IJVs-VVs flow direction assessment:** Examination is performed with high-frequency transducers as above reported. Individuals should be examined at least in sitting and supine positions. Flow recording begins 2 minutes after the change in posture and after several deep breaths to permit blood redistribution in the venous system. For each assessment, the direction of flow is analyzed either with the pulsed-wave mode and the sample placed in the vessel at a 60° angle, or with the color-coded mode by comparing the color of the flow in the IJV-VV with that of the satellite carotid or vertebral artery, or both, respectively. Either the IJVs or the VVs can be examined by using the transversal or the longitudinal cervical access, or both. The operator uses minimal pressure over the skin to prevent compressing the vein and thereby affecting the measurement. Flow direction is normally directed toward the heart. Reflux is a reverse flow assessed in the respiratory pause for a duration >0.88 seconds.⁵⁻⁷
- **Assessment of cross-sectional area:** The level of IJV insonation corresponds to the thyroid gland, and the point of measurement is outlined over the skin with a waterproof pen. The individual is examined in sitting and supine positions using the transversal access (by the longitudinal scan, the operator is unaware if the cross-sectional area [CSA] is elliptical or circular, thus affecting the measurement). The operator uses minimal pressure over the skin to prevent compressing the vein and thereby affecting the measurement. CSA is measured in the supine and sitting positions by means of the software for elliptical or circular shapes included in the ECD instrumentation, separately in the right and left IJV. Alternatively, it is possible to measure the diameter by means of the software and to calculate the CSA according to geometric formulas, respectively, for circle and ellipse. In case of spontaneous fluctuations in CSA caused by activation of the thoracic pump, the CSA can be measured during a short period of apnea after a normal exhalation. The CSA is calculated by subtracting the CSA measured in the supine position from that in the erect position, separately in the right and left IJV.⁵⁻⁷

- **B-mode anomalies.** Malformations in the IJVs often correspond to the presence of septum/valve malformation at the level of the proximal segment of these veins.⁵⁻⁷ They hamper the venous flow, causing turbulences, or determine blocked flow or reflux, especially during inspiration, with a paradoxical functional obstruction in the more favorable condition for venous emptying (activation of the thoracic aspiration). Videos 1 and 2 provide exemplification of the more frequent B-mode anomalies.

REFERENCES

1. Polman CH, Reingold SC, Edan G, Filippi M, Hartung HP, Kappos L, et al. Diagnostic criteria for multiple sclerosis: 2005 revisions to the "McDonald Criteria." *Ann Neurol* 2005;8: 840-6.
2. Kurtzke JF. Historical and clinical perspectives of the expanded disability status scale. *Neuroepidemiology* 2008;31: 1-9.
3. Cutter GR, Baier ML, Rudick RA, Cookfair DL, Fischer JS, Petkau J, et al. Development of a multiple sclerosis functional composite as a clinical trial outcome measure. *Brain* 1999;122: 871-82.
4. Fischer JS, Jak AJ, Kniker JE, Cutter G, Rudick R. "Administration and scoring manual for the Multiple Sclerosis Functional Composite." New York: National Multiple Sclerosis Society, 2001.
5. Menegatti E, Zamboni P. Doppler haemodynamics of cerebral venous return. *Curr Neurovasc Res* 2008;5: 260-5.
6. Zamboni P, Galeotti R, Menegatti E, Malagoni AM, Tacconi G, Dall'ara S, et al. Chronic cerebrospinal venous insufficiency in patients with multiple sclerosis. *J Neur Neurosurg Psychiatry* 2009;80: 392-9.
7. Zamboni P, Menegatti E, Galeotti R, Malagoni AM, Tacconi G, Dall'ara S, Bartolomei I, Salvi F. The value of cerebral Doppler venous haemodynamics in the assessment of multiple sclerosis. *J Neurol Sci* 2009;282: 21-7.