

# The severity of chronic cerebrospinal venous insufficiency in patients with multiple sclerosis is related to altered cerebrospinal fluid dynamics

Paolo Zamboni, MD<sup>a</sup>  
Erica Menegatti, RVT<sup>a</sup>  
Bianca Weinstock-Guttman, MD<sup>b</sup>  
Claudiu Schirda, PhD<sup>c</sup>  
Jennifer L. Cox, PhD<sup>c</sup>  
Anna M. Malagoni, MD<sup>a</sup>  
David Hojnacki, MD<sup>b</sup>  
Cheryl Kennedy, LMSW, MPH<sup>c</sup>  
Ellen Carl, BA<sup>c</sup>  
Michael G. Dwyer, BS<sup>c</sup>  
Niels Bergsland, BA<sup>c</sup>  
Roberto Galeotti, MD<sup>a</sup>  
Sara Hussein, BS<sup>c</sup>  
Ilaria Bartolomei, MD<sup>a</sup>  
Fabrizio Salvi, MD<sup>a</sup>  
Robert Zivadinov, MD, PhD<sup>b,c</sup>

<sup>a</sup> Vascular Diseases Center, University of Ferrara, and Bellaria Neurosciences, Ferrara and Bologna, Italy

<sup>b</sup> The Jacobs Neurological Institute, University at Buffalo, Buffalo, NY, USA

<sup>c</sup> Buffalo Neuroimaging Analysis Center, University at Buffalo, Buffalo, NY, USA

Corresponding author: Paolo Zamboni,  
Vascular Diseases Center,  
University of Ferrara,  
44100 Ferrara, Italy  
e-mail: zmp@unife.it

## Summary

**Chronic cerebrospinal venous insufficiency (CCSVI) is a vascular picture that shows a strong association with multiple sclerosis (MS). The aim of this study was to investigate the relationship between a Doppler cerebral venous hemodynamic insufficiency severity score (VHISS) and cerebrospinal fluid (CSF) flow dynamics in 16 patients presenting with CCSVI and relapsing-remitting MS (CCSVI-MS) and in eight healthy controls (HCs). The two groups (patients and controls) were evaluated using validated echo-Doppler and advanced 3T-MRI CSF flow measures. Compared with the HCs, the CCSVI-MS patients showed a significantly lower net CSF flow ( $p=0.027$ ) which was highly associated with the VHISS ( $r=0.8280$ ,  $r^2=0.6855$ ;  $p=0.0001$ ).**

**This study demonstrates that venous outflow disturbances in the form of CCSVI significantly impact on CSF pathophysiology in patients with MS.**

*KEY WORDS: chronic cerebrospinal venous insufficiency, CCSVI, CSF, echo-Doppler, MRI, multiple sclerosis.*

## Introduction

As selective venography studies have clearly shown (1-5), chronic cerebrospinal venous insufficiency (CCSVI) is characterized by multiple extracranial stenoses affecting the internal jugular veins (IJVs) and the azygous vein (AZ), leading to the opening of collaterals. A significant association between CCSVI and multiple sclerosis (MS) has recently been demonstrated (1).

Combined transcranial and extracranial echo-color Doppler (ECD) sonography can be used to detect venous hemodynamic (VH) parameters indicative of CCSVI, a condition in which the physiological postural and respiratory mechanisms of cerebral venous return are completely upset. We previously reported that at least two out of five VH criteria need to be fulfilled for a diagnosis of CCSVI. The fulfilment of  $\geq 2$  criteria in the same subject was never observed in controls, but overlapped perfectly with the diagnosis of clinically definite MS in cross-sectional studies (1,4). Furthermore, the application of advanced MRI techniques and assessment of non-conventional MRI measures may offer new pathophysiological and pathogenetic information (6-8).

Hypothesizing that altered extracranial venous hemodynamics may be associated with altered intracranial cerebrospinal fluid (CSF) flow dynamics, we applied an advanced cine CSF imaging acquisition and analysis protocol to our study population.

## Materials and methods

Sixteen consecutive relapsing-remitting (R-R) MS patients, diagnosed in accordance with the McDonald criteria (9), eight from the Bellaria Hospital (Bologna, Italy) and eight from the Jacobs Neurological Institute, University at Buffalo (NY, USA), as well as eight age- and sex-matched healthy controls (HCs), four from Italy and four from NY, were enrolled in this study. The inclusion criteria were: R-R disease course (10); Expanded Disability Status Scale (EDSS) (11) score of between 0-5.5; age of between 18 and 65 years; disease duration of between 5 and 10 years; being on a currently FDA-approved disease-modifying treatment; normal renal function (creatinine clearance level of  $>58$ ); for the Italian patients and controls, a willingness to travel to the USA.

The exclusion criteria were: an acute relapse and/or steroid treatment within the 30 days preceding study entry, pre-existing medical conditions associated with brain pathologies (e.g., neurodegenerative disorder, positive history of alcohol abuse, trauma and other condition identified through an MRI health questionnaire), abnormal renal function.

The study was conducted at the Jacobs Neurological Institute and the Buffalo Neuroimaging Analysis Center at Buffalo, NY, over a period of four days. All the investigators – the Italian team performed VH/Doppler assessments and the Buffalo team clinical and MRI examinations – were fully blinded to the subjects' clinical and demographic characteristics and group (MS or HCs). Clinical, VH, and MRI parameters were assessed within the same day for each subject, in a cross-sectional design.

All the patients underwent complete physical and neurological examinations, EDSS scoring, and Multiple Sclerosis Functional Composite (MSFC) (12,13) evaluations followed by ECD and advanced MRI assessment.

#### Protocol approval and patient consent

The study data were obtained under a protocol approved by the Human Subjects Institutional Review Board of the University at Buffalo. Written informed consent was obtained from all the subjects.

#### ECD study of cerebral venous return

Cerebral venous return was examined using the My Lab 30 Vinco ECD system (Esaote-Biosound, Genoa, Italy), equipped with 2.5 and 7.5-10 MHz transducers, with the subject positioned on a tilt bed as previously described (1,4,14,15). We looked, in particular, for the following five VH criteria (VH 1-5) indicative of the presence of CCSVI (1,4):

VH1. Reflux in the IJVs and/or in the vertebral veins (VVs), with the subject assessed in both the sitting and the supine position. In accordance with a study that proposed cut-off values to allow differentiation between physiological flow and reflux, reflux was defined as a reversal of the physiological direction of the flow lasting  $>0.88$  seconds (18), although in our study flow was assessed during a short period of apnea following a normal exhalation, and never in a forced condition like the Valsalva maneuver. Positive findings suggest the presence of stenoses in the IJVs and/or in the AZ, respectively.

VH2. Reflux in the deep cerebral veins (DCVs), which include the Galen vein, the internal cerebral vein, the Rosenthal vein, and the veins draining the subcortical gray matter (GM) into the DCVs. Positive findings indicate propagation of extracranial reflux into parenchymal veins.

VH3. B-mode imaging evidence of stenoses in the IJVs, due to the presence of annuli, webs, septa, or malformed valves (Fig.1).

VH4. Absence of Doppler signal in the IJVs and/or in the VVs, even after forced inspiration (Fig.1), in both sitting and supine positions, or in only one of the two positions but with detection of reflux in the other position. Blocked outflow is related to stenosis located distally to the point of assessment.

VH5. Negative difference in the cross-sectional area (CSA) of the IJVs ( $-\Delta\text{CSA}$ ), obtained by subtracting the CSA measured in the supine from that obtained in the sitting position. In human physiology, the IJVs are the predominant outflow pathway in the supine position leading to a positive value of  $\Delta\text{CSA}$  (14,17).

#### Venous hemodynamic insufficiency severity score (VHISS)

For each of the five VH criteria a "VHISS contribution score" was assigned using the scheme described below. These scores, combined, gave an overall severity measure, the VHISS.

As regards criterion VH1, there are eight venous segments that can potentially exhibit reflux in the two postures and one point was assigned for each one at which reflux was found to be present. Consequently, VH1 had a VHISS contribution score that could range from a minimum of 0 to a maximum of eight.

Criterion VH2 was assigned a VHISS contribution score of 1 if reflux was present in the DCVs in only one posture, and of 2 if it was present in both postures. The VHISS contribution score for this criterion was additionally weighted with a factor of 2 if reflux toward the subcortical GM could be detected. This was based on a previous report in which we found the latter to be significantly associated with greater disability (19). Consequently, the VHISS contribution score for VH2 could range from a minimum of 0 to a maximum of four.

The VHISS contribution score for VH3 ranged from 0 to 2, depending on whether B-mode anomalies disturbing outflow were present in none, one or both of the IJVs, respectively. VH3 was assigned a contribution score of 0 if either VH1 or VH4 were positive for the presence, in either posture, of reflux or obstruction in the IJV of interest (Fig.1).

The scoring scheme for the contribution of VH4 to the VHISS was the same as that for VH1, the difference being that only blocks were considered (Fig.1). No points were assigned for segments and postures in which reflux had previously been detected under VH1.

The VH5 criterion had an overall VHISS contribution score of between 0 and 4, calculated by assigning 0 to 2 points for each IJV. A  $-\Delta\text{CSA}$  value was assigned a score

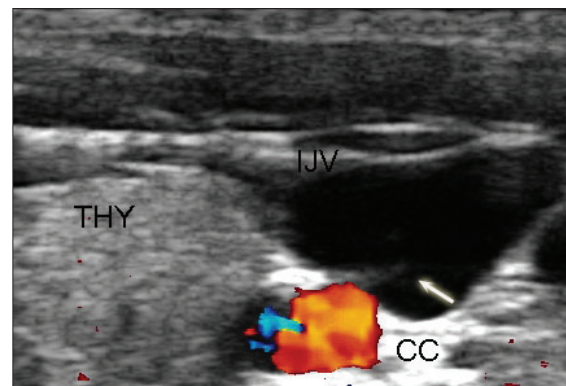


Figure 1 - Septum and flow block in an internal jugular vein on echo-color Doppler

Cervical ECD, left side transverse access, supine posture. CC=common carotid artery; THY=thyroid gland; IJV=internal jugular vein. The arrow in the IJV indicates a septum (criterion VH3) that cannot be crossed by the flow, despite maximum inspiration (no color in the lumen).

This example of blocked flow corresponds to VH4. Thus we assigned, for both findings, a single VHISS contribution score of 1 due to the mutually exclusive nature of VH3 and VH4.

of 2, whereas a  $\Delta$ CSA value  $<7 \text{ mm}^2$ , corresponding to the 25<sup>th</sup> percentile of  $\Delta$ CSA distribution in healthy controls (5), was assigned a score of one.  $\Delta$ CSA  $>7 \text{ mm}^2$  was assigned a score of 0.

The overall VHISS score was defined as a weighted sum of the scores contributed by each individual VH criterion. The formula for VHISS calculations was:  $VHISS = VHISS_1 + VHISS_2 + VHISS_3 + VHISS_4 + VHISS_5$ . The subscripts in this formula indicate the subscores for the five VH criteria. The VHISS score is an ordinal measure of the overall extent and number of VH flow pattern anomalies, with a higher value of VHISS indicating a greater severity of these anomalies. The minimum possible VHISS value was 0 and the maximum 16. The maximum is limited by the mutually exclusive nature of VH1, VH3 and VH4 (Fig.1).

**MRI assessment**

Image acquisition. All the subjects were examined on a 3T GE Signa Excite HD 12.0 Twin Speed 8-channel scanner (General Electric, GE, Milwaukee, WI), with a maximum slew rate of 150T/m/s and a maximum gradient amplitude in each orthogonal plane of 50mT/m (zoom mode). Table I details the MRI acquisition parameters. A cine, phase-contrast velocity-encoded ( $V_{enc} = 20\text{cm/s}$ ) gradient echo scan with peripheral cardiac gating was collected to measure the CSF flow in the Sylvius aqueduct; 32 phases, corresponding approximately to a full cardiac cycle (systole and diastole), were collected on one 4 mm-thick slice positioned perpendicular to the Sylvius aqueduct, with in-plane resolution  $0.39 \times 0.039 \text{ mm}^2$ . A sagittal T2 scan was taken prior to the axial cine sequence, to facilitate visualization of the aqueduct and positioning (Fig. 2). Although aliasing

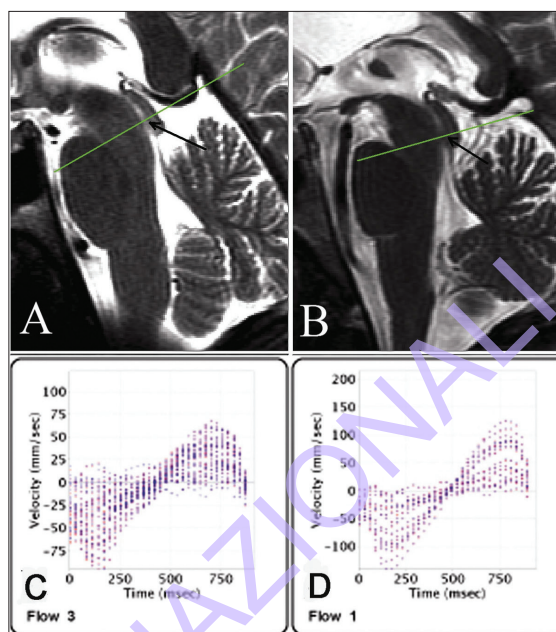


Figure 2 - Cerebrospinal fluid flow measurement in the Sylvius aqueduct. Assessment in a HC (left) and MS patient (right), A-B. Sagittal T2 scans showing positioning for the MRI cine acquisition. Slices were perpendicular to the aqueduct (arrows), C-D. CSF velocity distribution within the aqueduct region of interest, for the 32 phases, calculated using the GE ReportCard software. Positive (or retrograde) flow is toward the 3<sup>rd</sup> ventricle and negative (or anterograde) flow toward the 4<sup>th</sup> ventricle. Normal CSF flow in the aqueduct is negative during systole and positive during diastole.

Table I - MRI acquisition parameters on a GE 3T scanner.

Series description	PD/T2	SE T1	3D HIRIS	FLAIR T1W1	Sag T2WI	Ax CinePC $V_E=20\text{cm/s}$
AT (min:s)	5:08	6:11	9:18	6:49	1:10	4:22
Matrix	256x256	256x256	256x256	256x256	512x256	256x256
FOV (cm)	25.6	25.6	25.6	25.6	24	10
Phase FOV	0.75	0.75	0.75	1	1	1
TE (ms)	9/98	16	2.8	120	105	8
TR (ms)	5300	600	5.9	8500	5000	40
Ti (ms)	-	-	900	2100	-	-
ETL	14	1	1	24	24	1
Slices/Locations	64	64	184	64	14	1
Thickness (mm)	2	2	1	2	3	4
Gap	0	0	0	0	1	0
Averages	1	1	1	1	1	1
Flip Angle (degrees)	90	90	10	90	90	20
Bandwidth (Hz/px)	195	163	244	163	122	122

Abbreviations: AT=acquisition time;FOV=field of view; TE=echo time; TR=repetition time; TI=inversion time; ETL=echo train length; PD=proton density; T2WI=T2-weighted image; SE= spin echo; FLAIR=fluid-attenuated inversion recovery; HIRIS T1WI= high-resolution T1-weighted image; Sag T2WI=Sagittal T2-weighted image; Ax CinePC=axial cine phase-contrast acquisition.



was present in the cine images (because a 10 cm field of view was used), this did not affect the analysis which was confined to the aqueduct region. Given that circadian rhythm can influence CSF flow (20), HCs and MS patients were matched for the time of the day when the scan was obtained. A spin echo T1-weighted image was acquired 5 min following an injection with a single dose intravenous bolus of 0.1 mM/kg gadolinium (Gd)-DTPA.

#### MRI analysis

The MRI analysts were blinded to the patients' clinical, ECD, and MRI characteristics. Cerebrospinal fluid flow data were processed using the GE ReportCard (version 3.6) software (General Electric, GE, Milwaukee, WI, USA. Measurements for maximum anterograde (toward 4<sup>th</sup> ventricle) and retrograde (toward 3<sup>rd</sup> ventricle) CSF flow velocity were highly reproducible (intra- and inter-rater variations of less than 1%). However, to ensure consistency and higher accuracy in quantifying the anterograde, retrograde and net CSF flow rates, a semi-automated minimum area contour change (MACC) program was used to delineate the aqueduct in each of the 32 phases (21) (Fig. 2). The calculated outline was fitted to an ellipse and the minor radius was considered to be the radius of the aqueduct. Using the peak velocities calculated with the ReportCard software and considering that CSF flow through the aqueduct is laminar (22), the flow rate for each phase was determined. The positive and negative flow rates (mm<sup>3</sup> per heart beat) were determined by integrating the phases with positive and negative velocities, respectively. The net flow rate was calculated as the integral of the flow over the 32 phases.

#### Statistical analysis

Parameters are expressed as median values (with interquartile range). Differences between MS patients and HCs were assessed using Student's t test, or the Mann-Whitney test, as appropriate. The relationship between VHISS and CSF flow was assessed using Spearman rank correlation and linear multiple regression analyses. A p value <0.05 was considered significant with two-tailed tests used for all analyses.

### Results

The differences in demographic, clinical, ECD and MRI characteristics between the study groups, with the relative levels of significance, are shown in Table II. All MS patients were on disease-modifying therapy (seven were on subcutaneous interferon-beta 1a, two on intramuscular interferon-beta 1a, four on natalizumab and three on glatiramer acetate).

#### VH and VHISS parameters in MS patients versus controls

The number of VH criteria fulfilled (median; interquartile range) was significantly greater in the MS group than the control group (4.0; 1.8 vs 0; p<0.001, Mann-Whitney test). All 16 MS patients had CCSVI as defined by the fulfilment of two or more VH criteria; none of the controls had CCSVI. These differences were significant

(p<0.001, Fisher's exact test). These results showed that this study sample, like the MS patients that we previously reported, had increased CCSVI frequency (1,5). Accordingly, VHISS was significantly higher in the CCSVI-MS patients than in the controls (Table II).

#### VHISS is associated with reduced net CSF flow in the aqueduct of Sylvius

Normal CSF flow in the aqueduct is negative during systole and positive during diastole. Positive (or retrograde) flow is directed toward the 3<sup>rd</sup> ventricle and negative (or anterograde) flow toward the 4<sup>th</sup> ventricle; the difference between the anterograde and retrograde flow makes it possible to determine the net CSF flow. As shown in Table II, the MS patients, compared with the controls, showed a lower net CSF flow (p=0.027) and a reduced 3<sup>rd</sup> ventricle volume (p=0.02). The reduction of net CSF flow in MS patients was in turn strongly associated with VHISS: Spearman rank correlation coefficient (corrected for ties) was 0.8229, 95% confidence interval (CI): 0.5248-0.9412, p=0.0002. Figure 3 shows the corresponding linear regression analysis with 95% CI between the VHISS value and lower net CSF flow in CCSVI-MS patients (r=0.8280, r<sup>2</sup>=0.6855; p=0.0001). No correlation between clinical or other MRI parameters and VHISS was demonstrated.

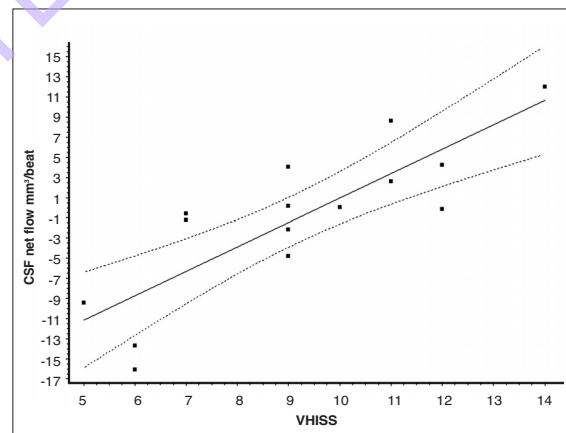


Figure 3 - Association between venous hemodynamic insufficiency severity score (VHISS) and net cerebrospinal fluid flow. Linear regression analysis (straight line) with 95% CI (dotted lines) between VHISS and net CSF flow in CCSVI-MS patients (r=0.83, r<sup>2</sup>=0.69 p<0.0001).

### Discussion

The hemodynamic alterations in CCSVI observed in this study consisted of a higher frequency of venous segments exhibiting reflux, flow block, B-mode imaging evidence of extracranial venous stenoses, and reduced compliance in the IJVs, leading to increased VHISS. Our study showed a strong correlation between VHISS and lower net CSF flow (Fig. 3). Cerebrospinal fluid is formed primarily in the lateral ventricles and mainly flows through the ventricular system,

Table II - Demographic, clinical, echo-color Doppler and MR characteristics of patients with chronic cerebrospinal venous insufficiency and multiple sclerosis (CCSVI-MS) and of healthy controls.

	CCSVI-MS n = 16 Median (interquartile range)	Healthy controls n = 8 Median (interquartile range)	p value
Age, years	35 (6)	32 (6.5)	n.s.
Sex, M/F	6/10	2/6	n.s.
Disease duration, years	8 (3.5)	-	-
EDSS	2.5 (1.25)	-	-
MSFC	2.25 (1.07)	2.95 (0.61)	0.01
Number of fulfilled VH criteria	4 (1.5)	0 (0)	0.0001
VHISS	9 (4)	0 (1)	0.0001
CSF positive flow (mm <sup>3</sup> /beat)	37.13 (32.22)	19.30 (17.79)	n.s.
CSF negative flow (mm <sup>3</sup> /beat)	-31.90 (37.37)	-32.82 (18.88)	n.s.
CSF net average flow (mm <sup>3</sup> /beat)	-0.35 (10.45)	-12.21 (7.59)	0.027
T1-LV (mm <sup>3</sup> )	1123.98 (2283.94)	-	-
T2-LV (mm <sup>3</sup> )	4852.85 (4425.19)	426.01 (803.97)	0.0001
NBV (mm <sup>3</sup> )	1615921.00 (127308.85)	1719794.00 (71247.05)	0.009
NGMV (mm <sup>3</sup> )	936122.79 (114747.53)	1011902.05 (101110.52)	0.03
NWMV (mm <sup>3</sup> )	678115.12 (75733.10)	692765.98 (32065.21)	n.s.
Third ventricle volume (mm <sup>3</sup> )	1348 (680)	861 (330)	0.02

Abbreviations: EDSS=Expanded Disability Status Scale; MSFC=Multiple Sclerosis Functional Composite score; VH=venous hemodynamics; VHISS=venous hemodynamic insufficiency severity score; CSF=cerebrospinal fluid; T1-LV=volume of lesions in T1; T2-LV= volume of lesions in T2, NBV=whole brain volume; NGMV=gray matter volume; NWMV=white matter volume

over the cerebral hemispheres, and through the arachnoid villi into the superior sagittal sinus. Normal CSF circulation, in which there is a correct balance between ultrafiltration of CSF (from the veins of the lateral ventricles) and its clearance from the CSF space into the venous system at the level of the dural sinuses, depends on efficient venous drainage (16,24-26). Impaired CSF dynamics may be a factor contributing to the increases in 3<sup>rd</sup> ventricle and lateral ventricle volumes that we measured (Table II), and that are observed very frequently in MS patients.

Our findings, demonstrating that CCSVI has a significant impact on brain pathophysiology, and particularly on the balance of intracranial fluids, could provide stimulation for the development, in the future, of mathematical models currently lacking (probably because the description of CCSVI is so recent). A model is needed in which increased resistance of venous outflow is partially corrected by the development of collateral circulations (2,19). Speculatively, the imbalance in CSF filtration-reabsorption processes might be related to increased transmural pressure in the condition of CCSVI (1,5,23, 24). CSF flow assessment is a novel MRI tool, and it

would probably be a useful parameter to measure during the follow up of patients submitted to endovascular procedures to correct extracranial venous stenoses in CCSVI (5). It can be hypothesized that improved VHISS would correspond to coherent changes in CSF flow dynamics.

Our pilot study has several limitations. Its main shortcoming is the small sample size. Another limitation is the lack of MRI data on cerebral veins. In advanced MR assessments, susceptibility-weighted imaging may be an ideal approach for "extracting" the venous tree of the brain and calculating the cerebral venous volume (6,7). However, the results obtained in this exploratory study are certainly encouraging and provide a basis for further investigations, both cross-sectional and longitudinal.

#### Acknowledgements

We would like to thank everyone involved in this project. Our thanks go to the subjects who took part in the study, and in particular to the Italian participants who travelled to Buffalo, NY, to undergo four days of examinations.

The authors thank Stenberg Zohara, basic researcher at the Jacobs Institute of Neurology in Buffalo, who facilitated the meeting between the researchers involved in this cooperative study. This study was in part supported by the Hilarescere Foundation and the Buffalo Neuroimaging Analysis Center.

## References

1. Zamboni P, Galeotti R, Menegatti E et al. Chronic cerebrospinal venous insufficiency in patients with multiple sclerosis. *J Neurol Neurosurg Psychiatry* 2009;80:392-399
2. Zamboni P, Consorti G, Galeotti R et al. Venous collateral circulation of the extracranial cerebrospinal outflow routes. *Curr Neurovasc Res* 2009;6:204-212
3. Singh AV, Zamboni P. Anomalous venous blood flow and iron deposition in multiple sclerosis. *J Cereb Blood Flow Metab* 2009 Sep 2 [Epub ahead of print]
4. Zamboni P, Menegatti E, Galeotti R et al. The value of cerebral Doppler venous haemodynamics in the assessment of multiple sclerosis. *J Neurol Sci* 2009;282:21-27
5. Zamboni P, Galeotti R, Menegatti E et al. Endovascular treatment of chronic cerebrospinal venous insufficiency. A prospective open-label study. *J Vasc Surg* 2009 (in press)
6. Haacke E, Makki M, Ge Y et al. Characterizing iron deposition in multiple sclerosis lesions using susceptibility weighted imaging. *J Magn Reson Imaging* 2009;29:537-544
7. Mittal S, Wu Z, Neelavalli J, Haacke EM. Susceptibility-weighted imaging: technical aspects and clinical applications, part 2. *AJNR Am J Neuroradiol* 2009;30:232-252
8. Poloni G, Bastianello S, Vultaggio A et al. Spectroscopic magnetic resonance imaging of the brain: voxel localisation and tissue segmentation in the follow up of brain tumour. *Funct Neurol* 2008;23:207-213
9. Polman CH, Reingold SC, Edan G et al. Diagnostic criteria for multiple sclerosis: 2005 revisions to the "McDonald Criteria". *Ann Neurol* 2005;58:840-846
10. Lublin FD, Reingold SC. Defining the clinical course of multiple sclerosis: results of an international survey. National Multiple Sclerosis Society (USA) Advisory Committee on Clinical Trials of New Agents in Multiple Sclerosis. *Neurology* 1996;46:907-911.
11. Kurtzke JF. Rating neurologic impairment in multiple sclerosis: an expanded disability status scale (EDSS). *Neurology* 1983;33:1444-1452
12. Cutter GR, Baier ML, Rudick RA et al. Development of a multiple sclerosis functional composite as a clinical trial outcome measure. *Brain* 1999;122:871-882
13. Fischer JS, Rudick R, Cutter G, Reingold SC. The Multiple Sclerosis Functional Composite measure (MSFC): an integrated approach to MS clinical outcome assessment. *Mult Scler* 1999;5:244-250
14. Schreiber SJ, Lurtzing F, Gotze R, Doepp F, Klingebiel R, Valdueza JM. Extrajugular pathways of human cerebral venous blood drainage assessed by duplex ultrasound. *J Appl Physiol* 2003;94:1802-1805
15. Doepp F, Schreiber SJ, von Münster T, Rademacher J, Klingebiel R, Valdueza JM. How does the blood leave the brain? A systematic ultrasound analysis of cerebral venous drainage patterns. *Neuroradiology* 2004;46:565-570
16. Schaller B. Physiology of cerebral venous blood flow: from experimental data in animals to normal function in humans. *Brain Res Brain Res Rev* 2004;46:243-260
17. Menegatti E, Zamboni P. Doppler haemodynamics of cerebral venous return. *Curr Neurovasc Res* 2008; 5:260-265
18. Nedelmann M, Eicke BM, Dieterich M. Functional and morphological criteria of internal jugular valve insufficiency as assessed by ultrasound. *J Neuroimaging* 2005;15:70-75
19. Zamboni P, Menegatti E, Bartolomei I et al. Intracranial venous haemodynamics in multiple sclerosis. *Curr Neurovasc Res* 2007;4:252-258
20. Nilsson C, Ståhlberg F, Thomsen C, Henriksen O, Herning M, Owman C. Circadian variation in human cerebrospinal fluid production measured by magnetic resonance imaging. *Am J Physiol* 1992;262:R20-24
21. Wack D, Dwyer M, Hussein S, Durfee J, Zivadinov R. Lesion outlining using minimum area contour change. *Mult Scler* 2008;14 (Suppl 1):P671:S226-227 (abstract)
22. Huang TY, Chung HW, Chen MY et al. Supratentorial cerebrospinal fluid production rate in healthy adults: quantification with two-dimensional cine phase-contrast MR imaging with high temporal and spatial resolution. *Radiology* 2004; 233:603-608
23. Franceschi C. The unsolved puzzle of multiple sclerosis and venous function. *J Neurol Neurosurg Psychiatry* 2009; 80:358
24. Ursino M, Lodi CA. A simple mathematical model of the interaction between intracranial pressure and cerebral hemodynamics. *J Appl Physiol* 1997;82:1256-1269
25. Kim J, Thacker NA, Bromiley PA, Jackson A. Prediction of the jugular venous waveform using a model of CSF dynamics. *AJNR Am J Neuroradiol* 2007;28:983-989
26. Hansen J, Koeppe B. *Netter's Atlas of Human Physiology*. Amsterdam; Elsevier 2008.