

**Multiple Sclerosis:
The Image and its Message**
The Meaning of the Classic Lesion Forms

Dr. F. Alfons Schelling, M.D.

Table of Contents

Challenges.....	4
(I) Genuine Naked Eye Identification	5
(I-1) Pioneering Spinal Cord Findings	5
(I-1-a) Bilateral Spinal Cord Flank Lesions.....	5
(I-1-b) Primary Multiple Sclerosis Specification.....	7
(I-2) Detection of Distinctive Brain Lesions	7
(I-2-a) Ventricle-Based Knuckles, Fingers, and Fists	8
(I-2-b) Cerebral Multiple Sclerosis: A Pathological Entity in Its Own Right?	11
(I-2-c) The Specific Vein-Relationship of Cerebral Multiple Sclerosis.....	11
(I-3) Macropathology: Unexploited Key Evidence.....	13
(II) Histological Perspectives.....	15
(II-1) Tissue Changes in Specific Lesions	15
(II-1-a) Histology of Flank-Lesions of the Spinal Cord	15
(II-1-b) Histopathology of Cerebral Plaques	21
(II-1-c) Spinal and Cerebral Multiple Sclerosis: The Same, and Yet Not the Same	22
(II-2) Histological Lesion Categorizations.....	23
(II-2-a) From "Atrophy" and "Grey Degeneration" to "Multiple Sclerosis".....	23
(II-2-b) Multiple Sclerosis: Primarily a Fibrous Overgrowth?.....	24
(II-2-c) Multiple Sclerosis – The Prototypal Demyelination?	25
(II-3) "Selective Demyelination": The Facts	28
(II-3-a) Primary Demyelinations: A Commonplace Phenomenon	28
(II-3-b) Reverberations of a Histological Misspecification:.....	31
(II-3-c) The Root of All Evil: Demyelination.....	33
(II-3-d) Lymphocytic Infiltrations: Active, Or Re-active?	34
(II-3-e) Primary Inflammation: Adding to the Confusion	36
(II-3-f) Histology: Not the Key to Understanding Multiple Sclerosis.....	36
(III) The Neurologist's Standpoint	38
(III-1) Classical Clinical Observations.....	38
(III-2) CDMS: Chronically Delusive Misidentification Syndrome	44
(III-2-a) The First Clinical Cases.....	45
(III-2-b) Mutations of the Multiple Sclerosis Syndrome	50
(III-2-c) Framing of New Clinical Criteria	51
(IV) The Specter of the Multiple Sclerosis Agent.....	56
(IV-1) Lawless or Specific Pattern(s) of Spread?.....	56
(IV-1-a) Multiple Sclerosis by Blood-Borne Dissemination?	57
(IV-1-b) Inflammatory Versus Specific Plaques.....	61
(IV-1-c) Injurious Inflammation: The Cart Before The Horse.....	64
(IV-2) From Randomly Spread Foci to MS-Agent.....	67

(IV-3) Looking Back in Frustration.....	72
(V) Lesion Explanation in Physical Terms	74
(V-1) The Dynamics of Lesion Formation.....	74
(V-1-a) The Spinal Patches' Peculiar Mode of Extension	75
(V-1-b) Dynamics of Brain Plaque Expansion.....	78
(V-2) Cause of the Injurious Impulses	84
(V-2-a) Recurrence of Injurious Venous Back-Jets into the Brain.....	85
(V-2-b) Specific Spinal Scars: Also Venous in Origin?.....	88
(V-2-c) Co-Evolution of Specific Cerebral and Spinal Lesions	90
(V-3) The Key to Decoding Multiple Sclerosis: Specific Data.....	91
(V-3-a) Inadequate Disease Specifications	91
(V-3-b) Reappraising Specific Multiple Sclerosis Observations	92
(V-3-c) Practical Consequences of Specific Observations	93
References.....	95
Overview of Plates.....	107
Plate I: Carswell's "Peculiar Diseased State"	109
Plate II: Cruveilhier's "Four Cases of Grey Degeneration"	110
Plate III: Cruveilhier's "New Example of Degeneration"	111
Plate IV: Charcot's First Illustration of Multiple Sclerosis.....	112
Plate V: Charcot's "Sclerosed Plaques Occupying the Corpus Callosum"	113
Plate VI: Siemerling and Raecke's "Plaques in Cerebral White Matter and Cortex"	114
Plate VII: Putnam and Adler's Multiple Sclerosis	115
Plate VIII: Scheinker's "Perivenous Plaque", Steiner's "Foci of Demyelination"	116
Plate IX: Frommann's "Grey Degeneration"	117
Plate X: Lauenstein's "Acute Myelitis"	118
Plate XI: Carswell's Earliest Depiction of an Arterial Infarction of the Brain	119
Plate XII: Eichhorst's "Inflammatory Foci"	120
Plate XIII: Oppenheim and Cassirer's Multifocal Encephalitis	121
Plate XIV: Venous Predisposition to the Emergence of "Dawson's Fingers" and of Carswell's "Remarkable Spinal Cord Lesion"	122
About the Author	124
Contact.....	125

Challenges

At the present time three measurement tools are generally considered decisive as to whether someone is affected by multiple sclerosis or not: a counter, a calendar, and a clock.

Suppose a patient, for no obvious reasons, goes through **two or more** episodes of a manifest dysfunction of **two or more** separate neuronal pathways: Whether these episodes are simply referred to as “**unexplained neurological deficits**”, or whether they are identified as “**clinically definite multiple sclerosis**” depends solely on **the times at and during which** the dysfunctions are present.

Brought in to resolve the dilemma of a neurological diagnosis, the counter, the calendar, and the clock also determine whether the patient’s various episodes of neuronal dysfunction are ascribed to some mysterious origin or whether they are claimed to have their cause in some particular kind of histological process, i.e. “**primary or auto-immunological inflammatory demyelination**”.

A patient who has been identified as having clinically definite multiple sclerosis is then reduced to the status of a test-subject qualified to be recruited for diverse clinical trials aiming at mastering an imaginary cause of a poorly defined condition. Thus, although “hope springs eternal” and “success is just around the corner”, feelings of uneasiness, even despair, persist.

The sluggishly rising tide of publications on mistaken diagnoses of multiple sclerosis, i.e. patients in whom the diagnosis of a curable disease has been missed, arouses immediate concern. Of more basic interest to the issue, however, are the following principle considerations:

- The improper functioning of any organ, and thus also of a nervous pathway, for any period of time will, of and by itself, never reveal a dysfunction’s cause.
- The succession, in a patient, of diverse neurological episodes of unexplained nature does not justify the assumption that all of these episodes were provoked by only one cause, let alone one determinate cause.
- Finally, no neurological or any other clinical examination can truly anticipate or provide a substitute for findings obtained in anatomical-pathological or histological studies.

This book invites the reader to embark on a critical reappraisal of the subject of multiple sclerosis, to discover where and why medical thinking on multiple sclerosis has gone wrong – and how a more fruitful era of medical treatment of the disease can be initiated.

(I) Genuine Naked Eye Identification

Those who have thoroughly explored the standard works on the subject of multiple sclerosis must have wondered about the significance of the historical drawings chosen as frontispieces for many of these works: Were the masterly old plates to serve merely as embellishments? Were they intended to arouse curiosity? Or were they rather meant to provide essential informations?

The following chapter attempts to make clear that appreciating the strange beauty of these old lithography is not enough: They were meant to tell a story, to point to the key evidence on the disease's nature and cause. Unless this message is fully grasped, there can be no changes in present multiple sclerosis research and therapy, no re-direction toward possible genuine cures and prevention.

(I-1) Pioneering Spinal Cord Findings

The illustrations of the first instances of multiple sclerosis, which showed a specific damaging of the spinal cord, were done seventeen decades ago, and yet their relevance for the proper identification and understanding of the disease's pathology has still not been fully appreciated. By means of these distinctive naked-eye findings alone multiple sclerosis was substantiated as a distinct disease entity, and they thus constitute the standard of reference by which every statement regarding the condition should be evaluated. Because of their crucial conceptual significance, the classic multiple sclerosis-specific spinal cord observations will be the focal point of the following chapter.

(I-1-a) Bilateral Spinal Cord Flank Lesions

Carswell's Testimony

In 1830, Robert Carswell, a young Scottish doctor, was confronted twice with one and the same unknown kind of lesion. This discovery, however, became public only after a number of years, when Carswell had taken over the chair of pathological anatomy in London.

Indicated by Carswell simply as "a peculiar diseased state", imposing itself as a special form of atrophic scarring, the lesion was specifically characterized by an illustration of its brownish, remarkably firm "spots", or, more concretely, their distinctive mode of arrangement. What stirred Carswell's interest in the first place were, even more than the "points" punched into the pons of one of the specimens, what he presented as the "patches" of a "remarkable lesion of the spinal cord" (24).

Carswell did his best to accurately document these findings: In plain drawings - see Plate I – he pictorially defined the pathological changes so clearly that they could hardly be mistaken for a lesion of a different kind. But he did not verbally refer to the lesion's distinctive characteristics, i.e. he did not concretely explain its true peculiarities. His classic illustration gave evidence of the following (for its non-specificity, the softening of the lower cervical cord will be ignored):

There are four pairs of lesions extending specifically along and, in roughly pointed ways, into the spinal cord's flanks. The damage appears thus characterized primarily by its unmistakable pattern of arrangement. In the individual lesion domains two kinds of tissue changes are spread from the spinal cord's lateral contour to different depths. On two spinal cord cross-sections the coherent flank lesions are seen to broadly insert themselves, alternatively on the cord's two sides, into the flanges of the H-shaped girder of its central grey matter.

This entire picture is unique, and of and by itself it holds the key to the understanding of the process of spinal multiple sclerosis.

Cruveilhier's Duplication of Carswell's Findings

Two spinal cord specimens depicted by the leading Parisian pathologist, Jean Cruveilhier, in 1839 and 1841, were marked by scars unmistakably identical to the patches of Carswell's "remarkable spinal cord lesion".

In Cruveilhier's first specimen, taken from an inmate of Paris' vast "Salpêtrière" asylum, the cervical cord was now shown not only anteriorly, but also posteriorly. The uneven extension of the patches exclusively from the spinal cord's flanks was particularly evident, and the tissue lying closer to the lesion's lateral line of origin -- compare Plate II, figg. 1, 1 and Plate I -- was again shown to have undergone more intense changes.

And yet Cruveilhier spoke of the singular marks merely as "reddish grey islets", and referred to their entire appearance simply as "a grey degeneration of the [white matter] columns of the spinal cord" (34).

Cruveilhier's second illustration of multiple sclerosis, once more only vaguely indicated as an instance of "grey degeneration or transformation of the spinal cord" (34), is unique not only in displaying the spinal cord affection in its entirety, but also for its depiction of another typical feature of spinal multiple sclerosis unknown until then: The additional lining up of more circumscribed lesion zones, preferentially along the spinal cord's posterior midline.

As illustrated in Plate II, Cruveilhier's second specimen also paralleled Carswell's previous exemplar in some of the peculiarities of its cross-sectional lesion pattern: The slim, laterally based patch, ending in an apex which deviates markedly towards the spinal cord's posterior midline, together with the broader, also peripherally based posterior lesion wedge (34), distinctly reflect the manner of lesion spread: A consistent alignment preferentially with the spinal cord's lateral contour and a continuous, unusually oriented encroachment upon the neighboring tissues. In connection with their peculiar positioning, the patches' manner of extension thus appears different from that of any other lesion.

Charcot's Report on Spinal Multiple Sclerosis

In 1865 a specimen exhibiting the maximum possible longitudinal extension of direct damage to the spinal cord's flanks was detected by Jean-Martin Charcot while working as a pathologist

at the "Salpêtrière". Even more remarkable than his personal post mortem observation, however, was his synoptic summary of the then available illustrations of corresponding affections of the spinal cord's flanks. This original, anatomically substantiated understanding of spinal multiple sclerosis (which he later, unfortunately, speculatively modified) has hardly ever been taken note of, since it was merely expressed in the form of a footnote to this specific case report.

This footnote deserves special attention as it seems to constitute the sole historical advance towards a consistent specification of spinal multiple sclerosis - originating simply by Charcot's intuitive equation of his specific observations with Carswell's and Cruveilhier's identical findings (shown on Plates I and III).

In the specimen which Charcot himself described, both flanks of the spinal cord were affected in their entire lengths, yet to varying depths: In the spinal cord's thoracic section, the quite symmetrical lateral lesion wedges extended deepest by far, only to lose substantially in depth, both upwards from the spinal cord's cervical, and downwards from its lumbar enlargements, vanishing completely at the cord's upper end -- cf. fig. 3 of Plate IV , and figg. B and C of Plate V -- and lower end (26).

(I-1-b) Primary Multiple Sclerosis Specification

Since Charcot's 1865 paper, no substantial advances in the gross characterization of the spinal patches of multiple sclerosis have been made, provided the condition be understood as a specific form of pathology directly identifiable with Carswell's "remarkable spinal cord lesion". As regards the lesion's tissue changes, however, neither the apparent discolorations nor the related hardenings are of and by themselves in any way distinctive. The abnormal tissue, with its singular patterns, merely puts the specific changes into relief.

(I-2) Detection of Distinctive Brain Lesions

One of Carswell's and both of Cruveilhier's archetypal multiple sclerosis specimens were also marked by pontine lesion spots. But -- as Plate I , figg.1, 1' and Plates II and III clearly demonstrate -- the pattern of all these damages to the pons' front differed essentially from that of the specific patches of the spinal cord, both as to lesion configuration and grouping. Remarkably, both Carswell, who discriminated the spinal scars as "patches" and the pontine marks as "points", and Cruveilhier, who initially depicted spinal and pontine "islands" in different colors, considered the pontine and spinal lesions as damages pertaining to one and the same pathology.

The question arises: What motivated these two pathologists to present the separate injuries to pons and spinal cord as lesions of the same nature, despite their different configurations and arrangements? Formally, the pontine "points" and specific spinal "patches" could hardly be

regarded as identical. What, therefore, justifies Carswell's and Cruveilhier's assumptions as to the two lesion types' specific relationships?

(I-2-a) Ventricle-Based Knuckles, Fingers, and Fists

It was probably not only the lesions' similar discoloration and firmness which made Carswell and Cruveilhier suppose that the concurrent brain and spinal cord lesions represented the same pathology. Also the comparable size and compactness of the spinal "patches" and pontine "points" might have encouraged them to make this inference. However, the idea that the not yet absolutely distinctively specified multicentric rounded brainstem damages and the specifically patterned flank lesions of the spinal cord were related pathologies, was soon to be supported by other post mortem observations.

Unexploited Discoveries by Charcot

A somewhat more instructive cerebral lesion picture was presented in 1867, in a 35 year old victim of multiple sclerosis, who had died in the "Salpêtrière". There were written indications that the spinal cord's flanks had throughout been primarily and, in their lumbar section exclusively, injured. The illustrations of these findings -- see Plate IV, figg. 3, 4 -- further provided clear evidence of the presence of a spinal lesion identical to those referred to above (93).

Truly revolutionary, however, was Charcot's masterly depiction of a lesion quite simply described as "a sclerotic plaque affecting the wall of the lateral ventricle [of a cerebral hemisphere]", elsewhere characterized as "grey sclerotic plaques, like scars, in the walls of the ventricles, up to a thickness of one centimeter" (93). The particular figure 1 of Plate IV actually shows the massive, undulating expansion of a quite homogenous lesion into the otherwise undamaged tissues of the roof of the brain's lateral ventricle. The lesion embeds prominent veins, coursing within often distinct, eccentrically widened perivascular spaces.

This plate of Charcot's is of inestimable evidential value: In it we find illustrated for the first time the entire spectrum of multiple sclerosis-specific changes, i.e. both the cerebral plaques' vein-related expansion in the ventricular wall and the spinal patches' extension along and into the spinal cord's flanks. Charcot, the renowned "Father of Clinical Neurology", has never been duly acknowledged for this, his potentially most momentous achievement. This lack of recognition may, in part, have been due to the incorporation of Charcot's masterpiece into a thesis by a little-known pupil of his, Leopold Ordenstein, focusing mainly on the in vivo manifestations of the disease.

In 1884, other valuable pictorial documents of Charcot's on the subject of multiple sclerosis appeared. Although presented merely as "sclerotic plaques affecting the corpus callosum on its ventricular side", the illustrated lesions (cf. figure A of Plate V) for the first time revealed another peculiarity of the condition's brain pathology: In the corpus callosum, the main connection between the cerebral hemispheres, a series of smooth, interconnected lesion spikes

and waves arises perpendicularly off of the corpus callosum's underside, into the substance of its bulky bow. Against the healthy surroundings the damage appears sharply delineated throughout. As regards the lesion figures B, C, and D (Plate V), particular interest is due not so much to the illustrations of typical pons plaques as to the depiction of the related lateral spinal patches' upper terminations (31).

Charcot's "Lectures", however, referred to these truly unique brain and spinal cord lesion pictures simply as "unpublished [multiple sclerosis] observations".

Siemerling and Raecke: Serial Sections of Specific Cerebral Changes

In 1914, Ernst Siemerling and Julius Raecke, physicians at the Hospital for Nervous Diseases in Kiel, Germany, again demonstrated cerebral findings identical to those by which cerebral multiple sclerosis had first been pictorially specified. Plate VI discloses their illustration of this particular kind of brain lesion in a series of sections drawn parallel to the brain's median plane: In the cerebral hemispheres, there emerge ventricle-based plaques, expanding straight out in the direction of the cortex. The corpus callosum lesions evolve in a comparable way. The cerebral damage's mode of spread -- compare Plate IV, fig. 1, Plate V, fig. A, and Plate VI -- is here obviously the same as that in Charcot's cases, although the lesion pattern appears more diversified.

Siemerling and Raecke also seem not to have been aware of their observation's unique nature and implications. They merely indicated a "sclerosis of the ventricular linings", "extensive plaques and numerous smaller foci in cerebral cortex and white matter", a penetration of the corpus callosum by "large lesions", and the presence of "additional foci" in spinal cord, optic nerve, and brainstem (127).

Dawson's Conceptual Switch

In 1916, the unique naked-eye appearance of multiple sclerosis of the brain was correctly defined, curiously enough, in a work devoted to elucidating the condition's tissue changes, histologist James Walker Dawson's "The Histology of Disseminated Sclerosis". Regarding the naked-eye findings in the spinal cord of Dawson's standard specimen, there was mere mention that "the [spinal cord] sclerosis frequently mapped out the triangular portion between the anterior and posterior root entry zones and extended inward to involve the grey matter", and that posterior lesions appeared centered by the median or paramedian septum of the spinal cord (35).

Dawson's Description of Cerebral Damages

The dense sclerosis encompassing the brain's lateral ventricles originates in separate, roughly finger-, dome- or cone-shaped lesions arising immediately upon the ventricular lining and surging, or digitating as it were, outwards off of this lining. Peripherally, the otherwise smoothly rounded or crested lesion elevations tend to flatten against the bordering cerebral

cortex. Ventricle-based and separate more peripheral plaques can fuse into ampulla-shaped lesions, whose neck tissue is often only slightly affected. Other ventricle-based lesion-projections appear outwardly prolonged into a co-axial series of peripheral plaques (35).

The peculiar lesion-expansions off of the ventricles, now commonly referred to as "Dawson's fingers", were observed to force their way more easily into the brain's white matter, such as that of the corpus callosum, than into the central nuclei's and cerebral cortex' grey matter. In places the "fingers" were found to invade both of them. Comparable lesion formations appeared to sit, like hoods, on the lateral ventricles' three "horns" (their three extensions' ends) or to rise into apices or rounded offshoots of varying lengths. Other plaques directly silhouetted part of the ventricles' edges by an outwardly wavy or spiky front line, occasionally rising into peaks broadened and flattened at their contacts with the cortical border.

In focusing primarily on multiple sclerosis of the brain, Dawson's famed account marked a definite switch in researchers' attention from spinal to cerebral multiple sclerosis, thus virtually adopting the lesion's cerebral form as a pathological entity in its own right. Subsequently, accounts on multiple sclerosis of the spinal cord comparable to Carswell's "remarkable spinal cord lesion" ceased to appear.

Steiner's Lesion Sketches

In 1931 Gabriel Steiner, at the University of Heidelberg, drew vivid pictures of the spread of multiple sclerosis into the cerebral hemispheres. Apart from presenting schematic drawings of process-typical intrusions into the cerebral cortex from its outer side, he illustrated impressively the specific plaques' bumpy, stalked or splashy projections off the ventricular borders. Because the lesion formations preferentially burst forth at the lateral cerebral ventricles' outer angles, this site was referred to by the telling German name "Wetterwinkel", denoting a source of thunderstorms and deluges. This site has also come to be known as "Steiner's Wetterwinkel". All in all, Steiner's pictures lucidly highlighted what Dawson's description of cerebral multiple sclerosis had disclosed fifteen years before (134).

In 1962 Steiner, then at Wayne State University, demonstrated again that cerebral multiple sclerosis is primarily characterized by smooth, rounded or peaked lesions rising off of the ventricular border. Besides showing that ventricle-based lesion "tongues" can also connect with more peripheral plaques, Steiner now observed that isolated, ovoid or spherical lesion "splashes" also arise from blood-vessels far away from the ventricles (135). Such separate plaques are here referred to as "Steiner's splashes".

As regards the specific patches of the spinal cord, Steiner never mentioned anything of their essentially different image as compared with that of the brain plaques. His 1962 publication nevertheless revealed some interesting details: Its three sections of a piece of lower thoracic spinal cord showed, as can be seen in Plate VIII, B, that the lesions to the spinal cord's sides are formally quite different from the injuries surging up off of the cerebral ventricular border (135).

(I-2-b) Cerebral Multiple Sclerosis: A Pathological Entity in Its Own Right?

Steiner's publications are clear examples of just how, from Dawson onwards, the specific image of spinal multiple sclerosis ceased to be taken note of. In fact, the lesion extension along, and into, the spinal cord's flanks directly identifiable with that of Carswell's "remarkable spinal cord lesion" has never again, since Dawson's time, been demonstrated.

Neither Charles E. Lumsden, who pointed to the "knuckles" by which multiple sclerosis first may poke into the brain (69), nor Colin W.M. Adams, who depicted a corresponding "fist" (2), ever referred to the multiple sclerosis-specific spinal lesion's radically different mode of development.

It must be emphasized that such terms as "knuckle", "finger" or "fist" are absolutely adequate, in fact unsurpassed in illustrating the multiple sclerosis-specific brain injuries' massive, directed punches -- but that these terms are entirely inappropriate for characterizing the related, bizarrely angulated lesion encroachments upon the spinal cord's flanks. Yet before delving more deeply into this problem, another distinctive trait of cerebral multiple sclerosis, equally perceptible to the unaided eye, must be focused upon.

(I-2-c) The Specific Vein-Relationship of Cerebral Multiple Sclerosis

Whereas Carswell's lateral spinal patches, according to the condition's classical illustrations of Plate I, Plate II, figg. 1, 1, Plate III, Plate IV, figg. 3, 4, and Plate V, figg. B, C, D, did not seem to be pervaded by any special structures, Charcot's specific brain plaque was, as fig. 1 of Plate IV immediately discloses, plowed through with conspicuous vascular channels. Knowledge of cerebral vascular anatomy enables us to identify these ramifying structures as relatively large veins draining the central parts of the cerebral hemispheres. This relationship appears unusual enough to merit a concrete, careful scrutiny.

Charcot: First Indication of a Plaque-Vein Relationship

A closer look at figure 1 of Plate IV, Charcot's first illustration of cerebral multiple sclerosis, reveals the following: The lesion is spread about the periventricular veins' central course, i.e. the injurious process primarily involves the stronger vein segments. In addition, the peripheral lesion projections show a certain dependence on the course of major venous branches. The involved vein lengths themselves appear partly contoured by distinct, generally one-sided or at least eccentric widenings of their perivascular spaces. As to the actual wall of the lesion veins, however, the illustration does not reveal anything unusual.

Curiously, it is not Charcot but Otto Buss of Göttingen who is generally credited with the discovery of a vein-relationship of the lesions of multiple sclerosis in general. What is thereby consistently referred to is a case report of Buss', presented in 1889 (22), whose macroscopical lesion description seems at least compatible with a multiple sclerosis-specific affection of certain lateral and posterior sectors of the spinal cord. The observation that only the brain

lesions preferentially harbor one larger or several medium-sized veins is also of interest. Yet neither as to the spinal cord nor to the brain did Buss provide a lesion specification which proves really distinctive of multiple sclerosis. In the given context, his report therefore deserves not to be paid further attention to.

Dawson's Detailed Evidence

The first written indication of an involvement of periventricular veins in the process of cerebral multiple sclerosis, as related by Dawson, revealed the following: In the extensive areas of sclerosis immediately contiguous with the brain's ventricles, some large collecting veins running immediately underneath the ventricular lining, so-called subependymal veins, are directly outlined by zones of gelatinous tissue. The involved vein walls appear partly homogenized, lacking their normal structural differentiation, and are encompassed by distinctly widened perivenous spaces in which residues of minor hemorrhages are to be found (35). Nothing was mentioned as regards the significance of all these peculiar changes.

Putnam: Remodeling Brain Lesions and their Veins

Tracy J. Putnam and Alexandra Adler illustrated for the first time, in 1937, that cerebral plaques characteristically spread in a rather odd, specific relationship to large ependymal veins and, further, to bizarrely altered affluents of these vessels. These researchers' most relevant observations are comprehensively summarized in Plate VII. Their three-dimensional reconstruction model of one particularly interesting, serially sectioned brain specimen demonstrated especially well the curious distensions and distortions of the involved veins.

Plate VII shows their observations made on a section of cerebral white matter, thirteen millimeters by nine, which contained some veins arising nearly perpendicularly off the ventricular border. The specimen stemmed from a patient whose nervous affection was said to have run for twelve years a course typical of multiple sclerosis and whose post mortem was simply noted to have demonstrated "spread throughout brain and brainstem, numerous old and fresh plaques" (109).

The small brain specimen illustrated in Plate VII is of inestimable informative value. It shows a ventricle-based lesion cone, a typical "Dawson's finger", projecting along an oddly distended affluent of the major venous conduit running within the ependymal sclerosed area. Additional isolated plaques ("Steiner's splashes") have also emerged, farther out, from the main branch of the distended vein of the "Dawson's finger", along its grotesquely distorted peripheral course, and from the trifurcation of a small affluent of another ependymal vein. The specific epi- and paraventricular cerebral lesions were thus, for the first time, demonstrated to rise along and expand from definite segments of usually fairly large periventricular veins.

Fog on the Vein-Conditioned Plaque Development

In 1965 Torben Fog, directly investigating the multiple sclerosis-specific cerebral lesions' relationship to the course of their veins, found the distinctive plaques to consistently develop in a peculiar dependence upon definite vein segments.

Not only any lesion spread along and any digitation ("dragging") of damages off of the ventricular border, but also any projection of isolated plaques beyond the reach of the ventricle-based "Dawson-fingers" stood in direct relationship to definite stretches of the lesions' "central" or "parent veins". The lesion advance from these vein segments proved regularly, and often strikingly, eccentric: Fog showed impressive images of veins somehow clinging to their lesions, and of plaques expanding extensively to only one side of a large vein, or also a bulky conglomerate of such veins.

Both the lesions' first emergence at, and their expansion off of, the cerebral ventricular walls thus proved to be determined by great venous trunks collecting the blood from inside the cerebrum, respectively by some of these veins' affluents. Especially the isolated peripheral lesions were found to preferentially emerge from their plaque-veins' bends, branchings or terminal ramifications. The veins involved again exhibited unusual tortuosities, twistings and distensions.

Although the largest lesions were commonly found to have emerged from large veins, the range of a lesion's expansion from the vessel wall could not be said to have stood in any definite proportion to the involved vein's caliber. Another curious finding concerned abrupt peripheral endings of large, cylindric, perivenous lesions without any discernible modification in their plaque-veins' walls (48).

Lumsden and Adam's Confirmatory Observations

In once more providing unmistakable pictorial evidence on the venous conditioning of cerebral multiple sclerosis, Charles E. Lumsden, in 1970, observed that in the brainstem as well multiple sclerosis-specific plaques consistently originate on veins. Specific pons lesions were accordingly shown to equally evolve as vein-dependent "Dawson-fingers" (71).

The results of Colin W. Adams' researches into the development of cerebral multiple sclerosis, on the other hand, led to a fresh realization of the fact that "the early stage of the periventricular plaque is the formation of a lesion around a subependymal vein" (1). Besides thus confirming that the changes definitively set out from veins running underneath the cerebral ventricular lining, Adams again found the lesion spread into the periphery of the cerebral hemispheres to be consistently related to the course of particular veins. The fluid inside the cerebral ventricles was accordingly not felt to play a part in the specific lesion developments (1,2).

(I-3) Macropathology: Unexploited Key Evidence

The initial identification of multiple sclerosis as a distinct kind of pathological process was founded on specific post mortem findings of a spontaneously arising spinal cord lesion, which was to be recognized with the naked eye alone (24,34,26). The peculiar spinal cord pathology was then found to be frequently correlated to a different, again simply macroscopically discernible brain pathology (93,31).

Charcot, who for the first time put together evidence on the specific involvement of the spinal cord's sides, and first clearly documented the spread of related and no less distinctive damages in and off of the cerebral ventricular border, seems also to have been the earliest observer to point out that multiple sclerosis is essentially defined by its unique and uniform gross pathology (17, 29). And it has since been confirmed again and again that, in typical cases of multiple sclerosis, the specific lesions can confidently be identified with the naked eye alone (44).

However, in those medical communities presently involved in multiple sclerosis research and treatment there seems as yet to be no full agreement on which traits ultimately distinguish multiple sclerosis. On the one hand, it has been explicitly stated that the diagnosis of multiple sclerosis can be made definitively at post mortem alone (84). On the other hand, it seems to be widely presumed that there are no morphological findings peculiar to the disease. The unique macroscopical lesion characteristics have gained little attention and the condition's dual character, i.e. the fact that cerebral and spinal multiple sclerosis, though commonly emerging side by side, present essentially different pathological pictures, has as yet not been properly realized. If, in keeping with current thinking on the theme, the condition's histological and clinical conceptions are considered first, it should not be forgotten: For the purpose of elucidating the condition's nature and cause, no more reliable information can be found than that provided by naked eye pathological findings.

(II) Histological Perspectives

“Between the motion and the act falls the shadow.”

T. S. Eliot, 1925

We have now reviewed the first demonstrations of the existence of a specific form of multiple sclerosis pathology. Irrespective of the meticulously exact depictions, all of these findings were of a fairly crude nature, in that they were merely naked eye observations. And yet the pathological condition was reliably identified simply by rendering the observed patterns of lesion spread.

Following the spirit of the times, the descriptions and categorizations of these findings referred primarily to the tissue changes inside the distinctive spinal and cerebral lesion-domains. The way in which - and the reasons why - these particular changes were ultimately subsumed under the rather bland name of multiple (i.e. multi-centric) sclerosis are of special interest for the understanding of the condition.

Eventually, however, continuous (re-)interpretations and (re-)categorizations of the exclusively anatomically specified findings solely in histological terms, by promoting endless speculations regarding the disease's origins, were to hinder rather than further the elucidation of its nature.

(II-1) Tissue Changes in Specific Lesions

Considering the marked differences in mode of disposition, configuration and delimitation of multiple sclerosis spinal cord lesions as against those of the brain, the question arises as to whether spinal patches and cerebral plaques might not also differ in their tissue changes.

Currently both lesion types are referred to simply in the same clichéd histological terms. For the first time, in this book, the instructive original microscopical lesion accounts which unmistakably reflect the specific pictures of multiple sclerosis of the spinal cord and brain will be comparatively analyzed to bring into relief the histological features which distinguish spinal cord from cerebral lesion types.

(II-1-a) Histology of Flank-Lesions of the Spinal Cord

The brownish lesions shown in Plate I extend via a distinct greyish fringe zone. Figg. 1, 1' of Plate II show dark lesion cores encompassed by a differently colored tissue affection. Yet in describing their findings, neither Carswell nor Cruveilhier alerted the reader to the fact that, in the spinal cord, the lesions' central and peripheral ranges were so different. In suggesting an even discoloration and scarring of all the involved parts, the changes were simply referred to, in the first instance, as "atrophy" and, in the second, as "grey [tissue] degeneration"(24,34)

Presented by Ernst Leyden in 1863, the first microscopical account of pathological findings corresponding specifically to Carswell's "remarkable spinal cord lesion" described only a non-specific nerve fiber degeneration (65). Leyden's specimen was subsequently subjected to Carl

Frommann's far more thorough microscopical analysis (50) and was found to exhibit a number of characteristic histological changes. In the meantime, Charcot's 1865 case report on spinal multiple sclerosis (26) had already indicated some new histological details.

Axons Bared of their Myelin Sheaths

In Charcot's report on that extensive affection of the spinal cord's flanks, which he intuitively considered identical to Carswell's and one of Cruveilhier's observations on spinal multiple sclerosis, an occurrence of denuded axons in multiple sclerosis was made mention of for the first time. In a microscopical study carried out with the assistance of Charles Jacques Bouchard (26), Charcot observed the following: The sclerosed parts consist of a tightly woven fibrillary connective tissue. Already outside their dense cores, the nerve fibers, i.e. both axons and myelin sheaths, appear to be wasting away. Towards the lesion centers this atrophy of nerve fibers is aggravated, until only a few thin, even strangled, axons with very scanty myelin-coverings can be detected. The patches' interiors harbor many amyloid (dead cell) bodies, some interstitial cell nuclei, and scarce "granulations of fat" (representative of agglomerates of degenerated myelin or myelin-stuffed scavenger cells).

Charcot concluded his descriptions: "In the outermost part of the [spinal cord's] lateral columns, where the nerve fibers are the most rarefied, one observes, here and there, axons which are completely devoid of their myelin [sheaths]. The spinal cord's central grey matter, nevertheless, does not show any perceptible alterations; all nerve cells encountered are in their normal state" (26).

Frommann: Primary Fiber Hypertrophy and Fibril Hyperplasy

The most exacting microscopic analysis ever made of the specific involvement of the spinal cord's sides was presented by C. Frommann in 1867. The results of his countless painstaking observations, illustrated in meticulous detail, can only be offered here in a very condensed form.

The specific patches' zonal differentiation: As the figures of Plate IX particularly well demonstrate, the microscopical picture of the distinctive spinal cord lesions presents various peculiarities: Not only do tissue changes extend beyond the directly visible lesion domains, but the structural changes within the individual patches also show a spatial gradation into different zones (Plate IX, figg. C and D). Rather than summarily rendering the modifications of the different tissue elements, Frommann carefully analyzed the ways in which every tissue component had been changed in each of the succeeding lesion zones. He reported the following: The lesion's basal, i.e. most lateral, zone (Plate IX, fig. F) extends for about one millimeter underneath the pia mater, the spinal cord's fibrous covering. Here the interstitial fibrous meshworks appear broadened and eventually tend to fuse. The changes extend first along fibrous septa and vessels -- main braces of the involved areas' mechanical framework -- to subsequently encroach upon the nets of connective tissue fibers extending between the

individual nerve fibers. Finally, this process is seen to advance upon and gradually occupy the nerve fibers' space.

In the basal lesion zone, with its shrunken and often grossly distorted connective tissue meshes, the nerve fibers have generally disappeared. A few axons are bared of their myelin sheaths, or invested with oversized ones. Figure F of Plate IX reveals that a mere swelling of myelin sheaths occurs side by side with a complete melting down of connective tissue structures to homogenized lumps or layers.

Plate IX, figg. C and D best demonstrate what Frommann described as the lesion's "second zone", the patch's densely fibrosed core. Here, except for a few thick-walled blood vessels that enter the cord's sides in deep-reaching tissue clefts, the picture of the cord's normal tissue fabric has been entirely effaced by a dense feltwork of very fine glia fibrils (very fine fibers of indigenous connective tissue), which are responsible for the patch's striking firmness. The dense fibrillary transformation of the lesion core is not really homogenous but interlaced with less severely fibrosed areas. Thus even fully scarred regions sometimes appear broken up by stripes of minimally altered tissue (Plate IX, fig. C) containing grouped axons and even whole nerve fibers.

Frommann's most interesting picture, however, presents the lesion's third zone, its zone of transition to normal tissue. The drawings of a lateral lesion's deep – cf. Plate IX, fig. C -- and posterior front or, more precisely, fringe zone – cf. Plate IX, fig. D – illustrate how the changes typically advance: Out of the lesion core, consisting of a dense felt of very fine fibrils, issue numerous spiky, angulated, even barbed processes, evolving by way of a progressive broadening of already previously conspicuous connective tissue structures. The various peaks of the lesion's advancing edge represent simply a fluid transition of such abnormally broadened fibrous structures into normally prominent ones.

In focussing as closely as possible on the minutiae in the changes of the different tissue elements, Frommann made several pioneering observations:

1. Investigating the behavior of the (astro-)glia fibers (the connective tissue structures proper to the brain and spinal cord), he noted that the involved fibrous tracts develop at first a strikingly dense outline and abnormal breadth, to even more than a sixfold extent of their normal size.
2. Once the structures have attained a certain thickness, tiny fibrils begin to form, at first inside their most condensed parts, and then to spread out of poorly delimited segments of the broadened fiber tracts' edges.
3. To Frommann's surprise, invasions of glia fibrils into the spaces of the nerve fibers were already traced before the nerve fibers or myelin sheaths were altered. Frommann

therefore concluded that the initially perceptible hypertrophy and hyperplasy of the affected connective tissue structures had to represent the lesion cause.

Conceiving of the lesion simply as an excessive overdevelopment of particular connective tissue structures appeared all the more justified in light of other findings, such as those testified to in figures E and F of Plate IX, namely accumulations of astroglia cell nuclei, a progressive outgrowth of new fibrils from sprawling fibrous structures, and even complete fusions of all sorts of connective tissue structures amidst, or directly adjacent to, not visibly altered nerve fibers and myelin sheaths. Curiously, old as well as newly formed glia structures could melt down, i.e. become affected by degenerative homogenizations, during any stage of their broadening or fibril formation.

Blood vessels played a curious role. Figures C and D of Plate IX show that especially the lesion's dense core tended to be broken through by strong blood vessels entering the spinal cord's sides in deep-reaching tissue clefts. Ruptured glia fibers or fibrils projected into part of these clefts. Frommann observed that the opening up of these clefts could only be understood as the effect of some mechanical impact.

An initial glia fibril formation, comparable to the one observed along broadened fibrous septa, also preferentially set out from definite lesion vessels, especially from the angles of their branchings. Along the affected vessels, newly formed fibrils frequently melted into circumferentially arranged layers of homogenized tissue, accumulating in definite directions off the vessel walls. Thus these vessel-based fibril growths and fusions tended overall to be contoured like mountain ranges.

Very early on in the progression of the affliction the small vessels pervading the patches' farthest extensions showed uneven thickenings of their walls and bizarre protrusions into their openings - some of which protrusions were bulky enough to block the vascular passage. Yet despite the frequency of these changes, not a single thrombosed vessel was found.

Regarding the nerve fibers, the losses of myelin-sheaths were very conspicuous. But also the axons showed manifold abnormalities, sometimes even within a not visibly altered myelin sheath. Gross axon swellings occurred, often in series along a nerve fiber's course. Elsewhere the axons -- as figure E of Plate IX demonstrates -- had perished in entire groups or rows. What was thus wasting away were both axons and myelin sheaths, the axons vanishing but more slowly.

Where lesions eventually had reached the spinal cord's central grey matter, nerve cell damages -- abnormal pigmentations, granulations, layered condensations of the cell periphery, wasted cells, dead cells -- were equally obvious.

Noticeably, even with severe tissue destructions, neither in the nervous tissue nor in its perivascular spaces were any fat granule cell (scavenger cell) accumulations or round cell (immunocyte) infiltrations to be traced.

As to the dynamics of the lesions' spread, Frommann confirmed Carswell's conclusions that the specific changes had first involved the spinal cord's lateral periphery and from there gradually proceeded centrally (50). But the questions were apparently never addressed as to 1) why the lesion domains extend in this peculiar way, 2) why definite fibrous structures become primarily modified, and 3) why also the other tissue components undergo the changes detailed above.

Lauenstein's "Myelitic Softenings"

Findings recorded by Carl Lauenstein in 1877 illustrate spinal multiple sclerosis, in a peracutely lethal case, not with sclerosed patches, but with circumscribed softenings. A comparison of the lesion patterns presented in Plate I and Plate X, i.e. of Carswell's standard instance of multiple sclerosis and Lauenstein's instance of "myelitis", leaves no doubt as to formal identity of the former's scars and the latter's softenings. But as to histological characteristics, Lauenstein's specimen differed distinctly from that of Carswell: From the third cervical down to the first thoracic segment, the entire spinal cord appeared somewhat soft. Although the local blood vessels proved conspicuously engorged, there were no indications of their being otherwise affected. The actual tissue softening was limited to the spinal cord's most lateral parts. Here, both interstitial connective tissue structures and nerve fibers showed an abnormal coloring, the fibrous glia tracts appeared swollen, and their cells distinctly enlarged. Mainly in the surroundings of the lateral lesions' larger blood vessels, the tissue's continuity was interrupted by homogeneously filled tissue clefts which were yet not directly continuous with the perivascular space.

Microscopically, the following observations were made: In the lateral lesions' central halves, all nerve fibers were abnormally intensely colored. Axons were hardly discernible from myelin sheaths and appeared at best as very fine points. The terminal lesion extensions were again chiefly characterized by axon swellings differing remarkably in intensity from region to region. Along the individual axons' courses, circumscribed ballooning and even corkscrew-like distortions -- see Plate X, lower right-hand corner -- tended to recur. However, the lack of a myelin sheath on a nerve fiber appeared to be due simply to the fact that the axon completely occupied the nerve fiber's space.

In addition, Lauenstein observed, outside of the actual flank lesions, a sporadic occurrence of swellings of definite clusters of axons or nerve cells distributed in a pattern of rounded dots shown on the spinal cord cross-sections of Plate X. Supposing that these foci had developed without a direct structural connection to the specific lateral lesions, they had to be considered the result of some complications such as ischemic events. At any rate, neither here nor in the

specifically affected areas were any perivascular white blood cell immigrations or scavenging fat granule cell accumulations to be traced (64).

Dawson: Diverse Spinal Tissue Changes

In his monumental work on "disseminated sclerosis," James Walker Dawson did not refer to any of the specific observations of multiple sclerosis mentioned above. Among the nine specimens which Dawson described, there is only one in which the distinctive traits of both spinal and cerebral multiple sclerosis can be reliably identified. For no obvious reason, Dawson's investigations concentrated mainly on this, his first, standard specimen. The results of these researches are of the utmost importance as they offer an unmatched opportunity for a direct comparison of the tissue changes of specific lesions of both spinal and cerebral multiple sclerosis.

In his attempt to elucidate and define the overall lesion nature, Dawson focussed primarily upon the development of histological changes. Curiously, although the damages to the spinal cord's sides and its posterior flank appeared attributable to the same kind of injurious events, the respective tissue changes were in fact decidedly different.

The classic affection of the spinal cord's sides was found to evolve as follows: In the lateral lesion domain any connective tissue formation, from fibrous septa, tracts and strands down to the finest interstitial meshworks, broadens, appears more and more condensed, and then bursts out in a feltwork of sprawling fibrils which subsequently tend to fuse. Amidst all these changes, the fiber and fibril-forming astroglia cells, as well as their processes, remain unusually prominent for long periods of time.

Simultaneous with the onset of the glia fibril formation in the affected zones, myelin sheaths and axons begin to dwindle away. These changes evoke the impression that the nerve fibers are being directly encroached upon and finally strangled by a circumferentially advancing fibril hyperplasy. The involved vessel walls also begin to thicken and condense, though at a slower pace. Throughout all of this only negligible perivascular inflammatory cell infiltrations, as well as fat granule (scavenger) cell developments, occur.

Prominent fibril formations also emerge preferentially from the local blood vessels' rather protractedly thickening walls. In their cross-sectional image, the perivascular fibril growths typically radiate in the form of a "corona ciliaris". Ultimately the ubiquitous sprawling of glia fibrils culminates in the formation of a dense fibrillary feltwork spreading throughout the entire affected area.

The lesions of the spinal cord's posterior flank, extending from its median and paramedian septa, show a different development. The onset of the injurious activities here is typically heralded by a swelling of only interstitial glia cells, followed soon by a comparable swelling of all other tissue elements. These tissue swellings are accompanied by plain vascular engorgements of a minor degree.

In the posterior lesions' marginal or transitional zones, the whole nerve fibers appear, from the outset, distinctly enlarged, and the myelin sheaths in the lesions' depth are often found to have broken apart. The axons, on the other hand, retain a swollen configuration, though entire groups of them may also break apart.

As a reaction to the injury throughout these posterior lesion areas, massive proliferations of both astroglial and scavenger cells arise. The scavenger cells' incorporation of debris quickly gives them the appearance of fat granule cells, and they leave the lesion site by way of neighboring perivascular spaces. In the typical posterior spinal lesions, an interstitial fibril formation and mild perivascular infiltration of lymphocytes, i.e. immunocytes, can only be traced from this stage on.

While studying the tissue changes of an unquestionable specimen of multiple sclerosis, Dawson, as previously Frommann, also discovered that it is not a breakdown of myelin sheaths but a swelling of interstitial tissue structures which first heralds spinal lesion developments. Similar to Frommann, Dawson again considered this initial hypertrophy and hyperplasy of local connective tissue structures to have been provoked by the causal agent itself (35).

(II-1-b) Histopathology of Cerebral Plaques

As to the distinctive lesions of the brain, it is extremely important to discover the cause(s) of their evenly affected lesion areas' typically closed and rounded delimitations, which stand in stark contrast to the spinal patches' fraying out into irregular fringe zones. The fact that only the brain plaques appear so smoothly punched out obviously has a particular physical reason, and the most comprehensive and reliable information on this point was provided by Dawson. The following is a summary of his standard account:

Regarding the primary histological changes, the cerebral plaque's domain does, as a whole, not differ essentially from the posterior spinal patch's border zone. Initially, everywhere in the lesion area, up into its outermost periphery, there is a swelling and massive proliferation of astroglial and scavenger cells. External to such a plaque border a few relatively small interstitial cells, each exhibiting a fairly round and dense nucleus, have begun to multiply. Yet there also are cerebral plaques whose entire domains are evenly marked; up to their outermost front; by an immediate destruction of nerve fibers, i.e. both axons and myelin-sheaths. Around corresponding lesions there is a scattering of fat granule cells rather than — as in the posterior spinal lesion -- a swelling or hypertrophy of interstitial cells.

In the cerebral plaques themselves it is again the myelin sheaths which are commonly more affected. But also the axons show swellings, vesicular distensions, and even complete disintegrations throughout. In the brain lesions, the axons generally appear to be more severely damaged than those in the patches of the spinal cord. In keeping with this, both myelin sheaths and axons are, in the cerebral plaque domains, often broken up into fragments. Thereby globules and granules representing the axons' remains are still lined up in rows, or also

scattered into neighboring tissue meshes. Occasionally, axon fragments appear amassed into greater clumps. or may already be found incorporated into scavenger cells.

Overall, the emergence of the cerebral plaques shows a distinct relationship to definite particularly conspicuous blood vessels, which appear -- often together with their perivascular spaces -- from the outset extraordinarily engorged and enlarged. And also in the brain the changes of the different local tissues regularly precede any degenerative and inflammatory changes of the walls of the lesion vessels themselves.

In the cerebral plaques, comparable to the subacute posterior spinal cord lesions, slight infiltrations by small round cells, of perivascular spaces and tissues are occasionally to be found. Because of their late and slight appearance, Dawson interpreted these reactions (and with this any local immunocytic activity) as being of a secondary nature, having been provoked by the perivascular accumulation of debris-laden scavenger cells (35).

(II-1-c) Spinal and Cerebral Multiple Sclerosis: The Same, and Yet Not the Same

The most important and characteristic feature of multiple sclerosis lesions, in Dawson's view, was the presence of densely ordered rows of large astroglial and fat granule cells in spaces normally occupied by nerve fibers. However, this lesion specification stood at variance with Dawson's own observation that there are not scavenger cells but rather a primary interstitial fibrosis in the classical lateral lesions of the spinal cord. Dawson considered that the lateral spinal cord patches' common lack of fat granules and small cell infiltrations might be attributable simply to a slighter degree of injury. The posterior spinal lesions and cerebral plaques were in fact marked by more massive devastations, but crudely broken-off myelin sheaths and rows of axon fragments also occurred in the lesions of the spinal cord's sides.

One additional consistent histological lesion characteristic was the particularly intense scarring of the affected regions. The fibrotic connective tissue reaction was found to be more vigorous than that resulting from comparable central nervous damages of a different origin, not only in the spinal patches but also in the cerebral plaques. But contrary to the situation in the spinal cord's sides, in the brain and posterior spinal cord, the glia fibrils' exuberant sprawling evolved only in the final lesion stage.

As to cerebral plaque development, Dawson's findings were quite revolutionary. Since Frommann the pathological changes in the spinal cord's sides had been thought to originate in a primary interstitial fibrosis. Dawson was the first investigator to show that, although related, the tissue changes in spinal and cerebral lesions do not necessarily evolve in the same way: In the brain the affection appears, microscopically, not to be marked by a primary fibrillary gliosis. Considering this plain fact, the nature and cause not only of cerebral multiple sclerosis but also of multiple sclerosis as a whole had to be envisaged from a new and different perspective.

Although Dawson noticed that also along the cerebral plaques' most prominent vessels the interstitial glia cells very early grew larger and proliferated vigorously, he emphasized that the fibrotic tissue transformation here only became evident after a distinct delay. He also discovered that, as Frommann had found in the spinal cord, firmly sclerosed zones in the brain tended to be preferentially perforated by large perivascular tissue defects. Entire branchings of lesion vessels coursed in wide, round perivascular hollows whose diameters, according to Dawson's illustrations, could reach a sevenfold width of the blood vessel they contained. But, especially regarding their tight and smooth circumvallation by densely compressed fiber layers, these yawning perivascular spaces stood in stark contrast to the vessel-related clefts or tissue lacerations entering the specifically affected cord sides.

As to the role of blood vessels in these lesion developments, Dawson's findings again underlined the fact that both the specific spinal patches and cerebral plaques first appeared near major vascular stems, and then advanced in the direction of the vascular periphery. But neither in the spinal cord nor the brain were the lesion vessels themselves ordinarily subject to more than rather protracted and not strictly lesion-related thickenings and degenerative scarrings of their walls.

Instead of demonstrating histological features peculiar to multiple sclerosis itself, Dawson's microscopical findings thus simply underscored the manifold, locally differing ways in which all the tissue constituents can become altered. Thereby, the histological manifestations of the cerebral plaques' and spinal patches' development were again found to differ in several important -- and yet widely neglected -- respects, i.e. especially in the local vascular, perivascular, and connective tissue changes.

(II-2) Histological Lesion Categorizations

The name of a disease may rightly be expected to tell something definite about its nature and cause(s). Having reconsidered the macro- and microscopical post mortem evidence which reflects most clearly the distinctive traits of the classic standard examples of spinal and cerebral multiple sclerosis, we are left with the task of clarifying why and how this condition has come to be categorized not in macropathological but in histological terms, although it was at first clearly specified by the aforementioned naked-eye findings, i.e. on the basis of macroscopically unique lesion patterns.

(II-2-a) From "Atrophy" and "Grey Degeneration" to "Multiple Sclerosis"

Carswell did not directly say that his "peculiar diseased state" was characterized by its distinctive mode of involvement of the spinal cord's flanks alone. But his reference to solely non-specific lesion properties -- by cataloguing the lesion simply as a kind of "atrophy" and describing it merely as consisting of a number of yellowish brown and semi-transparent, firmly consolidated areas -- also did not really constitute a specification of multiple sclerosis in histological terms.

In the same way, Cruveilhier, in his second, more detailed topical report describing the lesion's preferential involvement of the spinal cord's sides and posterior flank, did not point to this lesion pattern's singularity. Instead, he indiscriminately referred to both his specific findings and a further number of essentially different cerebrospinal lesions -- in fact, to all the damages which Plate II illustrates -- simply as "grey degenerations".

Only Charcot's first specimen of multiple sclerosis, embodied by a spinal cord whose two sides were taken in by two long, boat-shaped patches (in which demyelinated axons had been found), was presented as a specific observation of "sclerosis of the lateral columns of the spinal cord" (26). The affection of the spinal cord's sides by two symmetrical, inward-pointing, wedge-shaped scars was here, for the first time, defined as "sclerosis". And yet, although Charcot placed his case of lateral spinal cord sclerosis side by side with Carswell's and Cruveilhier's essentially identical observations, he also seems not to have been fully aware of the lesion pattern's specificity. He ultimately dubbed the condition rather ambiguously as "disseminated sclerosis in the form of circumscribed plaques", or "sclerosis in plaques" for short (26).

Ordenstein's 1867 thesis presented a specimen with clearly multiple sclerosis-specific lesions not only of the spinal cord (impressive sketches of its bilateral flank involvement are filed in Paris' Bibliothèque Charcot) but also of the brain. Here, for the first time, this condition was spoken of simply as a multilocular scarring or hardening, and the peculiar pathology was designated as "multilocular sclerosis" or "multiple sclerosis" for short, mainly to stress the concurrence of cerebral and spinal affections -- traceable by clinicians (26).

The shorter name variant "multiple sclerosis" has meanwhile found general acceptance -- also in referring to lesions affecting either brain or spinal cord alone.

(II-2-b) Multiple Sclerosis: Primarily a Fibrous Overgrowth?

From Carswell's and Cruveilhier's lesion descriptions it was obvious that, in the specific lateral spinal patches' domain, the tissue had become firmly fibrosed, -- the nervous tissue had become widely substituted by dense connective tissue structures. But neither report revealed anything peculiar to the fibrosis itself.

Charcot, who first referred to the specific spinal cord injury simply and specifically as "sclerosis", merely noted that the lesion's greyness and translucency appeared, under the microscope, to be due to an increase in fibrillary connective tissue occupying the nerve fibers' spaces, giving the impression that, on account of its growth, the still existent nerve fibers had directly been forced apart.

Frommann's microscopic studies first provided actual proof of a primary hypertrophy and hyperplasy of fibrous structures evolving in, and progressively extending from, the initially affected stretches of the spinal cord's flanks. The fibrosis was traced to a sprawling of fibrils within and out of particular, primarily strengthened stretches of the lesion domains' connective

tissue structures, and this fibril development even appeared to have advanced upon intact nerve fibers.

Beginning with Dawson, no single direct demonstration, but only three fragmentary documentations on the spinal cord's specific flank affection (35,135,92), can be traced — a trend coinciding with a luxuriant, still ongoing spread of ill-founded speculations on the essence and causation of (not only spinal) multiple sclerosis. Strasbourg psychiatrist M. Rosenfeld's bold statement that it was by no means clear what was actually peculiar to multiple sclerosis and that it had never been shown how multiple sclerosis was to be differentiated from scars of a different nature (115) was discreetly passed over in silence.

(II-2-c) Multiple Sclerosis – The Prototypal Demyelination?

Modern authors commonly refer to multiple sclerosis as a “demyelinating disease”, characterized above all by a random destruction of myelin sheaths around preserved axons (86, 154, 116). Multiple sclerosis has even been hailed as the archetype of all demyelinating diseases and as the standard of reference by which all other primary myelin diseases are to be evaluated (110).

In thus conceiving of the disease simply as a multilocular, randomly distributed myelin destruction [of unknown cause], it has even been stated about its lesions that “the plaques are commonest in the white matter, for it is here that myelin is present in greatest amounts” (85).

However, the question immediately arises: How can the multiple sclerosis-specific fibrosing wedges extending into the spinal cord's sides, and the compact plaques projecting off of the cerebral ventricles be reconciled with a lesion interpretation in terms of a systemic, randomly distributed myelin affection? To answer this question, the historical reasons for defining multiple sclerosis as a “demyelinating disease” must be detailed and explained.

Early Emphasis on the Significance of Demyelination

In 1868, Charcot presented a case in which brain and spinal cord specimens were said to have been affected by “multiple sclerosed plaques” - plaques which were thereafter microscopically specified through their lack of myelin (sheaths) or, more precisely, a “suffocating of the myelin [sheaths]” by connective tissue proliferations (27). Charcot's co-worker Bouchard, eager to characterize multiple sclerosis in more distinctive histological terms, particularly emphasized that, in the demyelinated plaque centers, the axons had remained conserved. For Bouchard this explained the lack of secondary (nerve tract) degenerations in multiple sclerosis (15, 16). Fascinated by these microscopic findings, both researchers revealed nothing about the lesions' additional properties, in particular their distribution patterns, and, in particular, whether they also corresponded to Carswell's “peculiar diseased state”.

A further paper of Charcot's, which is customarily quoted as having primarily determined the specifically demyelinating nature of multiple sclerosis, appeared half a year later (28). Forming

a record of Charcot's lecture on the subject of the condition's histology, its text was soon directly incorporated into Charcot's famous textbooks on neurology and so became part of the basic teachings on "multiple sclerosis" (29). Here Charcot made the abstract claim that a "permanent persistence of a certain number of axons amidst the most dense fibrillary tissue transformations constitutes a feature which appears peculiar to multiple sclerosis," which statement was later qualified by the remark that "it [the survival of demyelinated axons] is certainly not to be observed, at least to the same degree, in the other forms of grey degeneration" (29). This particular "exclusive demyelination" was not found to be distinguished by any other peculiarities — and the damage was said to be perfectly identical in appearance to the decay observed after the sectioning of a peripheral nervous trunk.

For Charcot the ultimate cause of multiple sclerosis was a "neoplastic" fibril formation. Relying heavily on his studies of Frommann, Charcot arrived at the conclusion that the observed fibrosis (in spinal multiple sclerosis) was "the initial and fundamental fact, the necessary antecedent of lesion development" (28,29). This fibrosis was supposedly set off by some "formative irritation" of the involved part's connective tissue fabric. The reasons for these postulates, however, were not made plain. Since they were not provably derived from precisely specified findings, Charcot's generalizations on multiple sclerosis thus appear hardly better founded than his and Bouchard's earlier lesion characterizations. In the end, Charcot had to admit: "It remains to be determined which histological characteristics distinguish it [multiple sclerosis] from other forms of sclerosis of the nerve centers." (28)

Although widely lauded as having established multiple sclerosis as the prototypical demyelinating disease, Charcot in fact provided no concrete evidence to prove that the causes of this particular kind of lesion actually lay in either some primary, or some specific, or at least some selective form of demyelination.

Establishment as a Myelin Affliction

The above-mentioned rather indefinite propositions apparently paved the ground for more decided articulations of the belief that multiple sclerosis merely constituted a primary cerebrospinal demyelination. It is revealing to trace how the breakthrough toward this new conception of multiple sclerosis was brought about.

Marie's Mission

The first researcher to directly postulate that multiple sclerosis was characterized by selective demyelination was the progressive, somewhat impetuous Parisian neurologist Pierre Marie. In his 1892 "Lectures on the Diseases of the Spinal Cord" (82) he explicitly declared that, while the myelin sheaths dwindled in the course of the disease, the axons in the lesions of multiple sclerosis were ordinarily left intact. Marie even asserted that any axon loss in a (multiple sclerosis-) specific lesion had to be regarded as purely incidental, a mere accident. His evidence on the subject consisted solely of a few crude drawings of some gross damages to brain and

spinal cord, evidence which, in its essence, corresponds neither to Carswell's "peculiar diseased state" nor to the specifically related cerebral damage first demonstrated by Charcot. Nonetheless, Marie's statement that selective myelin destruction "dominates, both in clinical and pathological respects, the entire history of this affection" (82) became accepted dogma.

Marburg Establishes Myelinolysis

In 1906, the Viennese neurologist Otto Marburg defined what he imagined multiple sclerosis to be directly in terms of a discontinuous (multifocal) myelin sheath destruction with initially absolute, and later relative, axon preservation (75). According to his established notion of these particularly acute kinds of "periaxial", i.e. peri-axonal, myelin losses, multiple sclerosis commonly began to be conceived of as a "myelin disease". The experimental evidence for his thesis resulted from applying a lipid-splitting enzyme to a frog's nerve, then observing the damages, which, according to Marburg, strikingly resembled those of multiple sclerosis. This led him to conclude that the process of multiple sclerosis revealed itself as a chemical lysis of the myelin sheath (75, 76). And this research into the cause of multiple sclerosis opened up a new, biochemical dimension.

Pette: Converting Multiple Sclerosis Into Multifocal Demyelination

The re-interpretation of multiple sclerosis as primary demyelination was promoted chiefly by the industrious and pragmatic neurologist Heinrich Pette of Hamburg, who first supported Marburg's multiple sclerosis conception by declaring that mere "discontinuous demyelination [myelin loss of separate segments of an axon's length] is so peculiar and unique an event as to justify the corresponding lesions' being set apart as a distinct group of the acute inflammatory diseases of the central nervous system" (98).

Pette autocratically dictated that every cerebrospinal lesion development was marked only in its final stages by fibrosis and sclerosis. Demyelination, in contrast, was the cardinal, most reliable identifying characteristic of multiple sclerosis. This multiple sclerosis had in fact just one unique and fundamental feature, demyelination. Entirely taken in by the conception of (primary) demyelination, Pette even wrote that the typical myelin involvement of multiple sclerosis had already been documented by Cruveilhier.

In high-handedly denying the existence of any form of primary sclerosis, Pette discarded as invalid the entire histological evidence, from Frommann up to Dawson, on instances of multiple sclerosis characterized by a primary fibrosis of the spinal cord's flanks. Pette even declared that findings of a massive sprawling of fibrous tissue excluded a diagnosis of multiple sclerosis (97, 98, 99, 100). Unacquainted with the post mortem observations by which multiple sclerosis had originally been specified, Pette in the end thus even denied the existence of any corresponding histological evidence.

Because it has never been substantiated by any concrete and specific specimens, it is no wonder that the concept of "demyelination" has always remained a dubious one: No single

qualitative or quantitative criterion for reliably identifying a "primarily demyelinating lesion" has ever been presented. Even quite recently this indefiniteness of lesion categorization was confirmed by the statement that, to figure in the illustrious class of the "demyelinating diseases", a pathological condition had to show demyelinations which were "predominant and not only prominent" (4).

(II-3) "Selective Demyelination": The Facts

A reconsideration of the original reasons for defining multiple sclerosis as "the prototypal demyelinating disease" shows that demyelination has never proved distinctive of any particular case or form of multiple sclerosis. Findings of demyelinated axons contributed, even less than the damaged areas' changes in color and consistency, to the identification of any multiple sclerosis-specific affection.

Because of their crucial importance, the prime histological features of the classical multiple sclerosis-specific observations will here be summarized. In the specifically involved parts of the spinal cord's flanks, a dwindling, or actual breakdown, of both axons and myelin sheaths takes place. Although preferentially the myelin sheaths tend to be injured -- some of the surviving axons appearing bared of part of their sheaths -- axons are more or less regularly lost as well. And axons, no less than myelin sheaths, are affected by swellings and various other changes, at times also in isolation (35, 50). In addition there are findings of myelin sheaths apparently simply squeezed out by their axons' ballooning (64).

According to Dawson's observations, the proportions between the numbers of affected axons and myelin sheaths must vary enormously, depending also on the lesion locations. In the gradually extending patches of the spinal cord's sides, the axons seem to persist more frequently, while a more intense axon breakdown appears to be typical of the posterior damages to the spinal cord. In the cerebral plaques, both myelin sheaths and axons tend to be evenly injured throughout.

These observations show clearly that a principle sparing or consistent intactness of the axons is by no means a feature of multiple sclerosis. The manifold changes affecting not only the involved myelin sheaths, but also all other sorts of local tissue, show that it is grossly oversimplified to picture the process of multiple sclerosis merely as a "peeling off of the axons' myelin sheaths". **The fact is that myelin sheaths in particular have never been shown to be altered in any way which might be considered multiple sclerosis-specific.**

(II-3-a) Primary Demyelinations: A Commonplace Phenomenon

In light of what has been said above, there is little sense at all in upholding conjectures about the causes of "multiple sclerosis-specific demyelination". However, light can be shed on the reason(s) for the tendency of myelin sheaths to primarily fall prey to the process of multiple sclerosis, if comparable kinds of injury patterns, not only of the myelin sheaths but also of the

other tissue elements – such as vessels, perivascular and other connective tissue structures -- are taken into consideration.

There has never been an objective evaluation, let alone a comprehensive survey of, any agents which might be capable of altering not only myelin sheaths and axons but also other cerebrospinal tissue elements in the way called attention to by Carswell's, Charcot's, Frommann's or Dawson's classical lesion characterizations. Instead, among the vast array of pathological conditions in which a prominent loss of myelin sheaths has been observed, the lesion damage of multiple sclerosis has, from the beginning, simply been compared to types of damage caused by blood-borne scatterings of tiny corpuscular agents or particles of inanimate matter.

The strikingly close analogies between the tissue changes of multiple sclerosis and those tissue changes resulting from diverse modes of plain mechanical trauma have gained remarkably little attention. Demyelinating brain lesions resulting from mechanical injuries have only in the past few decades been accordingly designated as "plaques simulatrices [of multiple sclerosis]", or as "false", "fool's" or "pseudo- [multiple sclerosis] plaques" (70, 72).

However, other comparable changes were already noted much earlier. Both in 1852 and 1855 Ludwig Türck observed that, where olfactory and optic nerves had been exposed to expansive processes, a glutting of fat globules, fat granules and fat granule cells indicated massive myelin decay, while the axons appeared rarefied in only one case of four (141, 143). In 1895 Bikes noted that spinal cord concussion tends to damage and destroy myelin sheaths much more extensively, much earlier and more severely than it does axons (12).

In 1916, contemporaneous with Dawson's account on multiple sclerosis, Aubrey Mussen reported on several indirect war missile injuries to the spinal cord, comprising damages fairly remote from bullet or shrapnel impact. The recurrence of gross axon distortions and swellings along individual nerve fibers was deemed to be the most remarkable finding. But observations of swelling, squeezing out – as in Lauenstein's 1877 account -- or breakdown of myelin sheaths and of damages to their fibrous encasements were noted as well. Debris appeared incorporated by "myeloclasts", amoeboid scavenger cells, and it even turned up in endothelial cells, i.e. in cells of the blood vessels' inner linings (88).

The injuries were found to extend typically along particular fibrous septa, i.e. sheets of connective tissue, inserting radially into the spinal cord's periphery. Along their course, and deeper within the cord's substance, preferentially where septa and vessels met, there occurred gaping tissue clefts – closely resembling those which Frommann had illustrated in 1867 (50). Here injuries had, as in multiple sclerosis, obviously spread primarily by way of prominent strands of the spinal cord's mechanical framework.

The most striking aspect of the traumatized areas, in the second week after injury, was not so much the emergence of vascular congestion and marked proliferations of interstitial cells, but a

very rarely observed phenomenon. Along altered stretches of the spinal cord's interstitial framework -- again mirroring Frommann's observations on spinal multiple sclerosis -- the following changes occurred: From previously ruptured or broadened stretches of the spinal cord's fibrous interstitial meshworks, there sprouted fine fibrils, which encroached upon the nerve fibers' circumferences. The latter tended to become replaced by a feltwork of sprawling, often interlaced fibrils, and the normal tissue structure was substituted by dense fibrillary scarring (88). On protruding intervertebral disks, circumscribed pressures of a minor degree were later observed to lead to a demyelination of the affected nervous tissue, just as already intimated by Türck in the 1850's. Here again, together with the demyelinations, marked, co-extensive proliferations of the fiber-forming interstitial tissue emerged, culminating in the formation of dense fibrillary feltworks (73).

Since then, axon demyelination has been studied in minute detail by exposing nervous tissues to localized mechanical impacts (37, 52, 59). It has been demonstrated that, for compression to cause a peripheral nerve's demyelination, the tissue must be warped fairly energetically (89). But as for spinal bulb and spinal cord, a repetitive swashing with minor quantities of cerebrospinal fluid sufficed to cause the exposed parts' surface demyelination (19, 83). Because of their nonspecificity, the occurrence in multiple sclerosis of comparable changes will not be discussed here.

Sharply circumscribed areas of demyelination contiguous with the outside of arterial bends, i.e. of the tissue primarily exposed to local pulsatile impacts, have also been found in cases of arterial hypertension (163). This "status prae-cribrosus" most likely evolves into smooth periarterial hollows, which occasionally riddle the brain's substance in the form of a "status cribrosus" -- in close resemblance to Dawson's perivenous hollows of cerebral multiple sclerosis.

Of all the mechanically caused direct primary demyelinations referred to above none has ever been shown to differ, in any essential histological detail, from the primary demyelinations in specific pathological instances of multiple sclerosis. Not only as to the diversity of the ways in which the different tissue elements are changed but also regarding their manners of spread, the microscopic findings of multiple sclerosis and slighter mechanical traumata parallel each other to a remarkable extent.

The Myelin Sheaths' Exceptional Mechanical Vulnerability

Neuropathologists have sometimes proposed that any edema, in fact any intense vascular seepage or leakage into some part of brain or spinal cord, whatever the causes, preferentially damages the myelin sheaths. One researcher even posited that there is no demyelination other than that attributable to perivascular edema (144). And yet the reasons for the particular vulnerability of myelin sheaths to such a "trivial" factor have scarcely ever been specifically addressed. This seems to be due to an insufficient awareness of the pathogenic implications of

the utter delicacy of the tissue bridges joining -- in the brain and spinal cord alone -- a number of myelin sheaths individually to one particular oligodendrocyte. Each of these bridges constitutes a bottleneck in its myelin sheath's supply line. The particular frailness of a myelin sheath's connection to its nutritive center, the oligodendrocyte cell body, and the vital role played by the connection in the sheath's evolution and preservation, were not taken note of until quite recently -- although the myelin sheath's individuality apart from the nerve cell's axonal extension was already detected at the time of Carswell's first documentations of multiple sclerosis.

It was only at the beginning of this century that oligodendrocytes began to be differentiated from the other central nervous interstitial cells (36, 88). And even after it had been shown, in the early sixties, that myelin sheaths are formed, and their losses substituted for, by oligodendrocytes (20), it was still thought possible that mature myelin sheaths might persist independently of oligodendrocytes (21).

Not until 1980 was it pointed out that the frailness of the tissue bridges between oligodendrocytes and myelin sheaths might directly account for the brain and spinal cord tissues' special proclivity towards primary demyelinations. The occurrence of pure demyelinations in any form of cerebrospinal edema was then explained by the fact that whenever particular oligodendrocytes and their myelin sheaths were abnormally driven apart, and their connections broken, the myelin sheaths would presumably decay (25).

Both in peracute spinal multiple sclerosis and as a result of recent mechanical injuries to nervous tissues, it was eventually noted that a myelin sheath can also be damaged by being squeezed out between a massively swelling axon and the particular nerve fiber's unyielding fibrous encasement (64, 88, 89).

(II-3-b) Reverberations of a Histological Misspecification:

Demyelinated axons were first described not in multiple sclerosis but in tabes dorsalis, a common complication of syphilis in the form of a specific degeneration of the spinal cord's posterior nerve tracts (65) (Plate II, fig. 3). It was accordingly pointed out quite early that multiple sclerosis could not be identified simply by findings of axon segments bared of their myelin sheaths (43). Nevertheless, the continued emphasis, by several neurological celebrities, on the condition's specifically demyelinating nature, sufficed to establish multiple sclerosis as the main representative of the presumed class of "demyelinating diseases".

Blurred Lesion Identity

Since the distinctive macropathology of multiple sclerosis had never been defined in adequate terms, circumscribing it in terms of a "grey degeneration" (34), then later as a "[multilocal] sclerosis" (26), and eventually as a "[primary] demyelination" (82) made it easy to subsume under each of these designations other not properly identified cerebral and spinal lesions which happened to exhibit comparable tissue changes. The different kinds of damages thus

designated by each of the given termini occasioned endless speculations as to the particular affection's cause. And the histological pseudo-specifications of multiple sclerosis spawned a number of other no less paradoxical disease conceptions.

Marburg's Sclerosing Inflammation

Otto Marburg's publications show what an extremely broad spectrum of essentially different pathological changes could become (mis-)identified as instances of "specifically demyelinating multiple sclerosis". Also presented as "sclerosing periaxial encephalomyelitis", i.e. as a scarring demyelinating cerebrospinal inflammation, Marburg's "multiple sclerosis" appeared simply as the main representative of a certain group of "non-purulent" conditions marked by "degenerative inflammatory foci, spread without any distinctive spatial distribution". The disease entity was said to be equally akin in nature to two radically different conditions: "[post-infectious] diffuse peri-axonal encephalomyelitis" and "[hereditary] diffuse cerebral sclerosis" (74, 77, 78, 79).

Ferraro's Even Less Discriminative Lesion Conception

In 1937, Armando Ferraro wrote that the pathological category of the "primary demyelinating central nervous affections" into which Carswell's "peculiar diseased state" had meanwhile become integrated could be differentiated only as to whether the individual processes possessed "patchy", or "diffuse", modes of spread. The results of his microscopical studies on correspondingly categorized cerebrospinal damages led Ferraro to formulate a virtually all-comprehensive multiple sclerosis conception, based on the following premises:

1. "No fundamental objections exist as to the unification [histological identification] of multiple [patchy] and diffuse sclerosis".
2. "[As to patchy sclerosis, there are] no...histopathological observations [which would permit us to] establish a distinction between multiple sclerosis and disseminated sclerosis".
3. "Knowledge of histology does not allow ... [us] to make a differential diagnosis in the various forms of demyelinating processes." (46)

Although Ferraro's observations simply testified to the non-specificity of his histological findings, his statements were commonly taken to mean that all the indicated forms of sclerosis were caused by the same, or at least closely related, disease processes.

Multiple Sclerosis: Macropathological Misrepresentations

More recently, the ways in which lesion patterns of multiple sclerosis have come to be illustrated stand in stark contrast to Carswell's and Charcot's real-life pictorial lesion specifications. As for the spinal cord, a 1939 schematic drawing by Wohlwill, republished by Hallervorden in 1955, appears to show that it is peculiar to multiple sclerosis to involve the

spinal cord not from its sides but in its antero-medial sector (53). And according to a 1969 sketch by Werner, the same condition is simply marked by a haphazard scattering of large, rather compact lesion foci into the interior of the spinal cord's white matter (157). As for the brain, on the other hand, an often reproduced 1930 illustration by Spatz evokes the impression that also cerebral multiple sclerosis is characterized by a random disposition of a number of lesion foci – apparently with a certain spatial concentration close to the outer angles of the lateral ventricles and immediately underneath the cerebral cortex (131).

A quick browse through the more recent literature on multiple sclerosis shows that the confusion still persists about what is actually multiple sclerosis-specific. Anybody who has access to depictions of lesions of “multiple sclerosis” on magnetic resonance imaging scans can pass his own judgments on this central point by comparing the MRI findings with the classic evidence concerning

1. the specific damages to the spinal cord (Plate I; Plate II, fig. 1, 1'; Plate III; Plate IV, figg. 3, 4; Plate V, figg. B, C, D; Plate VIII, fig. B; Plate IX, figg. A, B; Plate X), as well as
2. the specific damages to the brain-stem (Plate I; Plate II, figg. 1, 1'; Plate III; Plate IV, fig. 3; Plate V, figg. B, C, D), and
3. the specific damages to the cerebrum (Plate IV, fig. 1; Plate V, fig. A; Plate VI; Plate VII; Plate VIII, fig. A).

(II-3-c) The Root of All Evil: Demyelination

Since no really distinctive pathological traits have ever been posited for multiple sclerosis, the speculations as to the lesion's cause(s) have always been mainly conformable to the dominant research interests of their times. The currently established working hypotheses underlying multiple sclerosis research evolved in the following ways.

From Toxin to Virus

Marburg expected that multiple sclerosis would ultimately be explained as being a result of the spread of some myelin-dissolving toxin(s) (75,76,79).

The search for a demyelinating agent was then continued over several decades by Heinrich Pette, the main promoter of some fictitious "myelin aggressor". Assuming that the term "multiple sclerosis" stood for nothing but the randomly scattered foci of demyelination, Pette inferred the existence of a somewhat more compact agent possessing a similarly specific myelin affinity. Because of the lack of any evidence for such an agent, Pette at first proposed that, since it was obviously extremely small, it had to be some sort of virus (95, 96, 97).

Modern Dogma: "If not a viral agent, then an auto-immune process"

Since no proper evidence for a virus was forthcoming, Pette felt urged to postulate that multiple sclerosis could only be caused by some cell capable of launching a myelin-specific attack, the

kind of behavior which only definite strains of immunocytes could be imagined to be capable of. Thus multiple sclerosis came to be ascribed to an auto-allergy, i.e. an excessive auto-sensitizing towards particular constituent(s) of the myelin sheath (97, 101). The specifically patterned marks of Carswell's "remarkable spinal cord lesion", "Dawson's fingers" and "Steiner's splashes" thus were seen as the result of accordingly delimited tissue invasions by certain strain(s) of myelin-autoallergic immunocytes.

In this context it seems worth mentioning that Babinsky, in a 1885 paper, had already incriminated "lymphatic cells" as the cause of a certain variety of gross multifocal cerebrospinal damages, which he referred to as instances of multiple sclerosis. But in the same paper, he paradoxically also provided evidence on two facts militating against this assumption: He showed that (1) demyelinated axons are not peculiar to multiple sclerosis, and that (2) the "lymphatic cell" activities posited as causing multiple sclerosis also regularly evolved in the proximal stump of a sectioned peripheral nerve (6).

Remarkably, Prineas rationally re-established Babinsky's hypothesis in 1994, by conceiving of multiple sclerosis lesions as areas in which not only the myelin sheaths, but also their generative cells, the oligodendrocytes, were (auto-) immunologically affected (104, 106). This in spite of the fact that he himself had stated in 1985: "In the classical lesions of multiple sclerosis there is remarkably little cellular reaction, even during the acute phases of plaque development. It is upon this undisputed fact that the balance of opinion has always favored the view that the disease is a ... degenerative process" (103).

(II-3-d) Lymphocytic Infiltrations: Active, Or Re-active?

A sober analysis of Pette's writings reveals that, however eloquent and tenacious his teachings on the myelin-autoallergic nature of multiple sclerosis was, they were never founded on specific facts.

Immunocytes and "Myelophages": Rare, or Late to Appear

The basic facts: In the documentation on his first observation of a specific instance of multiple sclerosis, Charcot stressed the scarcity of "fat granules" in the damages to the spinal cord's sides -- which implied a negligible local prevalence of myelin debris-filled scavenger cells. In keeping with this, both Frommann's and Lauenstein's lateral cord lesions impressed observers by their lack of not only fat granule cells but also round cell infiltrates -- the latter finding implying that the lesion areas did not harbor a significant population of immunocytes. Dawson noticed fat granule cells, not in the spinal cord's lateral scars, but in posterior spinal and in cerebral lesions. However, even in the latter locations the fat granule cells appeared only to occur in more advanced stages of lesion development. Whenever perivascular infiltrations of small round cells, which might have been immunocytes, were found, they appeared slight and secondary to, i.e. provoked by, local accumulations of debris-laden fat granule cells. All this can be taken to show that no special local concentrations of immunocytes and myelophages, that is

of cells usually suspected of causing damage, are necessary for a multiple sclerosis-specific lesion's emergence. Accordingly, the affection of a lesion's myelin sheaths has often been observed to constitute not a dissolution or decomposition on the part of adjacent immunologically competent cells, but as a protracted dwindling or abrupt physical breakdown of entire sheaths, not seldom attended by the axon's fragmentation. The most reliable documentations on the specific lesions' histology thus clearly contradict the assumption of a primary autoimmune attack.

Autoimmunity: Not Solving Problems But Raising Questions

It is difficult to imagine how immunocytes, or also viruses or toxins, could become (and remain) localized, or how particular myelin constituents could be altered in such a way that the resulting damage might show the characteristic lesion pattern of a specific instance of multiple sclerosis. There is, accordingly, no indication of a primary existence of any conformable concentration-gradient, be it in particular agents or myelin compounds, between those areas which the process of multiple sclerosis specifically affects and those which it spares.

There is a long history of incriminating any scavenger cell found in the domain of a myelinated nerve fiber as an auto-aggressive grazer off of the particular sheath. However, an equally long history of contrary findings exists. Both Charcot, in the 1880 edition of his lectures, and Gledhill in 1973, demonstrated that, in compressive spinal cord lesions, a number of axons were encompassed by scavenging phagocytes instead of by their myelin sheaths (30, 52). Also in 1916, in concussive spinal cord lesions, direct invasions of myelin sheaths by myelophages ("myelin-eaters") were observed (88). Thus even massive local concentrations of myelophages glutted with sheaths-debris in, say, a multiple sclerosis-specific lesion, need not be causal to the injury.

"Perivenous cuffings", i.e. accumulations of immunocytes about venules, on the other hand, have been registered as a constant, normal finding in plain mechanical traumatization of the spinal cord (5). The so-called autoimmune, i.e. lymphocyte reactions in multiple sclerosis have never been shown to differ, either qualitatively or quantitatively, from those which naturally ensue from comparable tissue destructions of mechanical or vascular origin (60, 73, 153, 164).

In fact there are many immunological observations which aptly show that the immune reactions of multiple sclerosis are nothing more than secondary reactions to some preceding injury. But in none of these observations was the necessity of demonstrating the presence of specific lesions ever taken into account (except for possibly one magnetic resonance imaging study which indicated that any pertinent immune activation strictly followed, instead of preceded, the lesions' eruptions (90)). For obvious reasons, this immunological evidence will not be further discussed.

It may thus be concluded that, in genuine multiple sclerosis, neither immunocyte nor scavenger cell activities have ever been shown

1. to qualitatively differ from those in comparable brain and spinal cord lesions such as, in particular, purely vascular and mechanical cerebrospinal damages;
2. to exceed in severity what normally follows comparable damages; and,
3. to actually precede the specific destructions.

The interesting question arises as to why there has been so little explicit resistance to the explanations of the multiple sclerosis-specific pathological changes in terms of the work of particular strain(s) of auto-allergic immunocytes.

(II-3-e) Primary Inflammation: Adding to the Confusion

The still fashionable interpretation of multiple sclerosis as an "inflammatory process" has further hindered the recognition of multiple sclerosis-specific pathological findings. The term "inflammation", taken by itself, simply refers to the highly complex, either passively consequential or reactive changes which tend to evolve in the wake of any kind of tissue damage, excepting extremely delayed structural degenerations.

But the expression "inflammatory damage" has also come to imply damages apparently attributable to the process of inflammation itself or, in more recent times, to some immunological event forming part of it. The interpretation of multiple sclerosis as a kind of "inflammatory injury" has accordingly mainly been wielded against the lesion's original understanding as an essentially degenerative or sclerosing pathological process (87, 75, 95, 96, 97). Being such an extremely complex and multi-faceted process, "inflammation" has proved to be a magical black box suited for conjuring up ever new explanations for the indicated conditions.

In this connection, the inflammatory processes' ways of dissemination are still up for discussion. The important question of whether circulating agents would even be capable of producing part or all of the multiple sclerosis-specific lesion formations will find its answer in the fourth chapter of this book.

(II-3-f) Histology: Not the Key to Understanding Multiple Sclerosis

The categorizations of multiple sclerosis according to its tissue changes, culminating in the condition's re-specification as primary demyelination, have not contributed towards clarifying the nature of this condition. Conceiving of multiple sclerosis in non-specific histological terms has instead put research at the mercy of momentarily prevailing medical interest or fads. Instead of clearly differentiating which features of the condition are truly distinctive and evaluating their meaning, investigations into the disease's cause have, up to the present day, predominantly proceeded on pure speculations whose impacts have simply depended, to a considerable degree, on the respective proponents' professional authority and leverage. It is no wonder that all conventional attempts at elucidating the lesion's cause have not succeeded. The

goal of the following chapters is to point the way out of the blind alley which multiple sclerosis research is presently proceeding down.

(III) The Neurologist's Standpoint

"What a man would like to be true, that he more readily believes."

Francis Bacon, 1620

Not so long ago, it was posited:

"The 'gold standard' for the diagnosis of MS is the clinical history and findings at physical examination" (51).

This bold statement, like current disease definitions, has its roots in the belief that multiple sclerosis is to be identified simply by the forms of its nervous dysfunctions or the periods of time in which they manifest themselves.

Conceiving of multiple sclerosis as a clinical disease entity implies that there are criteria by which anybody with a sound background in neurology would be capable of incontestably diagnosing it -- merely by exploring the causal injury's functional repercussions. In other words: Every victim of the disease ought to show signs or symptoms which are, as to their nature or course, proper to multiple sclerosis, and which occur nowhere else.

Clinical criteria have been widely adopted as the ultimate standards for identifying multiple sclerosis. However, one critical question has never been addressed: Is it possible for functional neurological data to replace the post mortem findings containing evidence of a distinct form of injury?

As long as multiple sclerosis is considered to be a distinct form of injury, any clinical evidence for its presence should be derived from the condition's genuine specification. Before proposing a clinically distinct form of multiple sclerosis it needs to be clarified if the multiple sclerosis-specific lesion patterns in fact translate into equally distinctive neurological phenomena.

In this context, we must remember that the more properties required for a particular condition's identification, the more its specification has not been improved but worsened with superfluous expansion. Making changes in nomenclature -- redefining or reclassifying the specific pathology of Carswell's "peculiar diseased state" - which Charcot renamed as "multiple sclerosis" -- will not improve on the genuine lesion characterization.

It is of paramount importance to evaluate the soundness of the conception of clinical multiple sclerosis, to show how reliable the condition's identification by means of the patient's clinical history and neurological findings ultimately is. To settle this point, we will (1) re-evaluate the clinical accounts on the most reliably identified instances of multiple sclerosis, to check the diagnostic impact of the particular disease manifestations; and (2) reconsider how the diverse attempts at defining multiple sclerosis on the basis of neurological evidence have long been (erroneously) justified.

(III-1) Classical Clinical Observations

In commenting on the neurology of his "peculiar diseased state", whose lesion illustration provided the earliest unequivocal specification of multiple sclerosis, Carswell freely stated, "I could not ascertain that there was anything in the character of the paralysis or the history of the cases calculated to throw any light on the nature of the lesion" (24).

Cruveilhier, 1841: First Clinical Account of Multiple Sclerosis

Nothing is known concerning the clinical history of Cruveilhier's first specimen of multiple sclerosis, pictured in 1839, and only in his second case report were neurological data given in some detail.

A year and a half before the patient's death, the affection had first made itself felt with creeping or prickling sensations beginning in the soles of her feet and rising up to the calves. Soon afterwards, a trembling of the arms and a clumsiness of the hands supervened, so that grasped objects often slipped from the patient's hand.

Half a year later fitful incapacitations of the upper limbs forced the woman to give up her job as a chambermaid. In the three months before her death, she was further handicapped by stumbling, dragging of the legs, and occasional collapses of the knees. The left and then also right hands could no longer be relied upon.

During the last two weeks of her life, the patient lost almost all sense of feeling in both legs, although feeling in the arms was less impaired. The arms, more than the legs, especially on the right side, could still only be moved awkwardly.

The patient's suffering during her last ten days was aggravated by a feeling of constriction around her waist, urinary retention and complicating infections of the lungs and left shoulder. The patient died, aged thirty-eight, of suffocation (34).

Conclusion: There is no evidence of any distinctive neurological features of the disease. As against Carswell's "peculiar diseased state", however, this condition culminated not in a plain paralysis but in an almost complete loss of sensation in the lower, rather than upper, limbs, and in disturbed motor control. This last finding might be attributed to the presence of damages not only to the spinal cord's sides but also to its back.

Clinical Manifestation of Charcot's Specific Lateral Cord Lesion

Charcot's neurological observations on his earliest case of multiple sclerosis describe the capricious development of a progressively severe central nervous affection lasting between the patient's fourteenth year and her death at sixty.

For the first six years of its forty-six year course, the disease manifested itself with recurring feelings of strangulation, followed at monthly intervals by convulsive attacks with loss of consciousness, lasting for up to three hours. The attacks were generally preceded, for two or three days, by "girdling" pains around the lower chest and, in the beginning, also by giddiness,

heart flutterings and choking. The episodes during her twenties were limited to feelings of strangulation, shortly preceding and then persisting during menses.

The first actual neurological phenomena were observed in the woman's thirty-fifth year. Having experienced, for a few days, crawling sensations and a feeling of numbness in her left shoulder, she suddenly noticed a cramping of her left arm and leg and then lost consciousness. She was awakened by a painful contracture of the left half of her body, including the neck, which slowly subsided only after two weeks. The left arm, however, never regained its former mobility.

One year later the woman again suffered a severe nervous attack. This became a generalized tremor and weakening which gradually worsened so that, after a month, the patient could no longer leave her bed. There followed painful contractures of, at first the limbs on the left and, after three weeks, also on the right side, including body and neck.

The condition worsened for more than a year and to such a degree that the patient could no longer make use of her limbs. In addition, she suffered from a continuous feeling of strangulation and a hypesthesia extending over the (already severely cramped) left arm and leg, back and chest. All of these symptoms lasted for two years.

At the age of forty-seven the patient's condition gradually improved, over three months, to such an extent that, despite an enduring weakness of her lower limbs and a certain degree of cramping of the upper limbs, she could even walk and keep house.

At the age of fifty the woman awoke from a last fit of unconsciousness, with contractures of all four limbs. She then remained bedridden and became fully incontinent and incapacitated by a cramped fixation of her limbs, finally succumbing to an erysipelas, a skin infection spreading from her left leg over her trunk to most of her back. Up to the end her thinking, speech, and facial expressions seemed unimpaired, and she also retained a certain motility of the head and neck (26).

The significance of this observation: Charcot categorized the condition in three different ways:

1. as an instance of unequivocal hysterical attacks;
2. as a case of multiple sclerosis directly corresponding to Carswell's and Cruveilhier's classic pictorial lesion specifications (the Bibliothèque Charcot at Paris has crude sketches of Charcot's which impressively document this analogy); and
3. from 1874 onwards, as the first standard example of amyotrophic lateral sclerosis, a primary motor neuron disease whose existence was postulated by Charcot himself. This last categorization was made
 - a. although Charcot's own description of a boat-shaped scarring of the spinal cord's flanks clearly contradicted the idea of a corresponding lateral spinal tract degeneration;

- b. despite the fact that no amyotrophy, i.e. dwindling of the muscles, had been observed in the patient's lower extremities; and
- c. although Charcot had noted diverse massive sensory deprivations on the patient's part (26,29).

Neurological Data on Frommann's Observations

Frommann's classic histological account on a case of spinal multiple sclerosis was complemented by a clinical history put down by Leyden (65): The patient's disease probably first became manifest fifteen and a half years before death when, especially while carrying heavy loads, he suffered from intense twinges in his back.

One day, about two and a half years later, the patient suddenly collapsed, feeling that his right leg had been "punched through". He then noticed that he could not bend his right knee, nor was there any feeling in his right side. For about six months he was unable to walk, and thereafter continued dragging his right leg. The initial bladder incontinence turned into urinary retention. Moreover, the patient soon complained of racking pains of unspecified localization, and later about pains in the left leg, as well as numbness in the lower back. During the following ten years both legs became increasingly paralysed so that, in the end, he was only capable of changing his position supported by two crutches, and dragging his legs. The patient further perceived, from time to time, a creeping sensation in the lower limbs and eventually also a frequent trembling of his right arm. In his last week of life the man was unable to move or feel his legs, except for slight perceptions in his knees. His right arm was now weakened as well. The patient died, 42 years old, of a sepsis ensuing eight days after being scalded in an overheated bath – which the patient could not feel, owing to a loss of sensation in the lower half of his body (50).

Conclusion: In comparison to Charcot's previous observations (26), Frommann's patient, despite an apparently more extensive spinal cord involvement, was subject to far less severe and extensive nervous incapacitations. In both cases, moreover, it is futile to attempt to trace any direct correlations between functional clinical and gross morphological post-mortem findings, as a comparison of the findings' laterality makes evident. Nothing in the character of this disease can be considered indicative of the underlying lesion specificity.

Charcot's Prime Clinical Example of Cerebrospinal Multiple Sclerosis

By the age of twenty-five, this patient had already suffered much from headaches, as well as frequent cramps in her lower limbs. Neurological troubles arose the following year, in the form of a weakening of the legs more than the arms, particularly on the left side. The legs also felt numb and cold. Three years later, her vision became dimmed, and perceived objects seemed to sway and turn. After another three year period, recurrent girdling pains set in and, at the same time, the patient lost her ability to walk, which she regained in the following year, though only for a month.

About a year and a half before her death, both legs became immotile, apart from slight toe movements on the right foot. The arms, especially the left one, were considerably weakened. In addition, a mainly left-sided impairment of sight, a severe nystagmus, i.e. spontaneous oscillation of the eyes, a trembling on exertion, pains around the trunk, and alternations of urinary retention and incontinence supervened.

Nearly one year previous to death, the patient suffered from painful leg spasms for about one month. After another month the woman's legs, particularly her right one, could again be brought into different positions, despite their spasticity, and also the distortion of her handwriting diminished. Bladder control was shortly regained.

During the last months of her life, all exertions of hands, neck, or body provoked a trembling of the respective parts. Both legs, especially the right one, went into spastic extension, leaving only a weak, one-sided, residual motility of foot and toes. The one arm achieved only poorly coordinated movements. The patient herself looked apathic and dull. Two months after having slightly recovered for the last time Charcot's patient succumbed, at the age of thirty-six, to a vast decubital ulcer (93).

Conclusion: In referring primarily to the progressive weakening and eventual contracture of the patient's four limbs, Charcot was particularly interested in the trembling of the arms during exertion. Yet his classical observation of cerebral and spinal multiple sclerosis presented no data which actually defined the disease in clinical terms, nor did it offer any clues as to its specific macropathology.

Lauenstein's Myelitis

In this case, a man suddenly began to feel exhausted, giddy, and so stiff that he could hardly climb stairs, and this all during a work pause, thirteen days before his death. Subsequently he began suffering from an obstinate constipation and increasing upper back pains, radiating especially towards the nape of the neck.

Ten days later he was admitted to the hospital. The following day, all of a sudden, costal breathing, limb motility, as well as sensation from the toes up to the third rib and in the arms, except the arms' proximal inner side, suddenly ceased. A total urinary retention and fluctuating body temperatures set in.

During his last two days, the man could neither expectorate to alleviate breathing difficulties, nor was his speech any longer comprehensible. During the last night before death from suffocation, pains in the back and nape of the neck further intensified. Lauenstein's patient died, forty-six years old, of a relentlessly worsening breathing insufficiency (64).

Conclusion: This patient's history demonstrates that multiple sclerosis can lead to death even during the first attack. However, neither the symptoms and signs themselves, nor the course of the disease, can be considered as indicative of a specific injurious process.

Clinical History of Dawson's Standard of Comparison

Both a clinical history and the entire pathology of one particular instance of multiple sclerosis were comprehensively detailed side by side for the last time, by Dawson in 1916. His report deserves particular attention.

Two years and three months before her death, a woman one morning found her legs swollen and tender. Pains shot down her right leg, and she had great trouble in getting out of bed. Returning to work a fortnight later, she no longer felt able to walk as quickly as before, her right knee having become stiff.

Sixteen months later, the woman was forced to give up her job, mainly owing to a progressive stiffening of both legs, unpredictable bouts of arm trembling and periods of incontinence. Her speech had slowed down, and she had difficulties in pronouncing words.

All of these symptoms gradually worsened. On admission to the hospital a slight nystagmus, a minor right-sided mal-coordination in the finger-nose test, and leg reflexes pointing to a bilateral damaging of the cerebrospinal tracts were noted. During her first seven weeks in hospital, five months before death, the patient made one last hopeful recovery.

At intervals of a few days, in the fourth month before death, the following symptoms were recorded: a numbness in the right arm, followed by near-complete deafness with a dull buzzing sound in the right ear, right-sided facial paralysis preventing the closing of the eye and, finally, double vision to the right, protrusion of the tongue to the left, and difficulties in speech and swallowing.

A distinctly progressive weakening and spasticity of the legs, severe vomiting, a dimming of vision which gradually turned into complete blindness, a rapid wasting away of the muscles of especially the legs, diarrhea, and urinary retention were observed in the month preceding death. In spite of short periods with slight improvements, in the end the woman passed away rapidly, aged twenty-eight, with a distinctly septicemic appearance.

Conclusion: For all of its thoroughly registered complexity, the history of Dawson's exceptionally well documented case of multiple sclerosis again did not provide neurological observations proving the condition's clinical peculiarity, nor did it provide for reliable in vivo identification of comparable illnesses.

Reflections on Classical Clinical Observations

As to nature and course, all of the nervous troubles by which the pathologically specific instances of multiple sclerosis became clinically manifest proved utterly variable, paralleling one another merely in non-distinctive respects. A comparison of the preceding accounts on multiple sclerosis also discloses remarkable inconsistencies among clinical and pathological findings. Thus the specific spinal cord involvement is most extensive in Frommann's case, followed by Charcot's and then Lauenstein's. With regard to the nervous afflictions, however,

Lauenstein's patient appears most and Frommann's least severely affected. The extent of the nervous tissue involvement traced at post mortem therefore by no means correlates with the severity of the nervous deficits registered in vivo. With respect to the clinical data on Frommann's total cross-sectional scarring of the thoracic spinal cord and Lauenstein's narrowly localized lateral cord destructions, it must be assumed that completely but very slowly demyelinated areas can remain more or less functional, while peracute functional nerve tract interruptions need not be autoptically traceable.

We must also be aware of the fact that no neurological screening can achieve the "spatial resolution" which would be necessary for a reliable in vivo identification of the distinctive lesion patterns of either spinal or cerebral multiple sclerosis: A particular neurological dysfunction in principle simply indicates that the corresponding nerve tract has been affected somewhere. As a consequence, in involvements of longer functional pathways, it can sometimes not even be determined whether the trouble is cerebral or spinal in origin. But in spatially indiscriminate, lump-sum assessments a neurological dysfunction can never be expected to disclose exact position(s), number(s) and length(s) to which a definite nervous pathway has been affected.

It should not be surprising, therefore, that no individual multiple sclerosis patient has ever been observed to show clinical phenomena betraying the specific nature of the underlying post-mortem findings: There is simply no possibility of identifying the distinctive patterns of spinal or cerebral multiple sclerosis by evaluating a patient's clinical history, as well as physical and, in particular, neurological findings.

In clinical medicine, as in any other natural science, any criterion adduced for some condition's specific qualification must be shown to be both consistent, i.e. to occur in each and every patient suffering from the given disease, and exclusive, i.e. never to occur in a patient affected by a condition of different nature. For lack of any evidence that multiple sclerosis is characterized by distinctive neurological features, it is important to find out how it has come to be defined primarily in clinical terms, and why it is understood as a disease identifiable by the nature or course of its symptoms.

(III-2) CDMS: Chronically Delusiv Misidentification Syndrome

The ways in which the highly cherished idea of a "clinically definite multiple sclerosis" evolved have as yet never been subjected to a sober logical analysis and critique. In order to properly evaluate this type of disease conception we need to find its origins and to delve into the maelstrom of diagnostic speculations which have established multiple sclerosis as a neurological entity, without any connection whatsoever to the specific post mortem evidence referred to by the same name.

(III-2-a) The First Clinical Cases

Friedrich Theodor Frerichs, professor of "pathology and therapy" in Breslau, is commonly credited with having made the first in vivo diagnosis of multiple sclerosis. The principles which guided Frerichs are of considerable interest. As it turned out, he entrusted the publication of his diagnostic results to a young pupil of his, Wilhelm Valentiner, and it is the latter's work which will gain our attention here. In order to fully understand and judge Valentiner's lines of reasoning, it is indispensable to first acquaint ourselves with Frerichs' concept of "cerebral sclerosis".

Frerichs' (Cryptic) Cerebral Sclerosis

In 1848 Frerichs, at the University of Göttingen, undertook a classification of the solidifications of brain substance: He differentiated between consolidations of the brain as a whole, attributable to consumptive processes and aging, and localized cerebral hardenings, produced by neoplasms, tuberculosis and exudative inflammations. This was some time before the actual nature of the last three pathological processes really became understood.

Urging that the changes in the consistency of cerebral tissue be clearly discriminated as to their causes, Frerichs went on to compile data on "the unexplained form" of brain sclerosis. It was said to be sharply circumscribed, to usually start in the white matter above the lateral ventricles, and to have a texture somehow differing from that of pathologic growths and scars of chronic inflammations, as well as from that of general cerebral consolidations in advanced age, and in systemic diseases.

This cryptic sort of cerebral sclerosis was exemplified by four specimens which, in retrospect, can be said to have shown lesions of three essentially different kinds. Frerichs' second and third examples represented, to all appearances, malignant gliomas of the cerebrum (butterfly type) and brain stem (infiltrative form) respectively. The fourth specimen, secured from a victim of tuberculosis, had been adduced by Cruveilhier as illustrating grey degeneration (Plate II, fig. 4).

The first specimen, which stemmed from a boy who died of incessant convulsions at the age of six, had been observed by Frerichs himself. The epileptic fits had started with nodding spasms in the child's sixth month and had continually grown worse. Frerichs' drawing and description of the boy's brain showed a massive, overall Y-shaped scar involving cerebral cortex and subjacent white matter, conformable to the vascular territory of the two terminal branches of the middle cerebral artery (69).

While its origins remained undetermined, Frerichs' brain sclerosis presented the following physical features:

1. An unusually textured, scarred appearance of part(s) of the brain.
2. A lack of any specific parallel to Carswell's "peculiar diseased state".

First Clinical Diagnosis of Cerebrospinal Sclerosis

In 1856 Frerichs' student, Wilhelm Valentiner, presented a series of papers entitled "On the Sclerosis of Brain and Spinal Cord" (147). These expositions began with a detailed history of the nervous illness for which the first in vivo diagnosis of Frerichs' cryptic sclerosis had been made: Tactile and motor functions had failed first on the left and soon also on the right side of a patient suffering from muscular twitchings and pains. The subsequent excessive fluctuations in the patient's moods were eventually superseded by stuporous indifference. Special attention was paid to the severe trembling interfering with all of the patient's voluntary activities, including speech.

This symptomatology already sufficed to convince Frerichs of the actual presence of his pathological entity, "cryptic cerebral sclerosis". Frerichs' long-winded, confusing clinical argumentations as to why any other form of pathological process could be excluded from this case will not be recapitulated here.

Valentiner also detailed this patient's later troubles: Unsteadiness of the eyes, a fitfully aggravated paresis, increasing tremors, episodes of urinary retention, varying pains in head and neck, and a mental decline, until death ensued from an intestinal infection, two and a half years after the onset of the disease.

At post mortem, the circumference of the brain stem as well as basal and inner parts of the cerebrum proved invaded by sclerosed areas. If properly illustrated and explained, Valentiner's findings of a dense scarring of outer wall and roof of the lateral ventricles, forming the basis of a radiation of both sclerosed and softened lesion-expansions into the cerebral hemispheres, might have anticipated and complemented Charcot's and Dawson's specifications of cerebral multiple sclerosis. The affection of the spinal cord remained undescribed, but it is quite obvious that, while supposedly of the same cryptic origin, Valentiner's case of cerebrospinal sclerosis and Frerichs' diverse instances of brain sclerosis did not show any distinctive morphological features in common.

In an attempt to clinically characterize (cryptic) cerebrospinal sclerosis, Valentiner additionally evaluated the case histories of one personally observed and nine reported instances of unexplained cerebral, bulbar and spinal sclerosis. There were three clear instances of continuous degeneration of the posterior columns of the spinal cord (Plate II, fig. 3); one observation of genuine multiple sclerosis (Plate II, figg. 1, 1'); and seven rather vaguely characterized pathological conditions. Each and every case of this highly heterogeneous mix-up of different neuropathological observations was deemed useful for determining the clinical picture of Frerichs' cerebrospinal sclerosis.

Clinical criteria derived from, and supposedly indicating, all of these equally enigmatic, but otherwise scarcely comparable disease processes obviously had to be very broad. And, like the histological feature of "sclerosis", so also all clinical and neurological phenomena appearing

common to the diverse pathological processes subsumed under Frerichs' and Valentiner's notion of cerebrospinal sclerosis merely constituted non-specific findings.

Valentiner seems to have sensed some of these inconsistencies. He asked for the reader's forbearance in case conclusions arrived at in the course of his studies might not be diagnostically valid. He also voiced some concern about his own indiscriminate inclusion, in his clinical study on cerebrospinal sclerosis, of instances of a systematic degeneration of the posterior columns of the spinal cord. All the substantial differences between the various specimens of Frerichs' and Valentiner's cerebrospinal sclerosis appeared negligible when considering the fact that Cruveilhier himself had depicted the particular lesions side by side, labeling them with the same term.

Valentiner's diagnostic criteria or hints about how to identify future cases of cerebrospinal sclerosis will be cited insofar as they, or their modifications, came to form part of later clinical definitions of multiple sclerosis. Such criteria were:

1. Relentless progression, yet interrupted by frequent remissions;
2. Occurrence of all possible kinds of nervous incapacitations;
3. Earlier and more severe involvement of the lower as against the upper limbs;
4. Affection of motor functions in general more than sensory ones; and
5. Primarily non-consumptive character of the illness (147).

There can be no denying the fact that Valentiner's criteria for the clinical diagnosis of the cryptic form of cerebrospinal sclerosis were not derived from a study of patients suffering from one and the same disease. But no criticisms of the flaws of Valentiner's expositions seem ever to have surfaced. Instead, his paper became an integral part of the standard literature on the subject of multiple sclerosis.

Ordenstein's Prototypal Clinical Reports

When multiple sclerosis was diagnosed *in vivo* for the first time, the decisive findings were not proudly announced, but expressed in a rather roundabout way.

Introducing multiple sclerosis as a distinct form of cerebrospinal lesion, Ordenstein at first declared as absurd the search for a direct parallel between the given pathological findings and some neurological disease specification. Notwithstanding this explicit caveat, in his review of the literature on the subject of multiple sclerosis he cited Valentiner's paper prominently. And, in thus repeating Valentiner's mistake, Ordenstein once more indiscriminately presented the case histories relating to several profoundly differing forms of Cruveilhier's "grey degeneration" (cf. Plate II, figg. 2-4) as the earliest clinical evidence on multiple sclerosis.

Before beginning his long, drawn-out account on the symptomatology of multiple sclerosis, Ordenstein attempted to give a definition of the condition's anatomical pathology. He maintained that multiple sclerosis was characterized by an asymmetrical dissemination of lesion nuclei or wedges at the most varied places of the spinal cord and brain – areas of grey degeneration appearing everywhere. This lesion definition of multiple sclerosis was similar to that in a paper presented by Vulpian in 1866, which Ordenstein's thesis hailed as the standard French work on this pathology. Vulpian had posited that multiple sclerosis was specified by an orderless spread of one or more plaques into brain and/or spinal cord (152).

Ordenstein's exposition reached its climax in statements concerning the disease's clinical traits. The main message was that the manifestations of multiple sclerosis in the living appeared explicit enough to permit the condition's reliable (clinical) identification. The following symptoms were considered diagnostic:

1. Motoric disturbances, primarily of the legs;
2. A progressive advancement, with occasional remissions;
3. A pathognomonic trembling, emerging during physical efforts and ceasing during periods of rest;
4. Nystagmus, i.e. spontaneous oscillations of the eyes; and
5. Scanning speech, i.e. monotonous drawling utterances.

Despite his initial admonition that there could be no clinical diagnosis of an anatomically defined condition, Ordenstein later stated his belief in the reliability of these diagnostic criteria, even affirming the presence of multiple sclerosis in two *in vivo* cases. His presentations of two "clinically identified instances" made multiple sclerosis appear as an authentic clinical entity (93), and these two putative *in vivo* diagnoses were later "legitimized" by confirming the presence of multiple sclerosis at post mortem.

At least in one case, the description of a predominance of large plaques in the ventricular walls actually was reminiscent of the lesion arrangement of cerebral multiple sclerosis (17). In principle, however, Ordenstein's (and his teacher and supervisor Charcot's) *in vivo* specification of multiple sclerosis harbored the same fundamental flaws as Valentiner and Frerichs' clinical characterization of cerebrospinal sclerosis: Ordenstein's attempts at defining more precise criteria for the disease's *in vivo* diagnosis were founded simply on a more extended co-evaluation of causally enigmatic instances of a (frequent but only postulated) cerebrospinal grey degeneration or multilocular scarring process -- many instances of which were merely concretized by the mysterious epithet "unpublished observation".

All this, together with Ordenstein's adoption of Vulpian's utterly vague lesion specification, betray the fact that Ordenstein's newly established "clinically diagnosed multiple sclerosis" and

Carswell's, respectively Charcot's, pictorially specified multiple sclerosis, though bearing the same name, were certainly not the same entities.

Charcot: Multiple Sclerosis – A Kind of Lesion, Yet Clinically Defined

The seventh of Charcot's famous lectures dealing with the clinical diagnosis of multiple sclerosis was introduced with the statement: "Nothing is simpler ... than to diagnose the affection in question at the bedside of the patient" (29, 31). Not fully agreeing with Ordenstein's thesis, Charcot posited the following criteria for differentiating multiple sclerosis from similar illnesses:

1. An absence of sensory disorders in general and, in particular, the absence of girdling pains, i.e. pains around the waist.
 - As to this point, the clinical observations in both of Charcot's, in the second of Cruveilhier's, in Frommann's, Lauenstein's and Dawson's specific instances offer a large body of conflicting evidence.
2. Intentional tremor, i.e. trembling only under exertion, increasing in direct proportion to the extent of the movements executed. As opposed to Ordenstein's thesis, this symptom was now considered not to be pathognomonic, even inconstant or present only in late stages of the disease.
 - Remarkably, episodes of trembling or shaking of the limbs were made mention of in most of the histories of specific instances of multiple sclerosis, but Charcot and Ordenstein alone described this trembling as characteristic of multiple sclerosis.
3. Remissions to an extent not found in other chronic diseases of the spinal cord. This was, however, immediately conceded to be an unreliable criterion.
 - In this respect, also the degree beyond which a remission had to go to indicate multiple sclerosis was anything but clear.
4. Paresis of the lower limbs, a symptom which should have put physicians on the right track! Charcot admitted, nevertheless, that corresponding observations were common to a large number of different diseases.
 - Whether this criterion be fulfilled depends not on the injurious agent's nature but on whether it affects the pathways of the leg's motoric innervation.
5. "Trembling of the extremities, impeded articulation, giddiness, unsteadiness of the eyes, etc. ... symptoms belonging to multilocular sclerosis alone". Of all these troubles none was yet considered a constant feature of the disease.

- This bold assertion apparently resulted in the establishment of "Charcot's diagnostic triad" (omitting the giddiness) or Charcot's four clinical marks of multiple sclerosis. But it applied originally to a comparison of multiple sclerosis with "progressive locomotor ataxia", a clinical syndrome typically associated with sclerosis of the spinal cord's posterior nerve tracts (29, 31).

All in all, Charcot's contributions to the subject of multiple sclerosis thus prove highly contradictory. With his superb drawings on specific spinal and cerebral findings (Plates IV, V) and his precise and comprehensive early documentation on spinal multiple sclerosis (26), he provided clear evidence of the unique pathological features of multiple sclerosis. In addition, he often stressed that the condition was to be defined by its pathological anatomy alone. And yet, his statement that nothing is simpler than to diagnose the disease at the patient's bedside, and his role in the propagation of the first supposedly diagnostic clinical multiple sclerosis syndrome appears widely responsible for the fact that multiple sclerosis has come to be considered primarily as a clinical disease entity. Charcot has rightly been praised, but unfortunately for the wrong achievements.

(III-2-b) Mutations of the Multiple Sclerosis Syndrome

However ill-founded, Charcot's "diagnostic triad", was enthusiastically greeted. Not only were its handy criteria for diagnosing multiple sclerosis in the living patient everywhere uncritically embraced, but famed neurological scholars began to cast about for other methods of identifying the mysterious condition in vivo. The ensuing conceptual odyssey led mainstream research far away from evaluating the multiple sclerosis-specific post mortem evidence, establishing instead a blunt clinical neurological understanding of the disease.

Wilson's Audacious Attack

In 1876, Edward T. Wilson recommended replacing the term "disseminated insular sclerosis", used as a synonym for multiple sclerosis, with the expression "rhythmic or oscillating ataxia", referring to the disease's allegedly diagnostic tremor. Wilson obviously held that the condition was distinguishable rather by its symptoms than by any other abnormality. Unfortunately there seems to have been no reaction to his doubts about multiple sclerosis-specific post mortem findings (161).

Wernicke's Ambivalent Stance

Carl Wernicke (1883) behaved inconsistently: While questioning the value of Charcot's diagnostic criteria and decrying as futile any attempt at defining multiple sclerosis by its neurological manifestations, he himself worked out yet another clinical definition of the disease. The essential features of multiple sclerosis, according to Wernicke, were

1. the overall relentless progression;
2. the apparent sparing of the organism as a whole;

3. the involvement of the nervous system in at least two sites;
4. cerebral symptoms "revealing the nature of the disease by themselves" (158).

Rather Controversial: Balint

Rudolph Balint's reasoning was no less contradictory. In an 1899 article, he defined multiple sclerosis as a clinical syndrome, to be identified by its "four characteristic symptoms" – an understanding traceable to Charcot -- and then exemplified the affection in the following case-report:

A woman's nervous illness had arisen in four episodes, each provoked by an otherwise uncomplicated parturition. The first episode was marked by weakness of the left leg, the next of the right hand, the third of both legs, and the fourth of all limbs. Finally, the patient became incontinent, her legs insensitive to pain, and, after the emergence of left-sided facial paresis, she succumbed to pneumonia.

Of Charcot's four clinical multiple sclerosis criteria, none had been noted here. And the post mortem was ultimately said to have disclosed the well-known lesion development and image of multiple sclerosis. After first characterizing multiple sclerosis as a clinical syndrome, Balint had thus ultimately proceeded to identify the condition on the basis of its (unfortunately not specified) macropathology (7).

Borst's Counteroffensive with Blanks

In his 1903 survey of the literature on multiple sclerosis, Max Borst emphasized that, without post mortem evidence, it could never be certain whether a nervous disorder was actually multiple sclerosis or not (13). However, he again did not tell which findings would verify the presence of the disease. And, instead of conforming to the archetypes, his instances of multiple sclerosis proved to be a mixture of different imprecisely characterized and not properly understood cerebrospinal lesions. Borst's multiple sclerosis, although allegedly identified at post mortem, also failed to form a distinct anatomical pathological entity.

(III-2-c) Framing of New Clinical Criteria

Researchers around the turn of the 20th century must have had the impression that neither the in vivo presentation nor the pathology of multiple sclerosis exhibited any truly specific traits. Leading neurologists accordingly felt increasingly called upon to search for more practical ways of identifying the condition. And so, step by step, the conception of a "clinically definite multiple sclerosis" began to emerge.

Marburg's More Accommodating Criteria

In 1906, Otto Marburg frankly conceded that multiple sclerosis could become manifest in nervous disorders of any sort and in any concatenation, no neurological symptom being actually peculiar to it. He therefore suggested substituting the still prevailing "diagnostic triad of

Charcot" (co-occurrence, in a particular case, of intentional tremor, scanning speech and nystagmus) by neurological criteria which rather complied with the boundless varieties of the disease's in vivo manifestations. He arrived at the following four clinical diagnostic criteria of his own:

1. Neurological indications of a multilocular cerebrospinal involvement;
2. At first insidious, then galloping disease progress -- in certain cases, interrupted by repeated recoveries;
3. No indications of an affection involving the organism as a whole; this implied, in particular, an absence of fever -- even of neurogenic fever (while Charcot had regarded the latter as a characteristic of peracute multiple sclerosis attacks (29, 31)).
4. As regards his criteria's specificity, Marburg simply cautioned that also arteriosclerotic lesions could manifest themselves in the specified ways (75).

Multiple Sclerosis Defined by "Multiplicity"

A multiple sclerosis specification which excelled in its simplicity and, moreover, could be applied not only to the affection's clinical presentation but also its organic pathology was presented by C. P. Symonds in 1924. The twin definition was to exert a pervasive and enduring impact on the understanding of the condition. With respect to the diagnosis of multiple sclerosis, Symonds posited: "In clinical practice, the best criterion [for diagnosing] disseminated [= multiple] sclerosis is [neurological evidence for] dissemination of the [not always accountable] lesions both in space, within the central nervous system, and in time." Symonds concluded: "The disease is characterized ... anatomically by the coexistence [at] post mortem of multiple [non-specified] foci in various stages of degeneration" (138).

Pette: Diagnosis by Exclusion and Fulminance of Attacks

Heinrich Pette was the first researcher to freely admit that multiple sclerosis might be clinically diagnosed simply by the exclusion of other nervous diseases (i.e. definite pathological processes known to be capable of causing the observed affections) (100). He emphasized that there were no neurological phenomena peculiar to multiple sclerosis and warned -- as had often been done before and would often be done after him -- that the disease frequently manifested itself with a mask of clinical pictures considered typical of totally different (meaning medically understood) nervous affections. Pette said that the clinical picture of multiple sclerosis appeared primarily characterized by

1. a fulminant onset, and
2. exceptionally speedy fluctuations in its development.

But in both respects multiple sclerosis and plain arteriosclerotic or hypertensive cerebrospinal affections were conceded to often be indistinguishable from one another. Pette thought that, in

the presence of corresponding affections, it was justifiable to diagnose multiple sclerosis if there was no evidence for risk factors of arterial cerebrovascular affections (100).

Pette placed a heavy reliance on the exclusive procedure of "diagnosing" multiple sclerosis in vivo. Like Marie (82), yet in bold contradiction to any clinical history relating to the specific post mortem observations, he further claimed that multiple sclerosis could spontaneously and fully heal after one single attack. In the end, Pette's argumentation led to the absurd conclusion that any residual defect or history of any cerebrospinal affection(s) of unknown cause could be considered as evidence for the former presence of multiple sclerosis (95, 97, 100).

Need for Definitive "Bedside" Diagnoses

After these and several other quite unconvincing assertions by a number of leading neurologists on identifying multiple sclerosis in the living, the ground appeared well prepared for some official ruling regarding the circumstances under which multiple sclerosis was to be diagnosed. The impulse which proved decisive for laying down standardized criteria for the disease's clinical neurological "identification", however, originated not in any conceptual endeavors but rather in an interest to obtain statistically comparable patient populations for performing pharmaceutical therapeutic trials.

Schumacher's "Diagnostic Time Schedules"

In 1965 a crucial step towards achieving the rationally impossible was taken by a team of ten neurologists, headed by George A. Schumacher. For the diagnosis "clinically definite multiple sclerosis" they defined six criteria which, by integrating the most fundamental suppositions of the preceding clinical multiple sclerosis definitions, gained general acceptance and official approval. With a view to establishing anatomical pathological specifications, simply one confirming (+) and one excluding criterion (-) were defined:

(+) "There must be evidence of involvement of two or more separate parts of the central nervous system"

(-) "Simultaneous and symmetric involvement of the lateral and posterior columns of the spinal cord [alone] ... cannot be interpreted as caused by multiple sclerosis" (125).

Concerning the first point, we may ask ourselves whether a counting of unexplained lesions can actually make up for a qualitative lesion specification. This manner of thinking challenges us to ask: Does the finding of a second set of multiple sclerosis-specific "Dawson's fingers" truly enhance the first finding's specificity? Or can the cause of some cryptogenic nervous dysfunction be revealed by its being followed by another no less cryptogenic nervous dysfunction?

The assertion that multiple sclerosis cannot be diagnosed when the spinal cord's sides and back appear symmetrically affected is particularly strange: It excludes as instances of multiple sclerosis exactly all those observations corresponding specifically to Carswell's "peculiar

diseased state", i.e. all the classic specimens of spinal multiple sclerosis. The attempt at defining multiple sclerosis in clinical terms thus culminated in an exclusion of in vivo evidence for exactly that lesion pattern by which the disease had first been genuinely identified and consistently specified (cf. Plates I to V, IX and X; cf. Charcot, 1865)(24,34,93,31,26).

However, regarding the disease's temporal evolution, Schumacher's diagnostic criteria were remarkably strict. As to the efforts devoted to their precise definition, multiple sclerosis might have been taken to reveal its nature mainly by the periods and spans of time within which it made itself felt. A reliable diagnosis of multiple sclerosis thus required:

The individual cryptic cerebrospinal dysfunctions to have evolved either

1. "... in two or more episodes, separated by a period of one month or more, each episode lasting at least 24 hours", or
2. "... in a slow or step-wise progression ... over a period of at least six months" (125).

The two time schedules might further have been understood to define two distinct types of disease development, had they not admittedly been arbitrarily chosen. They were in fact devised to lessen the risk of a misdiagnosis of multiple sclerosis in central nervous affections of "essentially different" (i.e. principally known, but at times not traceable) causes, such as in lesions of some "vascular" or "inflammatory" origin.

Little was said about these criteria's reliability, for disease developments which comply with the stipulated time schedules occur not only in multiple sclerosis. Simply two unverified arterial or venous occlusions of some untraced origin are thus, if their clinical manifestations are correspondingly timed, already liable to lead to a mistaken "clinically definite diagnosis of multiple sclerosis".

The responsibility for making a diagnosis of multiple sclerosis was in the end shrewdly shuffled off onto the diagnosing physician: It is he who has to ensure, with all the expertise at his command, that "... the patient's signs and symptoms cannot be explained better [i.e. actually explained] by some other [i.e. known, or even more precariously, curable] disease process" (125).

The Disenchanted Truth

The current understanding of multiple sclerosis, including its interpretation as a demyelinating inflammatory process, and its explanation as a primary autoimmune disease, apparently relies on the conception of clinically identified multiple sclerosis.

However, the evidence in support of also this last notion is extremely meagre, definitions having never been borne out by specific observations. The condition's true identity has continued to elude researchers completely.

The meretricious nature of the "clinically definite multiple sclerosis" conception is especially revealed by the following:

- In anatomical-pathological respects, clinically defined multiple sclerosis has, from the start, always reflected a conglomerate of unexplained, and otherwise thoroughly different, pathological conditions.
- Currently established disease definitions imply that the cause of unexplained neurological dysfunctions (in case such recur) can be directly derived from the times during which the dysfunctions are manifest.
- The existence of untraced thrombotic or embolic, hypo- or hypertensive, toxic or metabolic, infectious or allergic, as well as of other, more complex and evasive central nervous affections is virtually denied.
- The conception of clinically defined multiple sclerosis is ultimately based on the logical fallacy of deriving a positive conclusion from blaringly negative premises.
- Instead of speaking of clinically definite multiple sclerosis, it would be more adequate to speak of cases of unexplained neurological troubles in which the clinicians' respectively neurologists' diagnostic repertoire has been exhausted.

As is also highlighted by the lack of any solid identifying features or exemplary case histories, the establishment of the notion of "clinically definite multiple sclerosis" cannot be understood as anything but a soothing stratagem. To make progress in the understanding of the conditions which are at present subsumed under the term "multiple sclerosis", those features must be focused upon which in fact prove peculiar to the specific instances of the disease. Hollow, ultimately speculative diagnostic assertions carrying along in their wake endless series of therapeutic experiments only delay the sound evaluation and explanation, as well as potential cure, of the addressed conditions.

(IV) The Specter of the Multiple Sclerosis Agent

“How often misused words generate misleading thoughts.”

Herbert Spencer, 1879

The investigations into the cause of multiple sclerosis conventionally proceed on a number of stereotyped assumptions which have not been carefully enough thought through. Based on unexplained neurological findings pointing simply to a concurrence or succession of lesion developments at different sites, the current attempts at elucidating the lesion cause start from the following conclusions: There has to be (1) a corpuscular agent which (2) attacks the lesion sites via the ordinary blood and fluid circulation, and which (3) does so on account of a special affinity for the myelin sheath.

These three assumptions, based on the complementary notion of random lesion spread and the explain-all conception of primary inflammation, have opened up an infinite field of multiple sclerosis research — all leading nowhere. Nonetheless, it is of no little historical interest to find out how these speculative assumptions turned into a dogma domineering multiple sclerosis research.

The peculiar multiple sclerosis lesions first testified to by Carswell (spinal cord) and Charcot (cerebral hemispheres and corpus callosum) were obviously characterized neither by random lesion spread nor by primary inflammation. And the critical issue of what causes their specific manner of spread has remained unaddressed.

(IV-1) Lawless or Specific Pattern(s) of Spread?

Multiple sclerosis is usually supposed to be the result of some agent's chance scattering via the brain's and spinal cord's vascular supply lines. But the question of how the specific cerebral “Dawson's-fingers” and flank lesions of the cord actually arise, consistently expand, and even — according to serial magnetic resonance brain images — continually re-emerge has never been properly addressed. The physical events underlying the specific lesions' development thus need to be thoroughly reconsidered.

An insufficient arterial perfusion has only rarely been suggested as the cause of multiple sclerosis, as ischemic lesions are known to conspicuously conform to the involved arteries' zones of irrigation. In fact, beginning with Carswell's pioneering observations (23, 24) (cf. Plate XIII) and continuing right up to the present, more and more evidence has accrued to show that, although often occurring in similar sizes, outlines, and numbers, the ischemic lesions show an overall configuration which differs radically from the spread pattern of both Carswell's “remarkable spinal cord lesion” and Dawson's periventricular lesion projections.

Putnam asserted that multiple sclerosis plaques were due to vein thrombosis. Two peculiar findings were supposed to support this idea: the emergence, in a living dog's brain, of

demyelinated plaques along affluent veins of a cerebral venous sinus which had been clogged by a countercurrent injection of inert lard oil (107); and the presence, in a victim of multiple sclerosis, of a thrombus obstructing a vein draining a number of well-defined cerebral plaques (Plate VII) (108, 109). But Putnam's inference was rendered implausible by the fact that a cerebral venous obstruction typically becomes manifest by one diffuse zone of edema dotted with hemorrhages, which had already been demonstrated by Cruveilhier (34).

There apparently remained only one segment of the cerebral and spinal vascular trees from which multiple sclerosis could, and had to, originate: The tiny vascular ramifications forming the transitions from arteries to veins. In fact, of the entire vascular bed, these minute blood vessels represent that segment which has the largest total surface, is the most slowly perfused, and proves the most permeable – thus constituting a blood-borne agent's easiest way of escape into the substance of brain and spinal cord.

Current hypotheses about the causes of multiple sclerosis proceed on the common assumption that its lesions, however long or large, are simply the result of a coalescence of sufficient numbers of such small vessel involvements. The question thus arises: Can massed transitional vessel involvements really combine to form the different multiple sclerosis-specific lesion patterns?

In this chapter it will be shown how the archetypal depictions and descriptions of multiple sclerosis, i.e. both Carswell's "remarkable spinal cord lesion" and "Dawson's fingers", came to be integrated into the protean class of conditions caused by multifocal small vessel involvements.

(IV-1-a) Multiple Sclerosis by Blood-Borne Dissemination?

Also referred to as "disseminated sclerosis" and understood as an unexplained form of multifocal "(post-) inflammatory scarring", multiple sclerosis is conventionally attributed to some minute cryptic agent's systemic scattering. But on looking at the lesion illustrations on Plates I and IV, it is hard to believe that the massive plaque projections off of the lateral cerebral ventricles or the slender patches extending over considerable lengths of the spinal cord's flanks could be caused by the spread of blood-borne agents.

Taking on the role of *advocatus diaboli*, we ought to be able to prove that a blood-borne agent can actually be spread in such a way as to produce the specific lesion patterns of multiple sclerosis. We must explain how the necessary clusters of separate (micro-) vascular units can become simultaneously involved, why these aggregates' consistently become enlarged out in definite directions, and how new lesions emerge in the brain again and again.

To attempt to settle these points we will shortly focus upon the characteristics of those lesions which were observed to result from a definite blood-borne agents' systemic spread. We will clarify just why minute agents cannot be distributed in a manner which produces typical

multiple sclerosis-specific lesion patterns. Finally, special attention will be paid to the peculiarities of those instances of "disseminated encephalomyelitis" which continue, up to the present day, to be likened to and confused with specific observations of multiple sclerosis.

Character of Disseminated Myelitis

Especially before the medical community had begun to become acquainted with infectious microbes and diverse mechanisms by which so-called "spontaneously arising" spinal cord lesions can be brought about, the term "myelitis" - inflammation of the spinal cord - was used to designate damages of the most varied kinds. It was not until well into the second half of the nineteenth century that decisive attempts to illustrate the origins of disseminated myelitis in different blood-borne agents' systemic spread were made.

In 1874 the multifocal spread pattern of two inflammatory spinal cord affections due to a local scattering of blood-borne agents was precisely defined in drawings by the Berlin specialist for nervous diseases, Carl F. O. Westphal. He depicted numerous spinal cord cross-sections obtained in both a case of smallpox and one of "phtisis pulmonum" (pulmonary tuberculosis) (159). The extremely varied patterns of inflammatory foci spread, obvious already from comparing closely neighboring cross-sections of one cord, so surprised Westphal that he decided that this form of pathology had to be characterized by "an absolutely irregular scattering of spot-shaped foci over most of the spinal cord". He further observed that this spinal cord affection had emerged in strict dependence upon tiny blood vessels (159).

Westphal's illustrations gave evidence of a certain predominance of radial lesion extensions in the cord periphery, many forming offshoots of central grey matter damages, fanning out and tapering off outwardly, or terminating abruptly, within the surrounding white matter.

Plate XII renders the pictorial characterization of the inflammatory cord lesions of a small-pox victim, made in 1913 by the Zurich pathologist Hermann Eichhorst. Eichhorst emphasized the following observations: The very numerous inflammatory foci -- a dozen of them discernible on a single cord cross-section -- were generally of poppy-seed size. Their numbers and distribution patterns varied extremely -- even on neighboring cord cross-sections the patterns of spread were rarely comparable. Based on his microscopic findings, Eichhorst was led to conclude that the specific pathological changes consistently originated in a primary affection of the tiny vessel coursing amidst each of the lesions (41).

In a victim of measles, Friedrich Wohlwill of Hamburg observed inflammatory foci, virtually free of cell infiltrates, dispersed over the entire spinal cord, each evolving and extending into a close relationship to a small venule (162). Regarding the present-day opinions about multiple sclerosis this observation is of double significance: The abstract pathological notion of multiple sclerosis has, on the one hand, become closely associated with the idea of a perivenular lesion; on the other hand, the entity is supposed to be caused by certain strains of immunocytes (which, in Wohlwill's case, were conspicuous by their absence).

Spinal Multiple Sclerosis: Simply Cryptogenic Disseminated Myelitis?

In 1928 Pette presented a number of illustrations depicting what he felt sure was a special kind of spinal cord lesion (96). However, in contrast to Carswell's much earlier observations of a "remarkable spinal cord lesion" Pette's cord findings were marked by the following peculiarities:

1. A radiating out of lesion cones and streaks from the spinal cord's central grey matter (cf. Plate XII) -- a feature particularly evident in the second cord lesion.
2. A lesion circumvallation by closely packed interstitial cells, forming a fairly smooth contour line, occasionally (in larger lesions) appearing distorted by irregular crenations and tattered appendices (this point is highlighted in the first and third instances).
3. A lack of any lengthy involvement of the spinal cord's sides or back by inward-directed lesion wedges.
4. No evidence of lesion extensions following the spinal cord's fibrous septa, or of correspondingly advancing lesion fringes.

What Pette had presented were in fact three definite cases of disseminated myelitis, all having one particular characteristic in common: their causal agent had not been identified. In keeping with this, Pette consistently adhered to the opinion that multiple sclerosis was simply a multifocal central nervous inflammation, identified primarily by the lack of evidence for a definite cause (95,96,97,98,99).

Apparently unaware of any truly multiple sclerosis-specific findings, Pette strove hard and quite successfully towards convincing the medical community to embrace his conception of multiple sclerosis. It seems not to have been realized that what came thus to be spoken of was disease without a clearly defined identity.

Character of Disseminated Encephalitis

Up until the end of the nineteenth century the term "encephalitis" also appeared rather ill-defined, comprising different kinds of "inflammatory" brain lesions, many of which were ascribed to primary or idiopathic, i.e. essentially cryptogenic, inflammations. This situation began to change at the beginning of the twentieth century.

The preferential emergence of the foci of encephalitis from tiny blood vessels of the brain's subcortical white matter was expertly illustrated in 1907. In the two lithographs of Plate XIII Hermann Oppenheim and Richard Cassirer clearly demonstrated that also in the brain inflammatory foci typically spread from tiny blood vessels.

Even when appearing spread throughout the cerebral white matter, including the lateral ventricular angle and corpus callosum (62, 68, 130, 132), such multifocal cerebral inflammations never resembled the image of "Dawson's fingers".

Cryptic Disseminated Encephalitis Versus Cerebral Multiple Sclerosis

Pette's first example of "multiple sclerosis" also showed stray inflammatory lesions in the brain, lying directly underneath the temporal cortex. In his third case mention was made of findings of actual periventricular damages - but these appeared to have evolved - not as "Dawson's fingers" do - away from, but in the direction of the lateral cerebral ventricles (96). Pette's cryptogenic multifocal inflammatory "multiple sclerosis" thus also did not exhibit any multiple sclerosis-specific features in the brain.

Other researchers made considerable efforts toward providing a clearer distinction of cerebral multiple sclerosis plaques, but they were unable to discriminate them from large, homogenous and well-circumscribed inflammatory plaques, such as those found in chickenpox (133, 148). But even more extensive cirrocumulus-like sheets of multifocal inflammatory changes found in the brain of victims of measles appeared to present no problems for differential diagnosis (155). In all these attempts at characterizing cerebral multiple sclerosis, the observations on the truly unique features of "Dawson's fingers" were never taken into account.

Postvaccinal "Multiple Sclerosis"

In the second half of the twentieth century even observations of disseminated encephalomyelitis, attributed to a definite, albeit not fully understood cause, namely a series of vaccinations or supposedly therapeutic inoculations came to be referred to as instances of multiple sclerosis.

The first of two much-quoted papers attempting to explain multiple sclerosis in terms of a "demyelinating" encephalomyelitis of neuroallergic origin (the case histories indicating rabies vaccinations as causes) was presented by I. Uchimura and H. Shiraki at Tokyo University in 1957 (145). Large agglomerates of merged inflammatory foci adjoining the outer angle of the lateral cerebral ventricles were illustrated in their first, second, third, and seventh specimens, and in four of the five remaining specimens comparable damages were said to have embraced the occipital and temporal ventricular horns. While appearing, as to their location, comparable to "Dawson's fingers", the lesions yet showed tattered, partly blurred edges, manifold internal inhomogeneities, and small attendant foci spread at random over the entire brain. The cord lesions' conformity to the foci and striae of disseminated myelitis was even more blatantly evident (145). It is unclear why the two researchers specified these observations as instances of multiple sclerosis.

A more detailed account on corresponding pathological changes was presented in the following year by Franz Seitelberger at Vienna (126). The brain of a man who had died of unexplained neurological troubles after receiving several inoculations of calf brain extracts after a diagnosis of multiple sclerosis showed, especially in its central white matter, a diffuse edema and engorged blood vessels. The white matter was beset by small inflammatory foci, varying from pinhead to rice-grain size. The changes, all of which appeared to be of the same age, were

related to a generalized vascular engorgement and effusion. The two major lesions capping the ventricular angle seemed to have evolved in the direction of the lateral ventricular angle and originated in a fusion of small inflammatory foci; their margins proved "moth-eaten" and presented many unevenly structured and bizarrely crenated lesion-tongues. The spinal cord lesions lined the anterior fissure or marked the course of deeper blood vessels (126). Categorizing this encephalomyelitis as a specific instance of multiple sclerosis is out of the question.

Unexplained Encephalomyelitis Is Not Specific Multiple Sclerosis

Clinically defined multiple sclerosis has come to be specified by subsuming, under one and the same (dysfunctional) term, all sorts of structural pathologies. Curiously, ever since the disease and its causes has been officially defined using trivial, enigmatic or ill-understood observations of multifocal cerebral and spinal inflammations. Identifying commonplace findings by offering unexplainables as proof apparently seems quite acceptable when dealing with multiple sclerosis.

And yet, the truth must out. There are only two forms of multiple sclerosis which are really specific and unique: That of the spinal cord, showing the peculiar flank lesions first documented by Carswell (24) and ultimately implied by Oppenheimer (92); and that of the brain, depicted as "Dawson's fingers" (and similarly, "Steiner's splashes") - defined pictorially first by Charcot (31) and later, rather abstractly, by Adams (1).

(IV-1-b) Inflammatory Versus Specific Plaques

A comparison of Carswell's and Charcot's pictorially specified examples of multiple sclerosis with "multiple sclerosis-like" cases of disseminated encephalomyelitis shows that there is no single specific parallel of either the spinal or the cerebral multifocal inflammations to the truly distinctive observations of multiple sclerosis. It is important to find out why these two radically different lesion forms are confused even today, and to suggest how such confusions might be avoided in future.

One significant factor is clear: Inflammatory affections may, in diverse non-specific respects, so-to-speak mimic multiple sclerosis-specific damages, though both conditions can definitely be differentiated. Having realized this, another false premise once and for all proves false - the multiple sclerosis-specific pathology can no longer be ascribed to a cryptic blood-borne agent's circulatory spread.

Large Idiopathic Plaques: Not Proof of Multiple Sclerosis

Both blood circulation and cerebrospinal fluid shifts (engendered by the brain's arterial pulsations, and often more so by fleeting expansions of the veins of definite cerebral or spinal drainage systems) present the most efficient means for any microscopic agent to be distributed swiftly and extensively throughout the entire craniovertebral space. In the blood stream any

virus or immunocyte may quickly be carried to any surface point of the vascular bed and, after entering into the cerebrospinal fluid, to any point of the brain and spinal cord's inner and outer surfaces. Among all of these possibilities of "docking" on tissues only those equally easily accessible will actually be affected "at random". Cerebrospinal tissues then may appear evenly strewn over with inflammatory foci or perivenular sleeves of less than a millimeter's breadth. The question is, in which ways such tiny dots and streaks can become metamorphosed into large (pseudo-)plaques.

Inflammatory lesions, attributable to one and the same blood-borne agent, may exhibit widely differing patterns of spread. It is easy to conceive of the efficacy of some "inflammatory" occlusion of a smaller artery or vein. Also, it is not difficult to imagine that some agent's release in dense wisps, its primary deposition (or secondary settling around a previously affected site) in varying clusters may result in protean lesion formations. Thus very different forms of even larger inflammatory lesions may evolve, and their intermittent growth may be due to contiguous depositions of comparable damages. If the tissue between thick-set foci is swamped by edema, foci clusters may turn into large, more or less homogenous and rather smoothly contoured lesions resembling, at least superficially, an isolated specific plaque of multiple sclerosis. Streaky perivascular inflammations may merge into larger lesions more easily where their tracks converge, i.e. around the spinal cord's central grey matter and at the lateral cerebral ventricle's outer angle. In the spinal cord, corresponding lesion patterns were already illustrated by Westphal in 1874 (159), while at the lateral ventricles' outer angle they appear to have been observed only by Seitelberger (126) and Uchimura (145).

The fact is that in the brain, even more so than in the spinal cord, to properly differentiate specific multiple sclerosis lesions from similarly configurated inflammatory damages not only the lesion positions, as they present themselves on single pathological slices, need to be taken into account. In order to reliably identify, for example, a "Steiner's-splash" or a "Dawson's finger" as against a large, confluence of inflammatory foci or streaks localized at and beyond the lateral ventricular angle, it is necessary to consider not only the lesion's overall configuration, but also its inner organization and, above all, the kind of vascular or tissue structure(s) from which it has originated, as well as the overall direction(s) of lesion spread.

Viruses: Incapable of Causing Specific Multiple Sclerosis Lesions

Any virus, as a minute immotile particle, depends entirely on the flow of body fluids to reach distant structures which it has a special affinity to. The richer the local blood supply and the ampler the local effusion of fluid towards adequate substrata, the greater the chances viruses have to settle at a definite site.

As to how viruses might be capable of selectively colonizing cerebrospinal tissues in patterns peculiar to spinal and cerebral multiple sclerosis, no explanation has ever been offered. Neither any property of a virus itself nor any ordinary or inflammatory fluid dynamics can conceivably

induce a viral lesion to spread in a multiple sclerosis-specific way. The patterns in which viruses are scattered and the patterns in which Carswell's "remarkable spinal lesion" and the cerebral "Dawson's fingers" evolve in no wise parallel each other – they are in fact fundamentally different.

Myelin Autoaggression: An Inapposite Postulate

Owing to their ongoing circulation in great numbers throughout the body, the distribution of immunocytes (lymphocytes, plasmocytes) on brain and spinal cord might a priori be expected to be fairly even. Whereas many extrinsic infectious agents may leave the vascular bed simply of their own accord or through tiny vascular leaks, the immunocytes' evasion from blood vessels is conditional on intricate mechanisms: Immunocytes will only come sufficiently close and adhere to the inside of a blood vessel if and when the local blood flow has been abnormally slowed down. For immunocytes actually to attach to a blood vessel's inner lining, it must have acquired a specific "stickiness", conditional on the presence of compounds to which a strain of immunocytes specifically reacts.

Even if these requirements were to be fulfilled, the immunocytes' tissue invasion would further depend on the speed of the local fluid exudation and the presence in the tissue of higher concentrations of definite compounds which steer, chemotactically, the reactive immunocyte's own extremely sluggish advance. Under these circumstances, white blood cells, such as immunocytes, have been observed to invade affected tissues first through thin-walled venules and then, possibly, also capillaries, but only exceptionally through other vascular branches (32, 139).

Regarding the ranges of the perivascular inflammatory streaks' extension, it is further important to be aware of the fact that, following any physical or other insult severe enough to provoke an inflammatory reaction, the point of transition between fluid-filtrating and fluid-absorbing blood vessels regularly shifts, for a variable distance, from postcapillary transitional vessels towards smaller and larger venules, possibly even to small veins (33).

In bluntly attributing multiple sclerosis to a cryptogenic autoimmune process, the following questions have never been answered:

1. What limits the immunocytes' vascular attachments exclusively to certain sharply punched out cerebral or frayed out spinal lesion domains?
2. What motivates and enables immunocytes to locally penetrate not only the vessel walls but also the close patchwork of astroglial "feet" encasing the brain and spinal cord's proper tissue elements?
3. What -- and this appears to be the decisive point -- prevents the immunocytes from exerting any injurious effects outside of the specifically patterned lesion domains?

The idea that the specific lesion patterns of multiple sclerosis are brought about by certain autosensitized strain(s) of immunocytes is thus at least as much out of place as the assumption of a conformable scattering of particular viruses. Both the kind of structures from which the distinctive changes emerge and the specific orientation and limitation of their growth principally contradict the assumption that multiple sclerosis – understood as a specific form of injury -- is caused by an agent carried about by blood circulation and interstitial fluid flow (139).

(IV-1-c) Injurious Inflammation: The Cart Before The Horse

In referring (with Charcot) to the specific spinal and cerebral multiple sclerosis observations as "disseminated sclerosis", the epithet "disseminated" can certainly not be understood as indicating some agent's spread via the organism's fluid circulation. And the notion of "inflammation" cannot soundly explain the specific changes. Not only is there no evidence for any inflammatory or immunological phenomena peculiar to multiple sclerosis. Quite to the contrary: Whenever properly identified instances of multiple sclerosis are spoken of, all inflammatory phenomena are either observed to be secondary in nature (as in the brain), or found not worth mentioning, or totally absent (as in the spinal cord's sides).

Precisely those lesion traits at variance with multiple sclerosis, on the one hand, and multifocal central nervous inflammations, on the other, are most revealing about the causes of specific multiple sclerosis lesions. Therefore, to arrive at a proper understanding of the condition, the basic misconceptions about the pathogenesis of multiple sclerosis need to be subjected to a clarifying critique.

Spinal Multiple Sclerosis – Not an Essentially Vascular Lesion

The multiple sclerosis-specific spinal patches' most characteristic feature is their extension primarily along the flanks, and from there directly into or even across the spinal cord. This distinctive mode of lesion spread is the most consistent trait in the lesion's genuine specification (Plates I through V, IX, X). Especially in its extreme expressions, this lesion characteristic (cf. Plate II, figg. 1, 1', left-sided scar), most clearly characterized in Charcot's 1865 case report (26) (lesion sketches at Paris' "Bibliothèque Charcot"), cannot be accounted for by any form of vascular affection.

The involvement of the spinal cord's sides with slender boat-shaped patches, constituting a particularly noteworthy diagnostic trait, was not seldom misinterpreted as bilateral nerve tract degeneration and referred to as "primary combined systemic degenerations of the spinal cord". And this regardless of the lesions' capricious changes in depth and their tapering off or even abrupt termination, both upwards and downwards, within the involved nerve tracts' course (65,29,160, 128,8,137). Both these lesion features clearly contradict a lesion interpretation in terms of an affection of nerve tracts.

From Dawson to Fog, specific patches involving shorter stretches of the spinal cord's flanks were preferably ascribed to some sort of correspondingly aligned vascular affections. But all

studies on the spinal cord's vascular patterns, up to the latest, rich 1988 documentation by Thron (140), have shown that a vascular pattern corresponding to the specific spinal cord lesions' pattern of spread simply does not exist.

In multiple sclerosis-specific spinal patches, even the vessel-related changes do not support the thesis that the lesions are actually of a vascular origin. This is already apparent from the manner in which tissue clefts – such as those in figg. C and D of Plate IX, or those illustrated by Ballet (8) -- open up from the spinal cord's surface along major vessel stems entering the spinal cord's flanks. Both these peculiar clefts and the patches' wedge shapes await explanation, as do the reasons why concerned arteries and veins are only affected in their most peripheral parts.

The "inflammatory demyelination" theories are further disproved by the many lesion vessels which present themselves, up to their finest ramifications, here and there as zones of departure of sclerosed fiber strands, which may be lined by inconspicuous myelin sheaths and nerve fibers (35, 50).

A last peculiarity of spinal multiple sclerosis which contradicts the idea of a strictly vessel-related lesion concerns the manner in which the distinctive lateral patches first evolve (see Plate VIII, B) and then advance (illustration in Plate IX, figg. C and D). Microscopically, the patches' more or less sclerosed fabric everywhere inserts into spiky and bizarrely angulated fibrous projections, penetrating a priori into particularly strong fibrous strands which are affected lesionwards by a dense fibrillary hyperplasy. These strands' transition into healthy fibrous tracts occurs in the form of a plain fiber hypertrophy.

The tissue changes marking the lateral spinal patches' advance show no actual dependence on particular blood vessels. Accordingly, in evolving patches of the spinal cord's sides hardly any inflammatory cell infiltrates have ever been traced (35, 50, 64). One further feature of spinal multiple sclerosis which does not agree with the conception of a multifocal inflammation can be observed in the direct modification of fibrous structures in the lesions' entire extent -- degrading them, at its worst, to homogenous lumps located at, in particular, the spinal cord's circumference, or altering them just by way of the plain hypertrophy marking the patches' terminal extensions.

In the lesions of "disseminated encephalomyelitis", by contrast, interstitial fibrosis has always been noted to form not the first but the last of the tissue changes -- and it has consistently been found to evolve, around each individual focus of inflammation, as a broadening circumferential sclerosis advancing in reverse order, i.e. towards the lesion center (35, 96).

Encephalitis-Foci and Specific Brain Plaques: Worlds Apart

The earliest illustrations of specific lesions of cerebral multiple sclerosis make it obvious that the massive plaques surging up in and off of definite areas of the ventricular border (Plate IV, fig. 1; Plate V, fig. A; Plate VI) and the damages "punched" into the pons (Plate IV, fig. 2) are distinct from the cerebral lesion patterns which blood-borne agents typically produce. The

same applies to any evidence on the modes of expansion of "Dawson's fingers" and "Steiner's splashes" along and away from particular cerebral veins (Plate VII; Plate VIII, fig. A).

One unique feature of multiple sclerosis-specific brain lesions is their origin primarily from definite stretches of relatively large plaque-veins reaching to, and then coursing along, the border of cerebral ventricles and the surface of the brainstem. The same applies to the emergence of ovoid "Steiner's splashes" from venous segments, bendings and branchings, upstream along a "Dawson's fingers" parent vein (Plate VII)(109). No less remarkable are the observations on a leakage of blood primarily from the plaque veins' strongest-walled proximal lengths or stems (35,109,2).

As to the widespread confusion of the venous conditioning of the plaques of cerebral multiple sclerosis with the typically transitional vessel-related random spread of the foci of "disseminated encephalomyelitis", the terms "vein" and "venule" need to be more clearly differentiated. The lack of a consistent definition and separation of these two vascular units has substantially contributed to the confusion regarding the origins and nature of multiple sclerosis.

Venules connect capillaries and veins, normally resorbing fluid exuded from the capillary bed. The seepage out of the capillaries ordinarily turns into a flow back, beginning with venules having a diameter of about one hundredth of a millimeter (33). However, while the point at which capillaries turn into venules appears well defined, the diameters beyond which venules are said to become veins range considerably -- from less than a twentieth of a millimeter to more than half a millimeter.

According to much of the literature on multiple sclerosis, specific brain lesions are said to arise in venules, while "encephalitic foci" apparently stem from veins, although the specific multiple sclerosis plaques -- in all specific observations -- are said to originate from veins measuring from one tenth of a millimeter up to two millimeters in diameter, while the foci and streaks of "cerebral inflammatory foci", according to all available evidence, proceed from venules of less than a tenth of a millimeter diameter. And so a specific lesion vein of approximately half a millimeter diameter is referred to as a "venule", while a far smaller venule lying amidst a focus of inflammation is spoken of as a "vein". This mix-up may have contributed to the fact that investigators of specific multiple sclerosis lesions never seem to have been challenged or felt obliged to ask why and how the diverse supposed "MS-agents" become injurious specifically in the neighborhood of strong, scarcely penetrable venous channels (35,109,47,1).

Multiple Sclerosis: Notional Veil Covering Lesion Identity

There can be no doubt that Carswell's "remarkable spinal cord lesion", as well as Charcot's specific findings of cerebral multiple sclerosis, on the one hand, and "disseminated encephalomyelitis", on the other, are two entirely different kinds of pathological entities which could only become notionally integrated by characterizing them with, and subsuming them under, sufficiently broad histological and neurological terms. The designation "multiple

sclerosis" has thus turned into a blanket label covering all sorts of unexplained pathological entities. As the specific multiple sclerosis pathology is not to be accounted for by a blood-borne agent's scattering, it must be of interest to find out why and how researchers trying to unravel the cause of multiple sclerosis became so fixated on a circulating agent's trail.

(IV-2) From Randomly Spread Foci to MS-Agent

Though not based on any specific evidence, the simplistic tenets that multiple sclerosis constitutes nothing but a definite kind of multilocular (grey) tissue degeneration, scarring, or demyelination, caused by some sort of cryptogenic, systemically disseminated inflammatory agent, have been fervently propagated. We will try to retrace the series of (mis-)conceptual propositions which have led to positing various (consistently mysterious, invisible and evasive) blood-borne agents as the cause of an all too vaguely defined disease entity.

Cruveilhier's Suppositions about the Lesion Cause

A relationship of Carswell's "peculiar diseased state" to metastases of malignant growths or infectious processes had been insinuated before microbes and malignant cells were properly identified. Despite the lack of evidence for any protuberant or infiltrating growth, Cruveilhier, in presenting his first specimen of multiple sclerosis (Plate II, figg. 1, 1'), already speculated that the apparent tissue degeneration might have resulted from a dissemination of cancerous masses. Cruveilhier also directly misidentified his specific observations with an unspecified condition marked by a spread of distinctly bulging lesions into the posterior columns of the spinal cord (Plate II, fig. 2), and he additionally subsumed under one and the same title of "grey degeneration", manifestations of two long-known infectious processes – syphilis and tuberculosis (Plate II, figg. 3, 4).

An Enticing Notion: "Lawless Lesion Spread"

As early as 1866, Edme F. A. Vulpian critically distorted the picture of spinal multiple sclerosis which Charcot's earliest synopsis of the specific observations had projected. In a threefold manner Vulpian's paper proved disastrous in confusing the issue:

- Firstly, by directly identifying as "sclérose en plaques" -- the preferred French synonym for multiple sclerosis -- two specific (Plates I and III), one entirely different (Plate II, fig. 4) and several ill-defined post mortem findings.
- Secondly, by misinterpreting Charcot's 1865 genuine instance of spinal multiple sclerosis as a case of systemic nerve tract degeneration.
- Thirdly, and most counterproductively, by positing that the lesions of multiple sclerosis are spread, both individually and generally, without any perceivable order (152).

Vulpian's last dictum was readily embraced by all researchers in this field: Ordenstein subscribed to it, stating that the locations of multiple sclerosis lesions were absolutely

indefinite (93); Ribbert noted that no two specimens resembled each other in their lesion localizations (112); and Marburg was convinced that the particular lesions were not specifically localized (76). In keeping with the quick establishment of this point of view the well-defined, identifying characteristics of the specific observations of multiple sclerosis consistently escaped notice.

Charcot Misread: Multilocular Affection Not Proof of Systemic Spread

Charcot paradoxically introduced his second, later widely adopted synonymous designation of cases of multiple sclerosis as "disseminated sclerosis" in his classical report on a specimen with a spindly scar involving both of the spinal cord's sides in almost their entire lengths and to varying depths -- the deepest in its thoracic section (26). The reasons for Charcot's choosing the epithet "disseminated" are unclear, as he subsequently pointed out that "the predominant role ascribed to the blood vessels in the evolution of the pathological process [of multiple sclerosis] has not by any means been demonstrated", and further explicitly noted that there was no proper explanation for the unique lesion disposition of multiple sclerosis (31).

Ordenstein's Referential Mix-Up

In his 1867 thesis, Ordenstein erroneously mismatched his specific observation of multiple sclerosis with diverse other nervous affections, in particular with a clear instance of disseminated encephalomyelitis, originally presented by Rindfleisch in 1863 as a cryptic case of "grey degeneration" of brain and spinal cord (93). Rindfleisch's account on this particular specimen relates that its cerebral and anterior spinal white matter were covered over with miliary inflammatory foci, each emerging from a massively engorged and infiltrated blood vessel. There was thus neither any distinctive parallel to Ordenstein's findings nor any evidence for lesion traits which would by themselves have proven indicative of a specific form of multiple sclerosis (113).

In his 1872 "Manual of Pathological Histology", Rindfleisch pointed out that, aside from the just described inflammatory form of grey degeneration, there also existed a plain, non-inflammatory form -- exemplified by Frommann's classic observation of multiple sclerosis of the spinal cord (Plate IX, figg. A, B, 114).

Leyden's Misequations

Ernst Leyden's publications on multiple sclerosis only made matters more confusing. On the one hand, Leyden referred to Frommann's case of genuine spinal multiple sclerosis as an instance of nervous tract degeneration (65); on the other, he indiscriminately presented three specific instances of spinal multiple sclerosis as well as two cases of a multifocal spinal scarring after smallpox as cases of myelitis (66). Eventually, Leyden even related a purely clinical account of a child's unexplained nervous troubles under the strictly anatomical pathological heading of "multiple focal sclerosis. (Encephalomyelitis disseminata, Leyden.)" (67). By now it

was obvious that "encephalomyelitis disseminata" and multiple sclerosis had become inseparably merged, at least in a terminological sense.

Kahler and Pick: Emergence of the Multiple Sclerosis Agent

The existence of an infectious "MS-agent" was first postulated by Otto Kahler and Arnold Pick in 1879, three years after Robert Koch's earliest description of a pathogenic microbe's (anthrax) life cycle (56). The two physicians announced that the evolution of multiple sclerosis in the wake of infectious diseases had been demonstrated by certain well-known (and thus not quoted!) instances of multiple sclerosis following attacks of cholera and smallpox, as diagnosed by Charcot himself, and by the observation of a period of ataxia (!) in a typhus patient of Clement's and another typhus patient of their own (56).

The data presented could hardly be considered in any wise peculiar to a definite form of multiple sclerosis, which was "by nature infectious", but the cases were the ultimate source of the unshakable belief that multiple sclerosis is brought about by some (sub-) microscopic agent.

Marie's Infectious Multiple Sclerosis

The idea of an infectious origin of multiple sclerosis was propagated with much enthusiasm by Pierre Marie, a student of Charcot's and later a leading neurologist in Paris. Of the plethora of data which Marie marshaled to support his claims, only his two best-documented observations will here be focused on.

Marie referred to only one case of multiple sclerosis of his own, which was identified by certain neurological symptoms having evolved subsequent to typhoid fever. Marie's case history revealed the following:

In the first one or two years after the patient's recovery from typhoid fever, his speech turned into a drawling "marked by all of the characteristics observed in multiple sclerosis". During the next two years "other symptoms of multiple sclerosis" supervened, including difficulties in writing and walking. Apparently the only observation made by Marie himself half a year later, of intensified tendon reflexes, oculomotor troubles and tremor during exertion, affecting mainly the left hand, concluded the entire diagnostic evaluation (81).

To radically eliminate any doubts as to the infectious origin of "disseminated sclerosis", Marie then quoted abstracts of five comparable reports, stressing that these were by no means exhaustive: "To bring together all the corresponding cases would have the entire bibliography on multiple sclerosis pass revue" (81). Among the five select case-reports Marie referred to, one provided by Wilhelm Ebstein in 1872 is unique for its complementary post mortem study (40), which Marie considered absolutely confirmatory of his diagnosis of multiple sclerosis.

In his original paper, Ebstein had actually claimed that the particular findings had shown a most complete analogy to those observed in "multiple insular sclerosis of the central nervous

system" (40). He reported: A patient with a persistent weakening of tongue, neck and limb motion, which had become manifest in the wake of typhus abdominalis, succumbed eight years later to "pulmonary phtisis" (tuberculosis). At post mortem, the white matter of spinal cord and spinal bulb, especially in its central and posterior areas, was strewn over everywhere with roundish grey foci, up to the size of millet seeds, shading off into normal white matter. Under the microscope, many foci presented themselves as nodular scars marked by a dwindling of nerve fibers and distended blood vessels (40).

Ebstein's findings were thus certainly not identical with Carswell's "peculiar diseased state", but reflected an apparent multifocal scarring process subsequent to typhus abdominalis. In view of this clear instance of multifocal myelitis, it was hard to argue with Marie's idea that "multiple sclerosis" was attributable to "fungal (micro-) embolisms" of different infections (81).

Marie's 1892 lectures on the diseases of the spinal cord blurred the conception of multiple sclerosis even more thoroughly: The renowned neurologist defined multiple sclerosis as the subject of certain unspecified illustrations by Carswell, Cruveilhier and Charcot, and as the topic of some vaguely indicated works by Rokitansky, Türck, Frerichs, Rindfleisch and Vulpian. There followed a lengthy discourse on the condition's neurology, and then Marie reiterated: "There is a plainly clear cause of the sclerotic cerebrospinal plaques. This quite effective cause is infection, or a series of infections. Regarding the multitude of observations of instances of postinfectious multiple sclerosis, this causal relationship can no longer be denied" (82).

Stressing once more, as the prime feature of this kind of pathology, the absolute irregularity of its multifocal spread, Marie further repeated Ribbert's assertion that it was impossible to find even two cases of multiple sclerosis -- compare Plate I to Plates VI, IX and XI -- which resembled each other (112), so fitful and bizarre, so independent of any anatomical system were the lesions' localization and progression. The non-distinctive patterns of the dozens of crude lesion illustrations which attended Marie's assertions on multiple sclerosis were made-to-order.

Ultimately, however, a definite mechanism determining the lesions' disposition was defined: The damages were noted to originate in blood clots adhering to the walls of certain blood vessels, the actual damages being correlated to perivascular infiltrations of lymphatic corpuscles (immunocytes). For Marie, the cause of "multiple sclerosis" by some infectious agent was beyond doubt (112).

Though lacking precise substantiation, Marie's lecture on multiple sclerosis proposed two types of multiple sclerosis, which were to be strictly distinguished: "Actual multiple sclerosis", marked by plaques appearing sharply punched out; and "multilocular diffuse sclerosis", whose lesions were characterized by "certain continuations, or at least prolongations [of the tissue affection], into the neighboring tissues". Marie thus gave a description of two kinds of changes remotely reminiscent of specific spinal patches and cerebral plaques. But as the lesion types

were neither assigned particular sites nor concretely exemplified, Marie's multiple sclerosis conception remained throughout non-specific of the condition (82).

Marie's theses on the nature of multiple sclerosis reflected or were borne out by the medical "hot topics" and domineering scientific interests of his time. His monopolizing of the term "sclérose en plaques" (multiple sclerosis) for post-infectious cerebrospinal affections is understandable, but in referring to Carswell and other authors of illustrations specifically identifying multiple sclerosis he left doubts as to what kind of lesion he was ultimately talking about.

Marburg's Circulatory Toxin Spread

Marburg's numerous papers on multiple sclerosis -- none of which referred to any multiple sclerosis-specific pathological observation -- illustrate best the vague meaning which the term "multiple sclerosis" had taken on by the turn of the 20th century. Also entirely ignoring the necessity of providing some distinctive characteristics of multiple sclerosis, Marburg campaigned primarily against an understanding of (acute) multiple sclerosis as a primary fibrosis. Indicating that this sort of multilocular cerebrospinal inflammation was equally related to childhood infections and hereditary cerebral white matter diseases (74, 77), and emphasizing an absolutely irregular random lesion spread as token of its strictly uniform macroscopical pathology (75), he invited a large spectrum of speculations as to the condition's origin(s).

In the end, however, Marburg was convinced that multiple sclerosis resulted from a disseminated encephalomyelitis brought about by a circulating toxin (75, 76, 79). Without ever offering any concrete feature for identifying the condition itself or discriminating it from Kahler, Pick and Marie's infectious multiple sclerosis, Marburg finally proposed that the infectious type be terminologically distinguished from his toxic one as demyelinating and sclerosing par-encephalomyelitis (80).

Pette's Mediating Decision: Multiple Sclerosis Due to an Allergy

Again, without presenting any specific evidence, and detached from any findings relating to Carswell's "peculiar diseased state", Heinrich Pette, beginning in 1927, achieved the conceptual integration of Marie's infectious and Marburg's toxic multiple sclerosis under the common designation of, not disseminated encephalomyelitis, but rather multiple sclerosis. The term multiple sclerosis thus ultimately came to refer to diverse, non-distinctive and unexplained, cerebral and spinal inflammatory affections ascribed to certain (postulated) blood-borne agents.

Whether a corresponding cerebrospinal lesion was labeled multiple sclerosis or disseminated encephalomyelitis was, according to Pette, just a matter of the neurologist's personal preference, dependent simply upon whether he imagined the inflammatory process to have already been superseded by scarring, or not (95).

Pette conceived of multiple sclerosis as being the result of an exposure to different microbes or complex organic compounds, a welcome conciliatory proposition which he justified in attributing the condition to an allergic reaction (97,100). Under Pette's premise that the affection was actuated by way of some hypersensitivity reaction, postvaccinal encephalomyelitis came to be commonly accepted as the key to understanding multiple sclerosis (98). Unacquainted with any genuine multiple sclerosis specifications, Pette considered his allergy hypothesis in fact as the only possible explanation of the condition's cause (99, 100).

In presenting brain and cord specimens of three cases of a so-called "acute disseminated encephalomyelitis" of unknown origin, Pette actually claimed, without substantiation or questioning, that the lesions in these cases -- all emerging from small inflamed blood vessels or surfaces to the cerebrospinal fluid (96, 99) -- were identical with those in old and oldest cases of multiple sclerosis and corresponded to the classical pathological findings referred to under this term. There were not even any objections to Pette's pompous announcement that his third case, apparently because it had run a somewhat longer course than the others (four months as against five respectively two weeks) would provide a full explanation of the entire development of multiple sclerosis (96).

The Aftermath

With the adoption of Pette's allergy conception, the specific pathology of Carswell's "peculiar diseased state" appeared doomed to fall into oblivion. After having first been subjected to diverse trivial characterizations, inappropriate blanket definitions as well as misleading categorizations, then next to curious co-evaluations with essentially different or simply ill-defined pathological entities, the truly specific multiple sclerosis-findings seemed to have actually been rationalized out of existence.

In surveying their "multiple sclerosis-like" postvaccinal encephalomyelitis findings, two researchers treading in Pette's footsteps accordingly had to admit: "We have no definite clues as to the pathogenesis, or even consistently adequate criteria for the specific diagnosis of multiple sclerosis" (145).

(IV-3) Looking Back in Frustration

Neither by interpreting multiple sclerosis in terms of a cryptogenic multifocal inflammation nor by explaining it with some (sub-)microscopic blood-borne agents' systemic scattering have the classic – and clearly specific – multiple sclerosis observations ever been taken into account. Though still frequently represented in the form of a decorative frontispiece introducing some historical account on the discovery of multiple sclerosis, Carswell's "peculiar diseased state", unmistakably identified in his earliest pictorial documentation of what later came to be referred to as multiple sclerosis, has as yet never been the subject of a sober formal analysis. The special features of Carswell's "peculiar diseased state" and the kind of injury it represents have never actually been closely scrutinized and specified.

Instead, in dealing with a purely notional disease entity deprived of any relationship to concrete exemplary observations, current researchers apparently dare not venture beyond postulating a specifically demyelinating and yet clinically defined multiple sclerosis. It seems in fact that the present speculative approach to the subject matter, involving the futile quest for some figmentary, in particular immunological multiple sclerosis agent, can be abandoned without scruples. This should be done in all haste to avoid prolonging unnecessary human (and animal) suffering.

Chapter 5 is devoted to divulging and delineating the injurious events and causes behind multiple sclerosis.

(V) Lesion Explanation in Physical Terms

“The end of all our exploring will be to arrive where we started and know the place for the first time.”

T. S. Eliot, 1942

The prevailing understanding of multiple sclerosis in vague clinical or histological terms, which neither derives from nor refers to any specific factual findings, has necessarily remained incomplete - and has prevented the proper appreciation of all truly valuable observations, beginning with Carswell and Charcot, and leading up to Fog and Oppenheimer. The degree of specificity of these basically unparalleled findings, and thus their true meaning, have never really been realized. As a consequence, a proper understanding of the processes behind these particular findings has not been achieved.

Carswell's "peculiar diseased state" was identified primarily by simple naked eye observation. From this it follows that its distinctive damages must also originate in specifically large-scale physical impacts. The massiveness of the impulses required to bring about the macroscopically discernible changes leads us to the conclusion that the actual agents of multiple sclerosis are not so minuscule as they are commonly imagined.

The mechanisms and forces required to produce Carswell's "remarkable spinal cord lesion" with its long, pointed patches encroaching primarily upon the spinal cord's flanks, will now be discussed. Then the physical impacts responsible for the so-called cerebral "Dawson's fingers" and "Steiner's splashes", vein-dependent projections off of the cerebral ventricles and into the brain stem, will be outlined. In explaining why these two lesion types tend to occur together this book concludes by pointing to ways of tracing the lesion causes and providing for their cure.

(V-1) The Dynamics of Lesion Formation

The development of the pattern of a lesion depends, in the final analysis, on plain mechanical principles. The first clues for determining the cause of a particular kind of injury are thus to be derived from its outer shape and inner organization. In multiple sclerosis, a sober consideration of the patterns of lesion "dissemination", i.e. of the "fibre-borne" extension of patches in the spinal cord's flanks, and the eccentric expansion of homogenous plaques from definite brain veins, will clarify several significant points:

1. Which forces are capable of bringing about the particular changes via the structures from which the lesions originate and in the observed directions and ranges of spread?
2. In which ways are the injurious forces transmitted onto the structures and zones from which the lesions arise?
3. From which sources do the injurious impulses arise?

4. Which forces control and check the lesion spread?

An explanation follows of the dynamics of lesion formation, as well as of the physical preconditions, i.e. the structural abnormalities required, for multiple sclerosis-specific changes to evolve. In light of the fundamental differences between cord patch extension and brain plaque expansion, the specific affections of spinal cord and brain will be discussed separately.

(V-1-a) The Spinal Patches' Peculiar Mode of Extension

We have already mentioned the unique naked-eye observations which serve as positive identification of spinal cord multiple sclerosis. Before focusing on the genesis of these changes, their most characteristic features will be reiterated.

Essential Gross Traits of Cord Affection

The specific observations of multiple sclerosis of the spinal cord all have one thing in common: the extension, within inconspicuous surroundings, of bizarrely shaped marks in both the spinal cord's sides, which are seen to encroach, via a more or less jagged front, on considerable lengths of mainly the lateral cord flanks (Plate I; Plate II, figg. 1, 1'; Plate III; Plate IV, figg. 3, 4; Plate V, figg. C, D; Plate VII, fig. B; Plate IX, figg. A, B, C; Plate X, Nerv. cerv. II-VII). Such lesions are occasionally seen to interconnect, inside the cord, up- and downwards, or also from flank to flank (Plate IV, fig. 4: B, B') (71).

Thus lateral patches may reach such a length as to be mistaken for a systemic affection of nerve tracts (Plate VIII, fig. B) (17, 18, 35). It is worth noting that a certain length of one side of the cord may show separate patches, whereas the same length on the opposite side proves fairly evenly altered to a definite depth (Plate II, figg. 1, 1').

Slight magnifications may also reveal a close array of small saw-toothed lesion spikes, or a series of crenelated rhomboid or bizarrely frayed-out patches encroaching upon the spinal cord's sides, as illustrated in a specimen in which also a tendency for posterior spinal patches to longitudinally interconnect is evident (Plate VIII, fig. B).

In considering all of these peculiar forms of lesion spread, the specific cord patches' plain macroscopic appearance provides a number of clues on the injurious causes of lesion formation.

Subtle Peculiarities in Patch Development

Documenting the upper "speed limit" of cord lesion advance, Lauenstein's 1877 observations of homogeneously softened patches in the cord flanks (Plate X), already discussed in more detail in the first chapter of this book, leave no doubt that the lesion domains can be abruptly affected within a very brief period of time.

A better understanding of the usual, more gradual mode of progression of spinal patches can be gained from Frommann's 1867 report: The local changes first manifested themselves in a

plain thickening of prominent connective tissue tracts constituting the spinal cord's interstitial framework, and then spread out to involve ever thinner fibrous structures. Along their farthest extensions, forming the patches' advancing fringe zones, the fibrous structures' thickening fluidly tapered off into normal, prominent connective tissue structures surrounding lesions (Plate IX, figg. C, D) (35, 42). Vascular segments showed a strengthening of their connections to neighboring tissues, developing rather irregularly in definite directions.

At a later stage, tiny fibrils had developed, first within and then out of certain sectors of thickened fibers, along the involved connective tissue tracts, and at definite sectors of blood vessels. From time to time, both thickened fibers and more or less recent fibril developments degenerated into hyaline lumps (Plate IX, figg. C, D).

Along blood vessels irradiating the periphery of not only the sclerosed but also otherwise inconspicuous adjoining sectors of the spinal cord, sooner or later, more severe changes had also occurred: The stems of many major blood vessels entering the lateral cord flanks were to certain depths marked by roughly delimited tissue clefts -- seamed by stumps of ruptured fibers and fibrils.

According to Dawson, the local changes primarily manifested themselves in an abnormal augmentation, i.e. reinforcement of a system of unusually prominent connective tissue structures inserting into the cord's sides. He asserted that these proliferative changes in the fibrous fabric of the spinal cord's sides must be directly due to the lesion cause.

Mechanical Determinants of the Specific Cord Changes

In considering the dynamics of these lesion developments, three points have not yet been properly considered: (1) the significance of the peculiar vascular involvements, (2) the meaning of the continuously progressive connective tissue changes, and (3) the reasons for the specific patterns of lesion spread.

(1) The significance of the vascular involvements: The observations of torn fibrillary connections between lesion vessels and scarred surroundings led Frommann to assume that the tissue clefts irradiating the spinal cord sides along major vascular stems could only be mechanically caused. As to the cleft arrangements, such clefts could only have resulted from laterally directed tensile impacts. And regarding the blood vessel affections by specifically orientated scarring processes, all of these vessel-related changes must have been provoked by physical insults of the same nature.

(2) Connective tissue changes: All in-depth microscopic studies on the patches' gradual extension into the two sides of the spinal cord agree as to the primary nature of the local connective tissue affection, i.e. that the fiber thickening and fibril growth already start at the lesions' earliest stage of development -- independently from any other kind of tissue changes. According to Frommann's findings, this is also true of the hyaline degeneration affecting certain strands of thickened fibers and sprawling fibrils.

The striking parallels between the manner of spread of (1) the various connective tissue affections, and (2) the diverse vessel-related changes have, up until now, been given little attention. In fact, both vessel-related tissue clefts and scarring tissue wedges start at the lateral circumference of the spinal cord and proceed inwards from there. The idea that all fibrous tissue changes (plain fiber thickening, fibril development, degenerative hyalinization) are to be accounted for by outwards directed tensile impacts agrees with two principle considerations:

- Both as to their course and strength, the developments of the fibers and fibrils of the connective tissue depend on the direction and intensity of locally effective tensile stresses;
- A plain thickening and well-ordered replication of preformed fibrous structures is an adaptive reaction to the particular structures' exposure to unusual tensile strains.

Thus both the specifically oriented perivascular fibril developments and the corresponding strengthening of definite connective tissue tracts can be understood as adaptive processes to unusually intensified and chronically repeated tensile impacts exerted upon the spinal cord's sides. The vessel clefts entering the spinal cord's sides and the hyaline degeneration of equally flankbound fiber trains, on the other hand, can be accounted for as an overstraining of these parts by more vehement forces of the same type.

Steiner's illustrations of the changes at the spinal cord's outermost flanks (Plate VIII, fig. B) may serve to illustrate this point: The pictured lesion's saw-toothed and crenelated patterns must necessarily be the work of an energetic, peripherally directed pulling. The observations of strikingly strengthened connections between the specifically affected spinal cord's fibrous hull and the subjacent scarred tissue (18, 87) are of particular interest in this respect.

The primary affection of the — mechanically first and most strained — tough connective tissue structures irradiating the specific lesion-domains, and the progression of the changes by way of a "fiber-borne" spread (Plate IX, C, D) support the explanation of lesion formation by unduly intensified tensile impacts acting continually upon the spinal cord's flanks.

(3) The specific pattern of lesion spread: In 1978 David R. Oppenheimer pinpointed the anatomical element which alone accounts for the specific involvement of the spinal cord's sides. Noting that some affected cord segments were drawn out from side to side, Oppenheimer was the first to realize that the lateral lesion wedges originated in the line of insertion of the right and left denticulate ligaments in the cord. He concluded that the observed changes might be attributable to an outward tug via the denticulate ligaments, the cord's main staying elements in the spinal subarachnoid space.

But there are also observations of additional patches affecting the cord especially along its posterior midline, for example by Cruveilhier (Plate III, figg. 1', 1''), or also at the front of the spinal bulb (Plate I; Plate V, fig. C) (23, 31, 42). In fact, the denticulate ligament, attached to the

entire length of the spinal cord's sides (55, 165), forms the only constant outer fixation of the spinal cord. Further highly variable fibrous connections occur between especially the back of the spinal cord and the spinal subarachnoid space's outer walls (45, 58, 61), the most conspicuous anterior fixation reaching the spinal bulb (58). It seems as though any of these accessory fixations can also engender specific mechanical lesions, but there exists no equally impressive evidence of this.

Another principle consideration must be made concerning the pointed extensions marking all of these specific patches' advancing fronts:

- Explainable only as a mechanically induced phenomenon, these spinal patches are particularly characterized by the acute tapering off (down to a microscopic size) of the progressive fibrous tissue changes -- as evident from the sharply angulated or bizarrely angled terminal lesion extensions -- which no infiltrative organic process of diffusion or expansion can account for.

Having indicated the structures and forces via which the specific flank affections of the cord are brought about, the how and why of the injuriousness of the diverse outer fixations of the spinal cord will shortly be considered, as soon as the dynamics of the specific lesion developments of multiple sclerosis of the brain have been outlined.

(V-1-b) Dynamics of Brain Plaque Expansion

The basic differences between the peculiar flank affections of the spinal cord and the specifically related damages to the brain have never been thoroughly thought through or systematically investigated into. However, it is crucially important to appreciate the radical differences between the two types of lesion formations, in order to gain a proper understanding not only of the injuries to spinal cord or brain but also to comprehend the nature of the specific changes of multiple sclerosis in their entirety.

Gross Characteristics of Specific Brain Lesions

To describe cerebral multiple sclerosis, pathologists have developed a special vocabulary which distinctly reflects the condition's massive and impetuous outbursts. Specific plaques found "punched out" of the periventricular tissue of the cerebral hemispheres and the front of the brainstem have been referred to as "fingers" (Dawson, Lumsden) or "fists" (Adams). And, as it is from here that the largest lesion imprints emerge, Steiner gave the lateral ventricular angle the ominous multiple sclerosis epithet "Wetterwinkel" (source of the thunderstorms).

The earliest clear and absolutely distinctive illustrations of multiple sclerosis of the brain gave evidence of a surging up of compact lesion waves in and off of the ventricular border, along the undersurface of the corpus callosum, sweeping also over wide inner expanses of the cerebrum. And Steiner, in his succinct overview of the specific spread patterns of cerebral multiple

sclerosis, characterized the isolated plaque-projections into the periventricular tissue aptly as "splashes".

Although generally appearing -- in contrast to the frayed out cord patches -- very smoothly contoured, ventricle-based specific lesions may also appear projected out in the form of thin and pointed spikes or even a coherent series of spiky waves. But despite an occurrence of such pointed projections, the specific cerebral lesion formations are distinctly different from the spinal ones with respect to the striking evenness of the tissue affection, also over very large individual plaque domains.

Periventricular "Steiner's splashes", projected out so far as to appear cast onto the cerebral cortex, tend to become flattened upon touching this apparently less easily impressed border. And yet, according to Steiner's lesion sketches, it seems that certain cortical surfaces of the brain can also become injured from the outside by fairly small, but otherwise typically shaped plaques. Lumsden, who was often confronted with comparable findings, actually asked himself what kinds of forces might bring about all these peculiar changes (69). There can yet be little doubt that, without a rather forceful mechanical impact, the cerebral plaques' sweeping over at times enormously large tissue domains cannot be plausibly accounted for. One great enigma remains as to the nature and causes of these vigorous impulses.

Impacting Veins, the Real Agents of Brain Injury

Up until 1937, the issue of which structures determine the development of all the distinctive forms of cerebral plaque spread was not definitively resolved. And even today there is no more than a handful of solid documents on the where and how of the specific plaque spread in cerebral multiple sclerosis.

Putnam and Adler were the first researchers to provide clear evidence on the peculiar plaque-vein relationship characteristic of cerebral multiple sclerosis. The specific brain plaques were shown to originate along certain strangely distended and distorted vein stems (Plate VII) (109). Unfortunately, these two researchers did not realize the implications of their findings as to the condition's genesis.

Scheinker, on presenting the most impressive cross-sectional image of a specific lesion's expansion (its "splattering out") to one side of its vein (Plate VIII, fig. A), spoke only of vascular distension, apart from indicating that this paravenous lesion development had perhaps originated in "local circulatory disturbances" (117, 118).

Fog's systematic observations on the specific vein relationship of cerebral plaques provided the clearest proof of the vein's crucial role for lesion expansion and projection (47, 48). And yet, once more there was no explanation of the significance of the particular findings in terms of lesion causation.

Fog definitively proved that the plaques of cerebral multiple sclerosis arise not from the ventricular lining but from definite segments of large epiventricular veins and that the lesions' digitating out into the cerebral hemispheres also consistently evolves in a corresponding vein relationship: Both ventricle-based "Dawson's fingers" and peripheral "Steiner's splashes" originate from venous branches radiating off of the cerebral ventricular border or (visualized in the opposite direction) emptying into epiventricular collecting veins.

Fog further found that isolated lesions preferentially arise from points where plaque veins begin to narrow down, where they turn, or arborize. His observations from a comprehensive study of two cerebral hemispheres also confirmed what Putnam and Scheinker's multiple sclerosis specimens had already illustrated, i.e. that lesion expansion proceeds in a generally highly eccentric manner with respect to its point of origin at some section of the particular plaque vein's walls. These findings made clear the reasons why previous investigators had commonly failed to trace the cerebral plaques' unique venous conditioning: Divergences between the longitudinal axes of the plaque veins, on the one hand, and the lesion axes, on the other, not only constitute the rule rather than the exception, they also capriciously change along the plaque veins' courses -- whereby the veins' eccentricities may be stunning. But the full meaning of all these observations for an understanding of multiple sclerosis has as yet not been properly appreciated.

Forces Behind Cerebral Plaque Expansion

Five features characterizing the spread of the specific brain lesions of multiple sclerosis prove useful for determining injurious impacts which cause the damages:

1. The common asymmetries of the plaque expansions away from their veins, especially in their bizarre extremes.
2. The plaques' emergence exclusively from certain segments or even sectors of the walls of their veins.
3. The consistent countercurrent spread of damage, i.e. its progression, without exception, in a direction diametrically opposite to the normal venous (and interstitial fluid) flow.
4. The origin of lesions -- and particularly of the largest lesion formations -- preferentially from strong, i.e. thick-walled and therefore scarcely penetrable vein segments.
5. The lesion spread only along a small, select system of cerebral veins.

Following is an evaluation of each of these five key aspects of lesion genesis, especially with regard to its significance for the understanding of the disease:

1. Asymmetries in the lesion expansion, and eccentric courses of the plaque veins: Compact lesion expansions or projections mainly or exclusively to one side of a length of plaque vein, such as are typical of cerebral multiple sclerosis, require a well-directed

mechanical impact that no microscopic agent could conceivably provide, especially through such strong vein walls as have commonly been found in periventricular plaque expansions. Further explanations of the process responsible for the unique plaque projections are given below.

2. Peculiarities of the involved vein lengths: The central role of veins in the development of cerebral multiple sclerosis has mainly been obscured by the capricious eccentricities of plaque vein placement relative to lesions. The emergence of plaques only from certain sectors of the walls of their veins, which at first sight appears rather erratic, might also have contributed to the late realization of the role of veins. The expansion of brain plaques mainly from venous bends and narrowings, or from terminal venous arborizations, was in fact directly described only in 1964 by Fog (47, 48). Of particular interest here is the occurrence of analogous findings in hypertensive encephalopathy, in which areas particularly exposed to the pressure of abutting arterial bends tend to become demyelinated, or even battered out to circumscribed hollows (reminiscent of the hollows surrounding Dawson's plaque veins) (117, 146, 163).
3. The lesion spread countercurrent to the normal venous flow direction: According to all available evidence, specific injuries to the brain consistently start out from strong proximal vein segments and then proceed for varying distances upstream. The process of cerebral multiple sclerosis thus advances in a direction diametrically opposed to that of normal venous flow. The extraordinary significance of this circumstance was already grasped by Carswell, long before the role of veins in cerebral multiple sclerosis was realized: "In inflammation the local congestion commences in the capillaries, afterwards extends to the small veins, but never to large branches; in mechanical congestion [by venous flow inversion] the blood accumulates first in the venous trunks, which are always conspicuous, and afterwards in the branches and capillaries" (24). Carswell here indicated a relationship which actually constitutes the master key to the accurate understanding of multiple sclerosis. **The advancement of the specific cerebral lesion formations of multiple sclerosis in the direction from wide vein stems upwards towards narrow venous roots shows the whole process to be essentially mechanical in nature.**
4. Primary altering of strong-walled periventricular collecting veins. Putnam and Adler's first illustrations of the plaque veins' "gnarled" look, i.e. irregular distensions and distortions (Plate VII) represent another finding awaiting its explanation in terms of mechanics. And there was one further significant finding: The maximal distension of plaque veins immediately downstream to their thrombotic obstructions and their maximal distortion downstream to other, more peripheral plaques. This included a stepwise increase in the thrombosed veins' proximal distension, in the direction of the obstruction, at each of three subsequent points of entrance of venous affluents.

Comparable, though less detailed, observations made several years later underlined the necessity of providing a physical explanation for the plaque vein's distention, not upstream, but downstream to its thrombotic occlusion (38).

In this connection a picture presented by Ingrid V. Allen in 1981 is especially relevant. On a cerebral hemisphere's medial aspect a number of vein-centered plaques are apparent, spread beneath the lateral ventricular wall and surging up off of the corpus callosum undersurface (3). On closer examination it can be discerned that the stem and first branches of a large ventricle vein have grooved for themselves wide beds whose breadth is nearly three times that of the involved vessels' diameters — a detail reminiscent of Charcot's first documentation on cerebral multiple sclerosis (Plate IV, fig. 1). Together with the findings of specific plaques rising up from strong, proximally strikingly distended veins, these observations again point to the effects of notably strong forces.

It seems obvious that the necessary physical impulses must have been exerted from inside the plaque veins, i.e. they can only have been exerted by venous blood. In considering the peripheral narrowing and central widening of the venous tree, as well as the excessive rises in pressure only in the central veins, the following conclusion appears self-evident:

The specific brain plaques of multiple sclerosis can only be caused by energetic venous back-jets set in motion by intermittent rises in the pressure in the large collecting veins of the neck, but especially of the chest.

Since the process of cerebral multiple sclerosis does not lead to an even distension of the proximal branches of a particular venous drainage system up to a definite length, since its plaques emerge preferentially from venous bends, narrowings and arborizations, and since the plaque expansions from veins show such striking eccentricities, the impacts of the regurgitant blood quite clearly tend to be very unevenly distributed (Plate VIII; Plate IX, fig. A). To be able to exert such effects the peripherally directed venous currents must at times attain remarkably high velocities and affect the brain in the course of very short periods of time.

5. As to the selective involvement of a definite venous drainage system in the brain: While injecting, under heavy pressure, carmine-gelatine into a human body's straight sinus in an attempt to render its tributary veins in the cerebral hemispheres more prominent, Benno Schlesinger, in 1939, came unawares very close to explaining the cerebral multiple sclerosis lesion's genesis. He realized that extravasations produced around the lateral ventricles' outer angles (Steiner's "Wetterwinkel") "closely simulate the distribution and even the shape of plaques in advanced cases of multiple sclerosis" (121). In this way, Schlesinger, an expert on cerebral vascular anatomy, clearly demonstrated that the most prominent plaque veins represented the main affluents of the straight sinus. The fact that other affluents of the straight sinus, i.e. veins of the

brainstem, must equally be considered as classic plaque veins appears to have been noticed only by Lumsden, in 1970 (71).

Physical Containment of Cerebral Lesion Spread

The factors which limit the specific plaque spread everywhere within a sharply punched-out front have never been plausibly accounted for. And yet, we have now become acquainted with many revealing details. The following relationships appear of basic significance:

- The compact massiveness of major "Dawson's fingers" or "Steiner's splashes" indicates that the thrust of the regurgitant blood is not simply exhausted by friction-induced vascular resistance.
- Nevertheless, "plaque borders" forming a series of thin, outwardly pointing epiventricular lesion spikes -- as they would be expected to be brought about by a corresponding series of regurgitant blood columns' deceleration tracks -- were found projecting into the corpus callosum (Plate VI, figure at bottom).
- Farther off of the cerebral ventricles, the relative reluctance of plaques to transgress the borders to the cortical grey matter is of particular interest: Rather than being conditioned by a local concentration gradient of some myelin constituent(s), the tendency of lesions to flatten out before impinging upon the relatively stronger pulsating cerebral cortex might testify to the greater effectivity of cortical arterial counterimpacts.

Because of the complexities of their dynamic interaction, the forces which are particularly effective in counterbalancing a local venous regurgitation's impact will be discussed in further detail below. But before embarking on this analysis of the dynamics of the venous back-jet into the brain, a brief interpretation follows of what the specific cerebral damages of multiple sclerosis imply with respect to local tissue changes.

Explanation of Microscopic Findings within Cerebral Lesion Domains

What merits comment first is the generally overestimated and overemphasized prominence of the damages to myelin sheaths over the damages to axons of nerve fibers. Upon its arrival in the brain, a venous back-jet acts upon the involved vein walls with a force directly dependent on their resistance to the retrograde venous shift. The vein walls which transmit the mechanical impacts directly to the embedding brain substance produce a sudden, centrifugally spreading tissue shearing or wave of tissue expansion. The concerned tissue layers' warping relative to their surroundings endangers the myelin sheaths and especially their delicate, vitally important connections to the oligodendrocytes, far more than the robuster axons of the nerve fibers. The more or less "selective" demyelination of the specific plaque domains can thus be expected to result primarily from destructions of the myelin sheaths' exceptionally frail supply lines. The lesion edges simply map out where local venous impacts have ceased being injurious.

The retrograde expansions of plaque veins -- and thus also of cerebral plaques -- must thereby be limited by pressure rises inside the involved vein, as well as inside the craniovertebral space as a whole, which suffice to cancel the thrust of the regurgitant blood. This explanation of lesion development admits solely of a very short timespan of brain plaque evolution, and it makes understandable why, as numerous pathologists -- from Dawson to Lumsden -- have noted again and again, brain lesions appear punched out "all in one piece".

The evolution of a diffuse halo of interstitial fibrosis silhouetting the edge of older cerebral plaques now appears equally explainable: The adaptive hypertrophy and hyperplasy of connective tissue can be regarded as a most sensitive indicator of repetitive, no longer destructive or demyelinating strains burdening the tissue beyond a certain distance from the impacting venous wall. However, in just diffusely shading off the cerebral plaque borders, this weak and even fibrosis (71) contrasts markedly with the isolated reinforcement of more prominent fibrous structures marking the spinal patches' fringe zones (50) -- a further detail pointing to a difference between the mechanisms injuring the brain and spinal cord respectively.

The plaque veins' massive and bizarre wall distensions, hardly explainable by a single local impact (Plate VII), and the diffuse hyperplasy of perivenous fibrous structures, most plausibly accounted for by a chronically repeated overstraining of the local tissue fabric, indicate that the venous regurgitations of cerebral multiple sclerosis intermittently recur in a persistent manner. In addition, the tendency of both the specifically affected brain and spinal cord areas to become gradually enlarged makes evident that the injurious events underlying the two forms of lesion development are capable of aggravating themselves and each other -- a further peculiarity of multiple sclerosis which has, as yet, not been properly accounted for.

A sound, comprehensive explanation of the process of multiple sclerosis must therefore not only point out the factors effectuating (and delimiting) the distinctive ways and manners of spread of the different cerebral and spinal lesion formations, but also show why both lesion types continually enlarge their domains.

(V-2) Cause of the Injurious Impulses

As a result of his painstaking, well-documented investigations, Fog was led to postulate two revolutionary theses -- which unfortunately went almost unnoticed:

- "The changes in the central nervous system may be the result of disturbances of circulation, especially in the venous drainage ... these disturbances may be intermittent and of varying degree."
- The hypertrophy, i.e. excessive development of fibrous connective tissue, about the major plaque veins is somehow related to the pressure changes within the chest (47, 48).

In 1955 Lumsden had stated that "... [from the available evidence] it does not follow that the agency [causing multiple sclerosis] is necessarily a living or even a chemical one". Instead, he suggested that vascular pressure was the condition's effective cause, since not only the way its lesions extended, but also their shapes, appeared determined by such mechanical factors as stress lines and pressure forces (69).

Later, after having realized the significance of Dawson's and Fog's (although, apparently, not of Schlesinger's) observations on cerebral multiple sclerosis, Lumsden explicitly noted that its lesions were related to "the deep venous drainage of the white matter", i.e. to affluents of the straight sinus. Aware of the fact that the plaque-vein relationship actually constituted "a fundamental or even the dominant principle of the process of multiple sclerosis", Lumsden anticipated that the problems relating to its development would possibly be solved when "more is known about the relative venous pressures in these regions" (71).

Irrespective of these insights, since the 1970's no headway has been made towards a better understanding of the relationships between local venous pressures and specific plaque developments. But Lumsden's and Fog's notes may be taken to spotlight the legitimacy and urgency of the attempt at clarifying the injurious potential of venous back-jets selectively burdening, in particular, the deep system of venous drainage of the brain.

(V-2-a) Recurrence of Injurious Venous Back-Jets into the Brain

Although rises, inside the trunk, in central venous pressures of several hundred millimeters of mercury, i.e. meters of blood-column, can be considered physiologically normal, little is known regarding potential impacts of these pressures upon individual venous drainages of brain and spinal canal. While exploring the injurious effects of venous regurgitations into, in particular, straight sinus affluents, two principally interrelated questions must be answered:

1. How can venous regurgitations obtain the necessary thrust to produce the large lesion expansions projected into the cerebral hemispheres?
2. What limits retrograde central venous pressure propagations to exerting their effects only in the specific lesion domains?

Central Venous Pressure Dynamics and Distribution

Respiratory or other bodily efforts produce central venous pressure excesses which can increase at tremendous speeds to very high levels. During accidental mechanical impacts upon trunk and neck even more brutal central venous pressure rises can be anticipated, and these occurrences have never been properly investigated. As a result of these pressure rises the soft tissues surrounding the cerebral veins may become burdened by pressures which they cannot withstand, even under minor exposure. Whether the brain is thereby damaged or not depends mainly on three critical circumstances:

- Speed, volume, and extent of the retrograde shifting of central venous blood;

- Circumscription of the central venous excess pressures' intracranial and, above all, intracerebral distribution;
- Volume, in particular of venous blood, to be momentarily displaced out of separate compartments of the craniovertebral space.

Little reliable information exists on even the most fundamental structural and functional determinants of course and extent, let alone consequences, of more massive venous back-jets into the human brain. And due attention has not been paid to the critically enhanced risk of vehement repulsions of central venous blood into exclusively the one or the other cerebral venous drainage system.

Fog mistakenly assumed that the pressure in the cerebral veins simply fluctuates parallel to the pressure in the chest. Even more paradoxically, he explained the perivenous tissue stiffening along major plaque veins of cerebral multiple sclerosis as being a safeguard preventing these veins' inspiratory collapse (48). Thus no one has bothered ask the following questions:

- Which quantities of blood can, with which force, be pushed up from central veins into the intracranial and, in particular, the intracerebral venous tributaries of either the right or the left internal jugular vein?
- How is regurgitant blood volume distributed in dependence on individual venous valvular, anastomotic, and branching patterns?
- To which extent can the spread of venous back-jets pushing up through only one internal jugular vein be confined to a particularly small cerebral venous territory?

Little reliable information exists already on such plain and fundamental facts as

- the individual prevalence, degrees, and bilateral relationships of the valvular incompetencies of the two internal jugular veins and of their extracranial venous tributaries and anastomoses;
- the individual and temporal variability in the pre-filling, the maximal capacity, and the conductivity to flow, of the venous drainages capable of carrying regurgitant blood towards and into the brain; and
- the individual and temporal variability in flow conductivity and pre-filling of the veins capable of venting the craniovertebral space for back-jets into a separate venous drainage system inside the cranial cavity or spinal canal.

Spread of Acute Rises in Central Venous Pressure into the Brain?

Any momentary excess central venous pressure tends to revert the flow in any venous drainage which is not guarded by competent valves. If a venous drainage system lacking competent valves is not vented by venous anastomoses (lacking opposing valves) and its pathways are

nowhere compressed, regurgitant blood can most easily and rapidly be pushed back in any affluent vein as far as its outermost tributary vessels.

But so long as its circumvallation is intact and nowhere substantially yields to pressure, the craniovertebral space can accommodate regurgitant blood volumes only as long as a commensurate venting, i.e. evacuation of blood from separate venous drainages of cranial cavity and spinal canal, is possible. If back-jets into different cerebral or spinal venous drainage systems compete, length and flow resistance of the respective venous pathways will also influence the pressure load to which walls and neighborhood of the involved veins will be exposed.

Skull radiographs of supposed victims of multiple sclerosis, showing striking widenings of the main venous passageways out of (and into) the cranium first stirred the present author's particular interest in the diverse anatomical pathological specifications of multiple sclerosis (119). A closer scrutiny of the truly unique post-mortem observations of multiple sclerosis led him to the conclusion that the specific cerebral changes evolve under the following circumstances and in the following ways:

The first prerequisite for plaque veins' injurious activities appears to be a disproportionately severe valvular incompetence of that internal jugular vein by which these plaque veins are specifically drained (Plate XIV, figg. A, B). Via this vein regurgitant blood then must be conducted into a relatively minor intracranial catchment area – meaning, in a classic instance of cerebral multiple sclerosis, directly up into the straight sinus affluents. Provided there are no venous anastomoses strong enough to provide for the involved venous pathways' sufficient venting, venous regurgitations of injurious intensities into the straight sinus' affluent veins must occasionally result (119, 120).

The remarkable functional isolation of the straight sinus system of venous drainage has been consistently illustrated not only anatomically (9, 120), but also – more dramatically -- in the literature on the disastrous effects of (especially thrombotic) straight sinus occlusions. The evidence presented demonstrates that, if the venous outflow through the straight sinus is blocked, the collateral venous drainage from the brain's central parts tends to decompensate under the mere perfusion load of blood circulation (10, 14, 54, 129, 149, 150, 151, 156). It becomes clear that the potentially far more massive overloading of the straight sinus affluents by intense venous back-jets can certainly not be expected always to be dissipated in a harmless fashion.

Apart from their typically being limited to affluents of the straight sinus, the brain plaques of multiple sclerosis expand from only certain small section(s) of a plaque vein's surface. The question arises as to what may limit and localize the particular venous regurgitation effects. A consideration of the acute, both absolute and relative rises in intra-abdominal and intra-thoracic pressure reveals the existence of a number of factors which can limit a spread of venous

regurgitation into particular cerebral veins. The primary limiting factor against a strong retrograde venous invasion of a particular part of the brain lies in the rapidity with which the thrust of any correspondingly localized venous regurgitations is counterbalanced by separate competing venous regurgitant and ordinary arterial flows into the craniovertebral space. A regurgitation into particular cerebral veins may also end precipitously, due to an exhaustion of its own volume or, in cases involving a larger intracranial venous domain, because the veins providing for a venting of the craniovertebral space are emptied too quickly. Finally, the ordinary course of trans-diaphragmal pressure gradients makes it probable that venous regurgitations into the brain will often be stopped by competing venous back-jets from intra-abdominal collecting veins into the epidural vein plexus of the lower spinal canal.

The Development of Venous Back-Jets into the Brain

The conditions predisposing to injurious venous back-jets via one internal jugular vein into the brain are rather complex, and research must be initiated to directly determine when and how such potentially disastrous events take place. If the venous drainage of the straight sinus is critically isolated and the other venous tributaries of the large collecting veins of the trunk are guarded by competent valves, potentially disastrous back-jets of central venous blood will begin as soon as the valve of the straight sinus-related internal jugular vein has been burst through, become too distended, or if its valve-leaflets have critically shrunken.

However, this is only one requirement for the occurrence of potentially disastrous venous back-jets into the brain. The presence of opportunities for sufficiently massive venting effluxes out of the craniovertebral space is equally necessary. As soon as the venous back-jet has become established, it will always tend to become more severe -- simply because of its continual "washing out" of its own pathways into, and of the channels of concurrent venting effluxes out of, the craniovertebral space. Thus initially harmless venous regurgitations may, sooner or later, reach injurious intensities.

The physical impacts causing "Dawson's fingers" and "Steiner's splashes" thus appear comprehensively accounted for.

(V-2-b) Specific Spinal Scars: Also Venous in Origin?

The observations on Carswell's remarkable spinal flank affection and its "fibre-borne" spread along the insertions of certain outer anchorages of the cord do not lend themselves to strictly the same lesion interpretation as the related damages to the brain. It shall therefore be explained under which circumstances certain stretches of the spinal cord's sides, in particular, may become specifically injured.

Some researchers have supposed that the lesions of spinal multiple sclerosis also originate from veins, or that the lesions relate to definite venous territories. However, Oppenheimer, who first realized the denticulate ligament's pivotal role in specific spinal patch developments, stressed that only few of the lesions which he had studied had shown a relationship to veins,

and that the only patches which had done so were found to irradiate the spinal cord's sides. Oppenheimer supposed that it was full flexions of the cervical spine, especially in the presence of rigid antero-lateral fixations of the spinal dural sac, which exerted the detrimental stresses upon the denticulate ligament's attachments to the spinal cord. But he failed to explain by which mechanisms and under which circumstances cervical flexion might stretch definite segments of, in particular, thoracic or still lower parts of the denticulate ligament in such a way and to such a degree as to result in a damaging of lower spinal cord sectors.

The spinal cord can be selectively injured in its sides either by being displaced posteriorly, relatively to unyielding lateral fixations, by a blunt impact upon its front (57), or also – in virtually any location – by an interference of particularly rigid outer spinal cord fixation(s) with the cord's up or down movements relative to the dural sac (73, 142). Violent impacts upon an individual's back effectuating sharp intradural displacements and, in particular, vehement subarachnoid fluid shifts, have been observed to actually lead to widely scattered, anchorage-related damages to the spinal cord's flanks (12, 88, 122).

Regarding the mechanisms capable of producing bilateral cord lesions, even the most detailed accounts on classic instances of spinal multiple sclerosis consistently lack any indications of either some massive thrust upon the spinal cord's front or of a heavy impact upon walls or surroundings of the vertebral canal. It is difficult to believe that in all these observations (series of) corresponding injurious processes or events were consistently overlooked. Therefore the search must begin for an endogenous source of comparably effective injurious impulses capable of continually injuring the spinal cord's specifically affected parts.

In view of the many striking parallels, both as to lesion patterns and tissue changes, between the remote effects of spinal concussion and spinal multiple sclerosis, vehement endogenous subarachnoid fluid shifts might be expected to play a preeminent role in disease genesis. If sufficiently intense, such fluid displacements could actually damage the spinal cord partially or in its entire length, conforming to the zones of insertion of the denticulate ligaments and of other particularly tough anchorages of the spinal cord to the dural sac. The question arises as to which mechanism actuates such intense endogenous shifts of spinal subarachnoid fluid -- shifts which are continually repeated and thereby tend to become intensified.

In comparing arterial as against venous conductivity, and the intensity of the pressure-dependent blood-displacements in the arteries as against the veins, the volume-displacements within the craniovertebral space, which are effected by local veins, can be expected to be far more effective than those of arterial vessels. This conclusion is corroborated by the results of studies on arterial and venous cerebrospinal fluid displacements, which show that far the most intense (endogenous) cerebrospinal fluid shifts are due to venous back-jets rushing back from veins inside the abdomen into veins encompassing the lowest part of the spinal dural sac (cf. Plate XIV, figg. C, D) (39, 111). There are individuals who have shown subarachnoid fluid shifts so vehement as to be likened to "plunger strokes" (136).

Continually subjecting the spinal cord, in short-term repetitions, to this intrinsically self-aggravating mechanism, venous back-jet induced subarachnoid fluid displacements from the lower spinal canal may gradually become so intensified as to eventually be injurious. Dragging the spinal cord headwards, such intense subarachnoid fluid shifts may be capable of injuring the spinal cord by means of abrupt tensile impacts exerting their effects specifically along those fibrous structures which represent the spinal cord's most stressed anchorages to the dural sac.

Both specific spinal cord patches and brain plaques, though differing essentially as to form and structure, thus become understandable in terms of one and the same causative mechanism, namely vehement, specifically localized venous regurgitation into the craniovertebral space.

Again, to cause the continual venous regurgitations into the lower spinal canal to individually attain injurious intensities, a mere progressive washing out, i.e. widening, of their own pathways and of those for the simultaneous venting effluxes may be sufficient. The strength of the individual retrograde flows will thereby tend to increase in proportion to the speed and ultimate height of the ascent of any infradiaphragmal, i.e. intraabdominal excess pressure -- dependent on the preceding emptying of the veins of the lower spinal canal. This emptying predisposes to more massive regurgitations, both directly and by a relatively stronger filling of separate veins providing the compensatory venting of the craniovertebral space. Spinal regurgitation, however, differs from cerebral as to the far greater number and complexity of the venous pathways connecting the intraabdominal collecting veins to the venous plexuses encompassing the lowermost part of the spinal dural sac.

(V-2-c) Co-Evolution of Specific Cerebral and Spinal Lesions

Given an individual anatomical predisposition to isolated venous back-jets into the brain's central veins, or to intensive venous regurgitations into the lower spinal canal, even trivial exertions or mechanical impacts from outside the body, producing an abrupt increase in intra-thoracic or intra-abdominal pressure, may cause multiple sclerosis-specific lesions to emerge. In these particular injurious events, the role played by blood-borne agents will never be anything but accessory (although a great number of bacteria may play a smaller or greater role in the selective destruction of an internal jugular vein valve or also the thrombotic obliteration of some functionally important venous connection).

Cerebral and spinal multiple sclerosis often co-evolve. And the central question remains as to why (and how) this is so.

Reduced cerebrospinal fluid volumes and pressures may a priori be considered as crucially important. They generally predispose to more intense venous back-jets both directly, by causing a weaker counterpressure to any retrograde venous flow into brain and spinal canal, and also indirectly, by implying a more abundant pre-filling of the venous vessels of brain and spinal canal, thus providing an opportunity for more massive displacements of venous blood

from the craniovertebral space. The tendency towards intense back-jets into brain and spinal canal must thus be substantially enhanced.

Low cerebrospinal fluid volumes and pressures can result in various ways: Artificially, for example by lumbar punctures or operations opening the cranio-vertebral space; or constitutionally, in particular because of low arterial pressures, or a low venous outflow resistance from the brain. The latter of these factors is of particular interest: A low flow resistance in the venous pathways of the brain can, in the presence of an individual predisposition to venous regurgitations into a definite venous drainage system of both brain and spinal cord, critically "destabilize" the venous dynamics of the craniovertebral space, already by its predisposing to a lower cerebrospinal fluid pressure.

One common determinant factor for the development of intensified venous back-jets is again most relevant in this context: Any ongoing venous regurgitation into brain or spinal canal will progressively "wash out" its own pathways as well as those of the venting effluxes. Venous regurgitations into brain and spinal canal must thus, in the long run, mutually enhance each other -- because any substantial widening of venous passages draining a major compartment of the brain, whether it be due to local venous regurgitations or compensatory venting effluxes, lowers not only the flow resistance against the venous currents themselves but, in diminishing cerebrospinal fluid filtration pressure -- according to the dependence of this latter on the cranial venous outflow-resistance, also weakens the resistance against cerebrospinal fluid shifts in the cranio-vertebral space. The mutual enhancement of these pathomechanisms is a particularly relevant factor in the causation of specific cerebral and spinal lesions in multiple sclerosis.

(V-3) The Key to Decoding Multiple Sclerosis: Specific Data

What has been presented above are the results of the first thorough attempt to clarify which observations of multiple sclerosis can actually be considered specific, and to elucidate their meaning. These evaluations have unfortunately brought to light some serious problems in the understanding of the disease.

(V-3-a) Inadequate Disease Specifications

As it is presently understood, the term "multiple sclerosis" conceals, in a threefold manner, the nature of any disease process to which it is applied:

1. There is the misleading clinical multiple sclerosis conception, which reflects the setting apart of certain cryptic disease processes simply by means of two quantitative properties: number and time. No facts have ever been presented to prove that this manner of determining the presence or absence of multiple sclerosis by the timing of unexplained neurological episodes is actually justified.
2. No less confusion has been created in additionally specifying multiple sclerosis by two different, each sufficiently broad histological terms which are supposed to provide a

morphological lesion specification coextensive with the neurological dysfunctional one. Here the early all-inclusive label "grey degeneration" became the forerunner of the expression "(multiple) sclerosis", implying that the disease was due primarily to a scarring process. Since some researchers felt that the latter lesion definition (yet not the term itself) was too narrow, the vague notion "primary inflammatory demyelination" came to be used. Nowadays, in certain circles, multiple sclerosis is considered to be caused by some sort of unexplained inflammatory cellular infiltrate of auto-aggressive immunocytes causing a specific myelin destruction (less obtrusive damages to other tissue components being, without qualms, passed over in silence). But the distinctiveness of this disease entity has never been substantiated by any specific exemplary observations.

3. Even the most fundamental differences in the lesion patterns shown by individual instances of (clinical) multiple sclerosis were eventually simply glossed over in conceiving of multiple sclerosis as the result of some random form of lesion spread, effected by some essentially cryptogenic "disseminated encephalomyelitis". The epithet "disseminated" thereby complicates matters by
 - supposing a form of lesion spread which is characterized by nothing but an absolute randomness -- which lesion-interpretation apparently justifies
 - considering the specific patterns of, in particular, cerebral "Dawson's fingers" and spinal cord flank affections just as coincidental, and eventually
 - attributing any corresponding condition to a single, essentially cryptic, systemically scattered blood-borne agent.

This vagueness about multiple sclerosis is handy: It avoids the need to differentiate observed lesion patterns and to elucidate their meaning. Together with the speculative "inflammatory demyelination" conception, the idea of "disseminated sclerosis" has thus proved pivotal in establishing multiple sclerosis – including its specific forms -- as a "cryptogenic, autoimmune disease". However, regarding the indefiniteness of these clinical, histological and pathogenic disease characterizations, it is abundantly clear that no two victims of multiple sclerosis ever necessarily suffer from one and the same disease, in terms of a definite specific injurious process.

(V-3-b) Reappraising Specific Multiple Sclerosis Observations

Experts on the history of medicine and neurology have always acknowledged the genuine identification of the pathological entity of multiple sclerosis by Carswell in his illustration of "a peculiar diseased state" of pons and spinal cord. However, they have never made explicit in just which respects these observations proved to be "peculiar".

As a result, the insight has never dawned that the instances of multiple sclerosis showing lesion patterns essentially identical to either the cerebral or spinal lesions of Carswell's "peculiar diseased state" in fact constitute a monolithic block of specific observations corresponding to one well-defined and absolutely distinct pathological entity. And so the specific pathological observations have never been definitively analyzed and traced back to their most plausible cause, i.e. the injuriously intensified effects of intermittent flow-reversals in definite venous drainages of the cranio-vertebral space.

Openly admitting, "We have no idea what the neurological episodes now being classified as 'clinically definite multiple sclerosis' are due to", not only avoids the pretence of a false diagnostic security but will also prevent many, otherwise inevitable, therapeutic blunders.

It was not possible, up until 1981, to identify Carswell's "peculiar diseased state" in the living. Accordingly, it might then have been claimed that all these problems were merely of a theoretical interest. Since then, however, magnetic resonance imaging has shown ever more potential for tracing the peculiarities of the specific lesions of, first, cerebral and then, later, also spinal multiple sclerosis in vivo. And with respect to the most recent advances in magnetic resonance flow mapping it might become feasible to demonstrate the occurrence of injurious venous back-jets into the brain and of vehement subarachnoid spinal fluid shifts even before patients have succumbed to their first "bout(s)", i.e. clinical manifestation(s) of multiple sclerosis.

(V-3-c) Practical Consequences of Specific Observations

The question of whether we decide to strive for a solid morphological multiple sclerosis specification is not only a matter of intellectual honesty. What is at stake is the development of the proper diagnostic and therapeutic procedures for patients falling prey to "Carswell's peculiar diseased state", i.e. to a potentially utterly serious and yet, in principle, fully curable central nervous affection.

Escaping from the ruts and sloughs which multiple sclerosis research has, over more than one and a half centuries, become entrenched in will be no easy endeavour. It is urgent to extricate ourselves from a confusing and misleading terminology, in which any research relating to multiple sclerosis has become hopelessly snarled. There are also countless private and corporate interests opposing any change in the present state of affairs — and they work quite effectively perpetuating the belief that (clinical) multiple sclerosis can, in the near future, actually be cured pharmaceutically.

Having carefully weighed the available evidence, the impartial reader will yet realize that any promise of providing a cure for "clinically definite multiple sclerosis" cannot, either sooner or later, be fulfilled. Time is of the essence, if the suffering is to be stopped.

The two key-objectives for achieving real progress in multiple sclerosis-research must accordingly be the development of magnetic resonance techniques which are suitable to

1. identify multiple sclerosis-specific changes and
2. determine their cause(s).

Specific instances of multiple sclerosis could be definitively cured by employing two surgical procedures aimed at preventing a recurrence of injurious venous back-jets:

- To prevent the development of “Dawson’s finger” projections, a ligature of the jugular vein carrying injurious venous back-jets into the center of the brain might form a simple method for curing an otherwise relentlessly progressing disease.
- As to spinal cord flank lesions, the development of minimally traumatizing surgical procedures for interrupting the pathways of vehement venous regurgitations into the lowermost spinal canal appears – as challenging as this task may appear –equally promising.

Progress in the field of magnetic resonance imaging and flow mapping, which make it possible to trace, in living patients affected by “Dawson’s fingers” or also spinal cord flank lesions, the venous flow inversions and related subarachnoid fluid shifts responsible for the particular lesion-developments, will then open the way towards achieving a proper cure and even primary prevention of the corresponding diseases.

References

1. Adams, C. W. M., Abdulla, Y. H., Torres, E. M., and Poston, R. N.: Periventricular lesions in multiple sclerosis: Their perivenous origin and relationship to granular ependymitis. *Neuropathol Appl Neurobiol*, 13:141,1987.
2. Adams, Colin: *A Colour Atlas of Multiple Sclerosis & Other Myelin Disorders*. London, Wolfe Medical Publications, 1989.
3. Allen, Ingrid V.: The pathology of multiple sclerosis -- fact, fiction and hypothesis. *Neuropathol Appl Neurobiol*, 7:169,1981, fig. 1.
4. Allen, Ingrid V.: Demyelinating diseases. In Adams, J.H., Corsellis, J.A.N., and Duchon, C.W. (Eds.): *Greenfield's Neuropathology*, 4th ed. London, Arnold, 1984.
5. Assenmacher, Dennis R., and Ducker, Thomas B.: Experimental traumatic paraplegia. The vascular and pathological changes seen in reversible and irreversible spinal cord lesions. *J Bone Joint Surgery*, 53A:671,1971.
6. Babinsky, J.: *Etude anatomique et clinique sur la sclérose en plaques*. Paris, Masson, 1885.
7. Bálint, Rudolph: Beiträge zur Aetiologie und pathologischen Anatomie der multiplen Sklerose. *Dtsch Zschr Nervenheilk*, 16:437,1899.
8. Ballett, G., and Minor, L.: Etude d'un cas de fausse sclérose systématique combinée de la moelle (Scléroses systématiques ou peritubulaires de la moelle et scléroses perivasculaires). *Archiv Neurologie*, 7:44,1884, Plates I-III.
9. Bekov, D. B.: *Atlas of the Venous System of the Brain in Man* (in Russian). Moscow, Izdatelstvo Meditsina, 1965.
10. Belman, Anita Lesgold, Roque, Clemente T., Ancona, Richard, Anand, Azad K., and Davis, Raphael D.: Cerebral venous thrombosis in a child with iron deficiency anemia and thrombocytosis. *Stroke*, 21: 488, 1990.
11. Berlin, C.: Beitrag zur Lehre von der multiplen Gehirn-Rückenmarks-Sclerose. *Dtsch Arch Klin Med*, 14:103,1874.
12. Bikeles, G.: Zur pathologischen Anatomie der Hirn- und Rückenmarkerschütterung. *Arbeiten Inst Anat Physiol Centralnervensyst Wiener Univ*, 106, 1895.
13. Borst, Max: Die multiple Sklerose des Zentralnervensystems. *Ergebnisse Allg Path Pathol Anat*, 9:67, 1903.
14. Bots, G. Th. A. M.: Thrombosis of the Galenic system veins in the adult. *Acta Neuropath*, 17:227,1971.

15. Bouchard: Des lésions anatomiques dans l'ataxie locomotrice progressive et de ses rapports avec d'autres maladies peu connues de la moelle épinière. Congrès Méd-Chir Lyon, 79,1865.
16. Bouchard: Détails histologiques aux pièces anatomiques relatives à un cas de sclérose en plaques généralisée du cerveau et de la moelle épinière. CR Séances Mémoires Société Biologie, 4e série, V:14,1868.
17. Bourneville, and Guérard L.: La sclérose en plaques disséminées. Paris, Delahaye, 1869.
18. Buchwald, A.: Ueber multiple Sklerose des Hirns und Rückenmarks. Dtsch Arch Klin Med, 10:478,1872.
19. Bunge, Richard P., and Settlage, Paul H.: Neurological lesions in cats following cerebrospinal fluid manipulation. J Neuropath Exp Neurol, 16:471,1957.
20. Bunge, Richard P., Bunge, Mary Bartlett, and Ris, Hans: Electron microscopic study of demyelination in an experimentally induced lesion in adult cat spinal cord. J Biophysic Biochem Cytol, 7:685,1960.
21. Bunge, Mary Bartlett, Bunge Richard P., Ris Hans: Ultrastructural study of remyelination in an experimental lesion in adult cat spinal cord. J Biophysic Biochem Cytol, 10:67,1961.
22. Buss, O.: Beitrag zur Aetiologie und Pathologie der multiplen Sklerose des Hirns und Rückenmarks. Dtsch Arch Klin Med, 45:555,1889.
23. Carswell, Robert: Softening of organs. In Forbes, John, Tweedie, Alexander, and Conolly, John (Eds.): Cyclopaedia of Practical Medicine; Comprising Treatises on the Nature and Treatment of Diseases, Materia Medica and Therapeutics, Medical Jurisprudence, etc. London, Sherwood/Whittaker, 1835, Vol. IV, Suppl, pp. 1-21.
24. Carswell, Robert: Pathological Anatomy. Illustrations of the Elementary Forms of Disease. London: Longman 1838, Chapters "Inflammation", "Atrophy" (Plate IV), "Softening" (Plate IV).
25. Cervós-Navarro, J.: Gefässerkrankungen und Durchblutungsstörungen des Gehirns. In Cervós-Navarro, J., Schneider H., and Ule, G. (Eds.): Pathologie des Nervensystems. Berlin: Springer, 1980, Vol. I, pp. 176-210.
26. Charcot: Sclérose des cordons latéraux de la moelle épinière, chez une femme hystérique, atteinte de contracture permanente des quatre membres. Union Médicale, 451/467,1865.

27. Charcot: Pièces anatomiques relatives à un cas de sclérose en plaques généralisée du cerveau et de la moelle épinière. CR Séances Mémoires Soc Biologie, 4e série, V:13,1868.
28. Charcot: Histologie de la sclérose en plaques. Gaz Hopit Civils Milit, 41:554/557/566,1868.
29. Charcot, J. M.: Lectures on the Diseases of the Nervous System, 2nd ed., translation by Sigerson, George. Philadelphia, Lea, 1879.
30. Charcot, J.-M.: Leçons sur les maladies du système nerveux, 3rd ed. Paris, Delahaye, 1880, Vol. II, p. 472, Plate II.
31. Charcot, J.-M.: Leçons sur les maladies du système nerveux, 5th ed. Paris, Delahaye, 1884, vol. I, pp. 189-272, Plates VII, VIII.
32. Cohnheim, Jul.: Neue Untersuchungen über die Entzündung. Berlin, Hirschwald, 1873.
33. Cotran, R. S., Kumar, V., and Robbins, S. L.: Inflammation and repair. In Robbin's Pathologic Basis of Disease, 4th ed. Philadelphia: Saunders, 1989, pp. 39-88.
34. Cruveilhier, Jean: Anatomie pathologique du corps humain; ou description, avec figures lithographiées et coloriées, des diverses alterations morbides dont le corps humain est susceptible. Paris, Baillière, 1835-1842, Vol. II, Instalment 32, pp. 19-24, Plate 2, Instalment 38, pp. 1-6, Plate 5.
35. Dawson, James W.: The histology of disseminated sclerosis. Trans Roy Soc Edinb, 50:517,1916.
36. Del Río Hortega, P.: Estudios sobre la neuroglia. La glia de escasas radiaciones (oligodendroglia). Bol Real Soc Espan Hist Nat, 21:63,1921, Plates I-XIII.
37. Dohrmann, George J., Wagner, Franklin C., and Bucy, Paul C.: Transitory traumatic paraplegia. Electron microscopy of early alterations in myelinated nerve fibers. J Neurosurg, 36:407,1972.
38. Dow, Robert S., Berglund, George: Vascular pattern of lesions of multiple sclerosis. Arch Neurol Psychiat, 47:1,1942.
39. Du Boulay, G., O'Connell, J., Currie, J., Bostick, Thea, and Verity, Pamela: Further investigations on pulsatile movements in the cerebrospinal fluid pathways. Acta Radiol Diagn, 13:496,1972.
40. Ebstein, Wilhelm: Sclerosis medullae spinalis et oblongatae als Sectionsbefund bei einem Falle von Sprach- und Coordinationsstörung in Armen und Beinen in Folge von Typhus abdominalis. Dtsch Arch Klin Med, 10:595,1872.

41. Eichhorst, Hermann: Über Erkrankungen des Rückenmarks bei Menschenpocken. Dtsch Arch Klin Med, 111:1,1913, Plate I.
42. Engesser, H.: Beitrag zur Casuistik der multiplen Sklerose des Gehirns und Rückenmarks. Dtsch Arch Klin Med, 17:556,1876.
43. Erb, Wilhelm: Krankheiten des Rückenmarks. In Handbuch der Speciellen Pathologie und Therapie. Leipzig, Vogel, 1876, Vol. 11/2, Section 1, pp.84-120.
44. Esiri, M. M., and Oppenheimer D. R.: Multiple (Disseminated) Sclerosis (MS). In Diagnostic Neuropathology. Oxford, Blackwell 1989, pp. 225-234.
45. Felten, H.: Anordnung und Bedeutung der intraspinalen Rückenmarkaufhängung. In Junghanns, H. (Ed.): Die Wirbelsäule in Forschung und Praxis. Stuttgart, Hippokrates, 1958, Vol. 5: pp. 19-30.
46. Ferraro, Armando: Primary demyelinating processes of the central nervous system: An attempt at unification and classification. Arch Neurol Psychiat, 37:1100,1937.
47. Fog, T.: On the vessel-plaque relationships in the brain in multiple sclerosis. Acta Neurol Scand, 40,Suppl.10:9,1964.
48. Fog, Torben: The topography of plaques in multiple sclerosis, with special reference to cerebral plaques. Acta Neurol Scand, 41,Suppl. 15:1.1965.
49. Frerichs, F. Th.: Ueber Hirnsklerose. Häser's Arch Gesamt Med, 10:334,1848.
50. Frommann, C.: Untersuchungen über die normale und pathologische Anatomie des Rückenmarks. Jena, Frommann, 1867, Vol. 2: pp. 77-130, Plates I-VI.
51. Gebarski, Stephen S.: The passionate man plays his part: Neuroimaging and multiple sclerosis. Radiology, 169:275,1988.
52. Gledhill, R.F., Harrison, B. M., and McDonald, W. I.: Demyelination and remyelination after acute spinal cord compression. Exper Neurology, 38:472,1973.
53. Hallervorden J.: Anatomie und Pathogenese der Multiplen Sklerose. Münch Med Wschr, 97:509,1955.
54. Hornet, Th., and Vuia, O.: Critical intracerebral venous zones. Rev Roumain Neurol, 1:165,1964.
55. Huber, Jo. Jakob: De medulla spinali speciatim de nervis ab ea provenientiibus commentatio cum adjunctis iconibus. Gottingae, Vandenhoeck, 1741, pp. 4-6, Plate I, lc. 2.
56. Kahler, Otto, and Pick, Arnold: Beiträge zur Pathologie und pathologischen Anatomie des Centralnervensystems. Leipzig, Hirschfeld, 1879.

57. Kahn, Edgar A.: The rôle of the dentate ligaments in spinal cord compression and the syndrome of lateral sclerosis. *J Neurosurg*, 4:191,1947.
58. Key, A., and Retzius, G.: Studien in der Anatomie des Nervensystems und des Bindegewebes. Stockholm, Samson & Wallin, 1875, Vol. 1.
59. Koenig, G., and Dohrmann, G. J.: Histopathological variability in 'standardized' spinal cord trauma. *J Neurol Neurosurg Psychiat*, 40:1203,1977.
60. Kolb, Lawrence C.: The relationship of the demyelinating diseases to allergic encephalomyelitis. *Med Analyt Rev Internal Med*, 29:99,1950.
61. Kölliker, Albert: Mikroskopische Anatomie oder Gewebelehre des Menschen. Leipzig, Engelmann, 1850, Vol. I: pp. 488-490.
62. Krücke, W.: On the histopathology and pathogenesis of acute haemorrhagic leucoencephalitis, acute disseminated encephalitis and concentric sclerosis. *Internat Symp Aetiol Pathogen Demyel Diseases*, Kyoto, 1973, pp. 11-27.
63. Kurtzke, John F.: Multiple sclerosis: What's in a name? *Neurology*, 38:309, 1988.
64. Lauenstein, Carl: Beitrag zur Lehre von der acuten Myelitis. *Dtsch Arch Klin Med*, 19:424,1877, Plate III/B.
65. Leyden E.: Die graue Degeneration der hinteren Rückenmarksstränge. Berlin, Hirschwald, 1863, pp. 114-116.
66. Leyden, E.: Beiträge zur acuten und chronischen Myelitis. *Zschr Klin Med*, 1:1,1878.
67. Leyden: Multiple Herdsclerose (Encephalomyelitis disseminata, Leyden). *Jahrb Kinderheilk*, N.F.15:272,1880.
68. Lhermitte, François: Les leuco-encéphalites. Paris, Flammarion, 1950.
69. Lumsden, Charles E.: Pathology, Related Demyelinating Processes and the Experimental Pathology of Multiple Sclerosis. In McAlpine, Douglas, Compston, Nigel D., and Lumsden, Charles E. (Eds.): *Multiple Sclerosis*. Edinburgh, Livingstone, 1955, pp. 208-274.
70. Lumsden, C. E.: The neuropathological relationship of multiple sclerosis to human and experimental anoxic and toxic leucoencephalopathies. *Acta Med Belg*, 27,1957.
71. Lumsden, C. E.: The neuropathology of multiple sclerosis. In Vinken, P. J., and Bruyn, G. W. (Eds.): *Handbook of Clinical Neurology*. Amsterdam, North-Holland, 1970, Vol. 9, pp. 217-309.
72. Lumsden, C. E.: Pathogenetic mechanisms in the leucoencephalopathies in anoxic- ischaemic processes, in disorders of the blood and in intoxications. In Vinken, P. J., and

- Bruyn, G. W. (Eds.): Handbook of Clinical Neurology. Amsterdam, North-Holland, 1970, Vol. 9, pp. 572-663.
73. Mair, W. G. P., and Druckman, Ralph: The pathology of spinal cord lesions and their relation to the clinical features in protrusion of cervical intervertebral discs (A report of four cases). *Brain*, 76:70,1953.
 74. Marburg, Otto: Die sogenannte akute multiple Sklerose. *Mitt Ges Inn Med Wien*, 4: 200,1905.
 75. Marburg, Otto: Die sogenannte "akute multiple Sklerose" (Encephalomyelitis periaxialis scleroticans). *Jahrb Psychiat Neurol*, 27:211,1906.
 76. Marburg, Otto: Multiple Sklerose. In Lewandowsky, M. (Ed.): *Handbuch der Neurologie*. Berlin, Springer, 1911, Vol. 2/1: pp. 911-958.
 77. Marburg, Otto: Zur Sklerosefrage. *Mitt Ges Inn Med Wien*, 11:202,1912.
 78. Marburg, Otto: Allgemeine Pathologie der nichteitrigen Entzündungen des Zentralnervensystems. *Dtsch Zschr Nervenheilk*, 124:37,1932.
 79. Marburg, O.: Multiple Sklerose; Pathologie und Pathogenese. In Bumke, O., and Foerster O. (Eds.): *Handbuch der Neurologie*, Berlin: Springer, 1936, Vol. 13/5, pp. 633-650.
 80. Marburg, Otto: New studies in multiple sclerosis, II. Parencephalomyelitis periaxialis scleroticans (acute multiple sclerosis) in various infectious diseases. *J Mount Sinai Hosp New York*, 9:640,1942.
 81. Marie, Pierre: Sclérose en plaques et maladies infectieuses. *Progrès Médical*, XII:287/305/349/365;1884.
 82. Marie, Pierre: Sclérose en plaques, In *Leçons sur les maladies de la moelle*. Paris, Masson, 1892, pp. 108-162.
 83. Mayer, Richard F.: Conduction velocity in the central nervous system of the cat during experimental demyelination and remyelination. *Intern J Neuroscience*, 1:287,1971.
 84. McDonald, W. I., and Halliday, A.M.: Diagnosis and classification of multiple sclerosis. *Brit Med Bull*, 33:4,1977.
 85. McMenemey, W. H., and Smith, W. T.: Primary demyelinating diseases. In Symmers, W. St. C. (Ed.): *Systemic Pathology*, 2nd ed. Edinburgh: Churchill-Livingstone, 1979, Vol. 5, pp. 2250-2261.
 86. Meyer-Rienecker, H.: Multiple Sklerose, Abk. MS. In Bundschuh, G., Schneeweiss, B., and Bräuer, H. (Eds.): *Lexikon der Immunologie*. Berlin, Akademie Vlg, 1988, pp. 609-610.

87. Müller, Eduard: Die multiple Sklerose des Gehirns und Rückenmarks. Ihre Pathologie und Behandlung, klinisch bearbeitet. Jena, Fischer, 1904.
88. Mussen, Aubrey: The finer histological changes in the traumatic degenerations of the spinal cord, following bullet wounds of the cord substance, or shock to the vertebral column. (With Plates 7 and 8). *Rev Neurol Psychiat*, XIV:417,1916.
89. Ochoa, J., Danta, G., Fowler, T. J., and Gilliatt, R.W.: Nature of the nerve lesion caused by a pneumatic tourniquet. *Nature* 233:265,1971.
90. Oger, J., O'Gorman, M., Willoughby, E., Li, D., and Paty, D. W.: Changes in immune functions in relapsing multiple sclerosis correlate with disease activity as assessed by magnetic resonance imaging. *Ann New York Acad Sciences* 540:597, 1988.
91. Oppenheim, H., and Cassirer, R.: Die Encephalitis, 2nd ed. Wien, Hölder, 1907. Plate I.
92. Oppenheimer, D. R.: The cervical cord in multiple sclerosis. *Neuropathol Appl Neurobiol*, 4:151,1978.
93. Ordenstein, L.: Sur la paralysie agitante et la sclérose en plaques généralisée. Paris, Martinet, 1867, pp. 49-81, Plate II.
94. Otto, Albert: Casuistischer Beitrag zur multiplen Sklerose des Hirns und Rückenmarks. *Dtsch Arch Klin Med*, 10:531,1872.
95. Pette, H.: Zur Frage der infektiösen Aetiologie der akuten disseminierten Enzephalomyelitis resp. der akuten multiplen Sklerose. *Münch Med Wschr*, 74:1409,1927.
96. Pette, H.: Klinische und anatomische Studien. Über die Pathogenese der multiplen Sklerose. *Dtsch Zschr Nervenheilk*, 105:76,1928.
97. Pette, H.: Infektion und Nervensystem. *Dtsch Zeitschr Nervenheilk*, 110:221,1929.
98. Pette, H.: Zur Ätiologie und Pathogenese der multiplen Sklerose. *Med Klinik*, 2:1138,1936.
99. Pette, Heinrich: Die akut entzündlichen Erkrankungen des Nervensystems (Viruskrankheiten, Entmarkungsenzephalomyelitiden, Neuritiden). Leipzig, Thieme, 1942, pp. 339-535.
100. Pette, E. and Pette, H.: Die Multiple Sklerose -- ein immunologisches Problem. *Wiener klin Wschr*, 75:482,1963.
101. Poser, C. M.: Pathogenesis of multiple sclerosis. A critical reappraisal. *Acta Neuropathol*, 71:1,1986.

102. Poser, Charles M., Paty, Donald W., Scheinberg, Labe, McDonald, W. Ian, Davis, Floyd A., Ebers, George C., Johnson, Kenneth P., Sibley, William A., Silberberg, Donald H., Tourtellotte, Wallace W.: New diagnostic criteria for multiple sclerosis: Guidelines for research protocols. *Ann Neurology*, 13:227,1893
103. Prineas, John W.: The neuropathology of multiple sclerosis. In Koetsier, J. C. (Ed.): *Handbook of Clinical Neurology*, rev. ed. New York: Elsevier, 1985, Vol. 3(47), pp. 213-257.
104. Prineas, John W.: Pathology of multiple sclerosis. In Cook, Stuart D. (Ed.): *Handbook of Multiple Sclerosis*. New York, Dekker, 1990, pp. 187-218.
105. Prineas, John W., Barnard, Robin O., Revesz, Tamas, Kwon, Eunice E., Sharer, Leroy, and Eun-Sook, Cho: Multiple sclerosis. Pathology of recurrent lesions. *Brain*, 116:681,1993.
106. Prineas, John W.: The pathology of multiple sclerosis. In Herndon, Robert M., and Seil, Fredrick J. (Eds.): *Multiple Sclerosis: Current Status of Research and Treatment*. New York, Demos, 1994, pp. 113-130.
107. Putnam, Tracy J.: Studies in multiple sclerosis. IV. "Encephalitis" and sclerotic plaques produced by venular obstruction. *Arch Neurol Psychiat*, 33:929,1935.
108. Putnam, Tracy J.: Lesions of "encephalomyelitis" and multiple sclerosis. Venous thrombosis as the primary alteration. *J Amer Med Ass*, 108:1477,1937.
109. Putnam, Tracy J., and Adler, Alexandra: Vascular architecture of the lesions of multiple sclerosis. *Arch Neurol Psychiat*, 38:1.1937, figg. 1,2.
110. Raine, Cedric S.: Demyelinating diseases. In Davis, R. L., and Robertson, D. M. (Eds.): *Textbook of Neuropathology*. Baltimore, Williams & Wilkins, 1985, pp. 468-547.
111. Reitan, Haakon: On movements of fluid inside the cerebro-spinal space. *Acta Radiol*, 22:762,1941.
112. Ribbert, Hugo: Ueber multiple Sclerose des Gehirns und Rückenmarks. *Arch Path Anat Physiol Klin Med*, 90:243,1882.
113. Rindfleisch, Eduard: Histologisches Detail zu der grauen Degeneration von Gehirn und Rückenmark (Zugleich ein Beitrag zu der Lehre von der Entstehung und Verwandlung der Zelle). *Arch Path Anat Physiol Klin Med*, 26:474,1863.
114. Rindfleisch, G. E.: *A Manual of Pathological Histology*. London, New Sydenham Society, 1872, Vol. 2, pp. 344-351.
115. Rosenfeld, M.: Endarteriitis bei multipler Sklerose. *Arch Psychiat Nervenheilk*, 38:474,1904.

116. Scheinberg, Labe: Multiple Sclerosis. In Halsey, William D., and Friedman, Emanuel (Eds.): Collier's Encyclopedia with Bibliography and Index. New York, Macmillan, 1985, Vol. 16, p. 698.
117. Scheinker, I. Mark: Neuropathology in its Clinicopathologic Aspects. Springfield/Illinois, Thomas, 1947, fig. 116.
118. Scheinker, I. Mark: Circulatory disturbances and management of multiple sclerosis. Ann New York Acad Sciences, 58:582,1954, fig. 1.
119. Schelling, F.: Do venous refluxes hurt the brain in MS? The fundamental problem. In Gonsette, R. E., and Delmotte, P. (Eds.): Immunological and Clinical Aspects of Multiple Sclerosis. Lancaster, MTP Press, 1984, pp.433-440.
120. Schelling, F.. Damaging venous reflux into the skull or spine: Relevance to multiple sclerosis. Medical Hypotheses, 21:141,1986.
121. Schlesinger, B.: The venous drainage of the brain, with special reference to the Galenic system. Brain, 62:274,1939.
122. Schmaus, Hans: Beiträge zur pathologischen Anatomie der Rückenmarkerschütterung. Arch Path Anat Physiol Klin Med, 122:326,1890.
123. Schüle, Heinrich: Beitrag zur multiplen Sclerose des Gehirns und Rückenmarks. Dtsch Arch Klin Med, 7:259,1870.
124. Schüle, H.: Weiterer Beitrag zur Hirn-Rückenmarks-Sclerose. Dtsch Arch Klin Med, 8:223,1871.
125. Schumacher, George A., Beebe, Gilbert, Kibler, Robert F., Kurland, Leonard T., Kurtzke, John F., McDowell, Fletcher, Nagler, Benedict, Sibley, William A., Tourtellotte, Wallace W., and Willmon, Thomas L.: Problems of experimental trials of therapy in multiple sclerosis: Report by the panel on the evaluation of experimental trials of therapy in multiple sclerosis. Ann New York Acad Sciences, 122:552,1965.
126. Seitelberger F., Jellinger, K., and Tschabitscher H.: Zur Genese der akuten Entmarkungencephalitis. Wiener Klin Wschr, 70:453,1958.
127. Siemerling, E., and Raecke, J.: Beitrag zur Klinik und Pathologie der multiplen Sklerose mit besonderer Berücksichtigung ihrer Pathogenese. Arch Psychiat Nervenkrankh, 53:385,1914, Plate XVI.
128. Sioli: Ein Fall von combinierter Erkrankung der Rückenmarksstränge mit Erkrankung der grauen Substanz. Arch Psychiat Nervenkrankh, 11:693,1881.

129. Smith, Robert R., and Sanford, Robert, A.: Disorders of the deep cerebral veins. In Kapp, John P., Schmidek, Henry H. (Eds.): *The Cerebral Venous System and Its Disorders*. Orlando, Grune & Stratton, 1984, pp. 547-555.
130. Solcher, H.: Perivenöse Enzephalomyelitis. In Doerr, W., Seifert, G., and Uehlinger, E. (Eds.): *Spezielle pathologische Anatomie*. Berlin, Springer, 1988, Vol. 13/III, pp. 148-214.
131. Spatz, Hugo: Über Encephalitis und Encephalitiden. *Nervenarzt*, 4:466,1931.
132. Spielmeyer, W.: Infektion und Nervensystem. *Dtsch Zschr Nervenheilk*, 123:161,1929.
133. Spielmeyer, W.: Vergleichend anatomische Betrachtungen über einige Encephalitiden, insbesondere über den Typus der Impfencephalitis. *Zeitschr Hyg Infektionskrankh*, 113:170,1931.
134. Steiner, Gabriel: Krankheitserreger und Gewebefund bei multipler Sklerose. Vergleichend histologisch-parasitologische Untersuchungen bei multipler Sklerose und anderen Spirochätosen. Berlin, Springer, 1931, pp. 108-120.
135. Steiner, Gabriel: Multiple Sklerose. Ihre Ätiologie, Pathologie, Pathogenese und Therapie. Berlin, Springer, 1962, fig. 4.
136. Strenta-Filstroff, Christiane: Les mouvements du liquide cephalo-rachidien et du sac dural à la lumière de la radiculographie. Marseille, Thèse, 1970.
137. Strümpell, Adolf: Ueber eine bestimmte Form der primären kombinierten Systemerkrankungen des Rückenmarks, im Anschluss an einen Fall von spastischer Spinalparalyse mit vorherrschender Degeneration der Pyramidenbahnen und geringerer Beteiligung der Kleinhirn-Seitenstrangbahnen und der Goll'schen Stränge. *Arch Psychiat Nervenheilk*, 17:217,1886.
138. Symonds, C. P.: The pathological anatomy of disseminated sclerosis. *Brain*, 47:36,1924.
139. Thoma, Richard: Die Ueberwanderung farbloser Blutkörper von dem Blut- in das Lymphgefäßsystem. Heidelberg, Habilitation Thesis, 1873.
140. Thron, Armin, K.: *Vascular Anatomy of the Spinal Cord. Neuroradiological Investigations and Clinical Syndromes*. Wien, Springer, 1988.
141. Türck, Ludwig: Über Kompression und Ursprung der Sehnerven. *Sitzungsber Kaiserl Akad Wissensch Math Naturwissensch Classe*, IX:229,1852.
142. Türck, Ludwig: Über sekundäre Erkrankung einzelner Rückenmarksstränge und ihrer Fortsetzungen zum Gehirne. *Zschr KK Gesellsch Ärzte Wien*, IX/2:289,1853.
143. Türck, Ludwig: Mitteilungen über Krankheiten der Gehirnnerven. *Zschr KK Ges Ärzte Wien*, XI:517,1855.

144. Turnbull, Hubert M., and McIntosh, James: Encephalo-myelitis following vaccination. Brit J Exp Pathol, 7:181,1926.
145. Uchimura, I., and Shiraki, H.: A contribution to the classification and the pathogenesis of demyelinating encephalomyelitis. With special reference to the central nervous system lesions caused by preventive inoculation against rabies. J Neuropath Exp Neurol, 16:139,1957.
146. Ule, Günther: Nervensystem. In Doerr, Wilhelm (Ed.): Organpathologie. Stuttgart, Thieme, 1974, Vol. III, pp. (9-1)-(9-92).
147. Valentiner, Wilh.: Ueber die Sclerose des Gehirns und Rückenmarks. Dtsch Klinik 14:147/15:158/16:167, 1856.
148. Van Bogaert, Ludo: Histopathologische Studie über die Encephalitis nach Windpocken (Encephalitis postvaricellosa). Zschr Ges Neurol Psychiat 140:201,1932.
149. Vuia, O.: Intracerebral angioarchitectonic venous territories (Their role in venous draining of brain under normal and pathologic conditions). Rev Roum Neurol, 3:235,1966.
150. Vuia, O.: Necrotic leucoencephalopathy of venous origin. Psychiat Neurol Neurochir, 71:281,1968.
151. Vuia, O., and Alexianu, M.: Insufficance veineuse du cerveau. Ramolissement et hémorragie cérébrale d'origine veineuse. J Neurol Sci, 7:495,1968.
152. Vulpian: Note sur la sclérose en plaques de la moelle épinière. Bull Mém Soc Méd Hôp Paris, 3:75,1866.
153. Wakefield, C. L., and Eidelberg, E.: Electron microscopic observations of the delayed effects of spinal cord compression. Exp Neurol, 48: 637, 1975.
154. Waksman, B. H., and Reynolds, W. E.: Multiple sclerosis, a disease of immune regulation. Proc Soc Exp Biol Med, 175:282,1984.
155. Walthard, Karl M.: Spätstadium einer "Encephalitis" nach Masern. Bemerkungen zur Histologie und Pathogenese. Zschr ges Neurol Psychiat 124:176,1930.
156. Wechselmann, Wilhelm, and Bielschowsky, Max: Thrombose der Vena Galeni als Grundlage von Salvarsantodesfällen. Dermatol Wschr, 69:763,1919.
157. Werner, W.: Perivenöse Enzephalomyelitis und multiple Sklerose. Med Klin, 64:1924,1969.
158. Wernicke, C.: Lehrbuch der Gehirnkrankheiten für Ärzte und Studierende. Berlin, Fischer, 1883, Vol. III, pp. 424-482.

159. Westphal, C.: Rückenmarkserkrankungen. Die fleckweise oder disseminierte Myelitis. Arch Psychiat Nervenkr, 4:338,1874, Plates VI,VII.
160. Westphal, C.: Ueber kombinierte (primäre) Erkrankung der Rückenmarksstränge. Arch Psychiat Nervenkrankh, IX:413,1879.
161. Wilson, Edward T.: A case of disseminated insular sclerosis. Brit Med J, ii:675,1876.
162. Wohlwill, Friedrich: Über Encephalomyelitis bei Masern. Zschr ges Neurol Psychiat, 112:20,1928.
163. Yates, P.O.: Vascular disease of the central nervous system. In Blackwood, W., and Corsellis, I. A. N. (Eds.): Greenfield's Neuropathology, 3rd ed. London, Arnold, 1976, pp. 86-147.
164. Youngchaiyud, Uriwan, Coates, Alan S., Whittingham, Senga, and Mackay, Ian R.: Cellular-immune response to myelin protein: Absence in multiple sclerosis and presence in cerebrovascular accidents. Austral N Z J Med, 4:535,1974.
165. Zedler, Johann Heinrich (Ed.): Grosses vollständiges Universal-Lexikon aller Wissenschaften und Künste welche bishero durch menschlichen Verstand und Witz erfunden und verbessert worden. Leipzig, Zedler, 1742, Vol. 32, pp. 1095-1097; reprint Graz, Akademische Druck- und Verlagsanstalt, 1961.

Overview of Plates

Plate I. Carswell's "peculiar diseased state of the spinal cord and pons", and his "remarkable lesion of the spinal cord". This earliest illustration of a specific anatomical pathological spinal cord finding, drawn in 1830 and published in 1838 by Sir Robert Carswell, is commonly celebrated as the first documentation of the existence of multiple sclerosis.

Plate II. Cruveilhier's "four cases of grey degeneration of the columns of the spinal cord, by way of a reddish or grey [tissue] transformation in the form of 'islands'".

The four specimens displayed actually represent four essentially different kinds of lesions, put together by Jean Cruveilhier in 1839. Only the first specifically corresponds to Carswell's "peculiar diseased state".

Plate III. Cruveilhier's "new example of degeneration or grey transformation [of the spinal cord in the form of patches]". This unique 1841 illustration by Jean Cruveilhier of an entire spinal cord affected by damages once more reflects the specifics of Carswell's "peculiar diseased state".

Plate IV. Charcot's first illustration of multiple sclerosis affecting the cerebral hemispheres in a specific way. The co-existence, in one and the same victim, of the specific findings of Carswell's "peculiar diseased state" with an equally peculiar form of damage affecting the cerebral hemispheres was demonstrated for the first time, in 1867, in this drawing by Jean-Martin Charcot, presented in Leopold Ordenstein's thesis.

Plate V. Charcot's "sclerosed plaques occupying the corpus callosum." This oldest illustration of the distinctive lesion-waves arising from the undersurface of the corpus callosum, presented in Charcot's 1884 "Lectures", showed the pattern of distribution of the entire damage to one cerebral hemisphere in a victim of multiple sclerosis.

Plate VI. Siemerling and Raecke's "plaques in corpus callosum, cerebral white matter and cortex". The plaques' distinctive spread pattern inside the cerebral hemisphere of a victim of multiple sclerosis was disclosed for the first time in this 1914 illustration by Ernst Siemerling and Julius Raecke.

Plate VII. Putnam and Adler's multiple sclerosis observation. This drawing summarizes the remarkable results of Tracy Putnam and Alexandra Adler's pioneering 1937 work on the unique form of vein-dependence characterizing the spread of the cerebral plaques in a specimen of multiple sclerosis.

Plate VIII. Keyhole view of multiple sclerosis: Fragmentary pieces of evidence.

Fig. A. Scheinker's "Perivenous plaque formation". Mark Scheinker's illustrations, from 1947 and 1954, show a plaque bursting forth to the one side of a vein – a particularly revealing finding.

Fig. B. Steiner's "foci of [spinal cord] demyelination". Beside a lesion centering upon the posterior median septum of the spinal cord, already noted by Gabriel Steiner in his presentation of 1962, the rugged pattern of the damages to the spinal cord's sides deserves attention.

Plate IX. Frommann's "grey degeneration of the spinal cord." These precise 1867 microscopic observations by Carl Frommann make plain that the specific affection of the spinal cord's flanks in classic specimens of multiple sclerosis typically advances in the form of a primary, gradually advancing scarring process.

Plate X. Lauenstein's "acute myelitis." Unique since 1877, this observation by Carl Lauenstein proves that the specific flank affection of the spinal cord can also show an acute evolution and express itself as tissue softening.

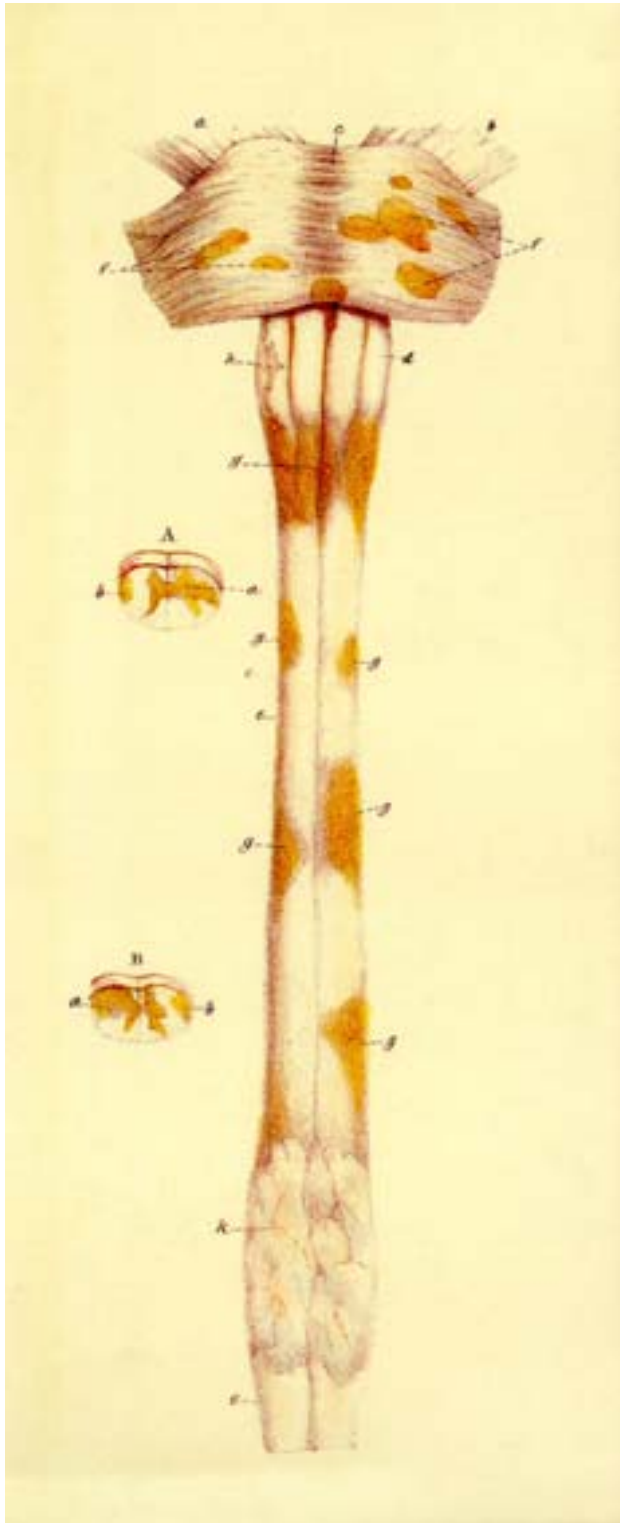
Plate XI. Carswell's earliest depiction of a deep, periventricular, intracerebral lesion, spreading in conformity to the obstructed arteries' area of supply. The possibility of explaining a cerebral vascular lesion's cause directly from its pattern of distribution seems to have been indicated for the first time in this 1838 drawing by Sir Robert Carswell.

Plate XII. Eichhorst's characterization of multifocal myelitis. These 1913 pictures by Hermann Eichhorst demonstrate the pattern of so-called random scattering of "inflammatory foci" due to a widespread involvement of the terminal vascular bed, i.e. the tiniest blood vessels. The difference from the lesion pattern of Carswell's "peculiar diseased state" is obvious.

Plate XIII. Oppenheim and Cassirer's multifocal encephalitis. Hermann Oppenheim and Richard Cassirer's 1907 figures demonstrate that, also in the brain, the emergence of the specific, directly vein-dependent lesion formations of multiple sclerosis and the development of "inflammatory lesions" are not the same and that the two kinds of lesion must accordingly be due to essentially different forms of injurious events.

Plate XIV. Individual venous dispositions which explain the emergence of "Dawson's-fingers" or Carswell's "remarkable spinal cord lesion". By showing the individual concurrence of some long-known venous variations and anomalies, these figures, drawn by the present author, explain the emergence of the specific lesion formations of multiple sclerosis.

Plate I: Carswell's "Peculiar Diseased State"



Carswell's "**peculiar diseased state of the spinal cord and pons**", with its "**remarkable lesion of the spinal cord**".

Main figure. Cervical spinal cord and pons, *anterior aspect* (a, right, and b, left cerebral peduncle; c, pons; d, spinal bulb; e, spinal cord; f, "**points of the pons**"; g, "**patches on the spinal cord**"; h, partial atrophy of right olive; k, softening of the spinal cord's cervical enlargement).

Fig. A, B. *Transverse cervical spinal cord sections* showing that "**the discoloration commences on the surface of the white, and extends inwards to the grey substance**" (a, lesion extension to central grey matter; b, involvement of white matter periphery only).


Significance of the Document:

This picture, commonly quoted as representing the archetypal evidence on the existence of multiple sclerosis, for the first time demonstrated the distinctive pattern of lesions involving selectively the spinal cord's flanks. Two different, laterally superimposed, kinds of tissue changes can be discerned. The comparable damages to the pons show a clearly different configuration -a fact which has as yet been paid little attention to.

Unique: The cornered, paired scars extending far along, and distinctly less so

circumferentially, into the spinal cord's flanks; between the scars' uppermost pair, a similar patch atop the decussation of pyramids; in addition, comparable, yet explicitly rounded lesions in the pons' anterior front.

Plate II: Cruveilhier's "Four Cases of Grey Degeneration"



Cruveilhier's "four cases of grey degeneration of the columns of the spinal cord, by way of a reddish (T.R) or grey (T.G.) [tissue] transformation in the form of 'islands'" (O.D. right -, and O.G. left olive; label C.R. not explained).

The Basic Error: The lesions of figg. 1, 1' were considered to represent the same changes – and were accordingly referred to in the same terms - as the totally different lesions illustrated in figg. 2, 3 and 4.

Proper Lesion-Specifications:

Figg. 1, 1': Only this cervical cord shows the specific lesion pattern of **Carswell's "peculiar diseased state"**, i.e. three **paired scars encroaching on, and more or less deeply into, the spinal cord's flanks.**


Fig. 2: This specimen shows **smoothly demarcated swellings, all following the spinal cord's posterior midline**, as they occur as focal inflammatory reactions to diverse systemically spread injurious agents. The spinal cord's flanks appear spared throughout.

Fig. 3: The **continuous affection of the two posterior nerve tracts** represents the classic late effects of syphilis. The spinal cord's lateral columns are completely unaffected.

Fig. 4: Here, a large, confluent area of a **smoothly delineated, superficial inflammatory infiltration** has occupied most of the spinal cord's front so that separate plaques are only to be discerned at the spinal cord's upper and lower ends, as well as in the pons. Moreover, the spinal cord appears distorted by a scar halfway up its length, and the pons is beset with tuberculomas. All these findings point to a repeated seeding of tubercle bacilli in the spinal subarachnoid space. Also here the spinal flanks are not specifically involved.

Significance of the documentation: In lumping together all the plate's lesions under the same terms, Cruveilhier's report initiated a lasting, widespread failure to properly evaluate the specific pathology of Carswell's "peculiar diseased state".

Plate III: Cruveilhier's "New Example of Degeneration"

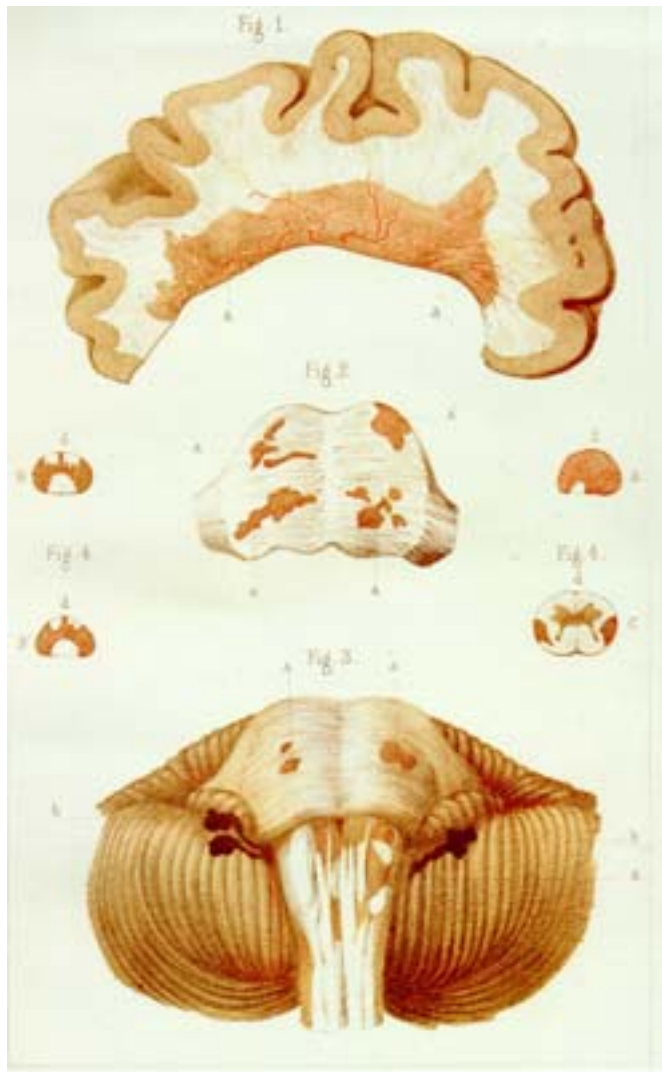


Cruveilhier's "new example of degeneration or grey transformation [in the spinal cord in the form of patches]".

Specific Findings: In the region of the cervical enlargement, lengthy bilateral scarring of the spinal cord's flanks (T.T, i.e. "taches"); similar, distinctly smaller scars lining fissures on the spinal cord's front (Fig. 1, F.A. – anterior view) and backside (Fig. 1', F.P. - posterior view), where certain areas following the spinal cord's posterior midline are particularly extensively involved. A section across the upper spinal cord (Fig. 1") demonstrates the lateral and posterior spinal damages' propagation in the form of bizarre wedges. The pons, affected by "the same grey degeneration", shows more compact lesions, exhibiting a multi-centric pattern of spread.

Significance: Cruveilhier depicted and described for the first time **the preferential lesion-alignment along both the spinal cord's flanks and hindmost parts**. But the finding's specificity and its specific conformity to the lesions of both Cruveilhier's first case of "grey degeneration of the spinal cord" and Carswell's "peculiar diseased state" were not realized. In displaying a specifically affected spinal cord in its entirety, however, this picture has remained unique.

Plate IV: Charcot's First Illustration of Multiple Sclerosis



Charcot's first illustration of multiple sclerosis affecting the cerebral hemispheres in a specific way:

Fig. 1, a-a, "Sclerosed plaque affecting the [upper] wall of the lateral [cerebral] ventricle" - projecting, in places, one centimeter off the ventricular border.

Fig. 2, a, a, "Sclerosed nuclei", exposed by slicing the pons parallel to its anterior front. The picture shows the multi-centric lesion expansions at the depth of the pons (cf. Fig. 2, a, a; Plate II, fig. 1, T.R).

Fig. 3. a, a, "Sclerosed plaques of pons and spinal bulb"; b, b, "ependyma" (covering membrane) of the brain's fourth ventricle.

Fig. 4, Spinal cord cross-sections (d, the cord's front) : A, above cervical enlargement; B, B', at middle; C, 3 centimeters over lower end.

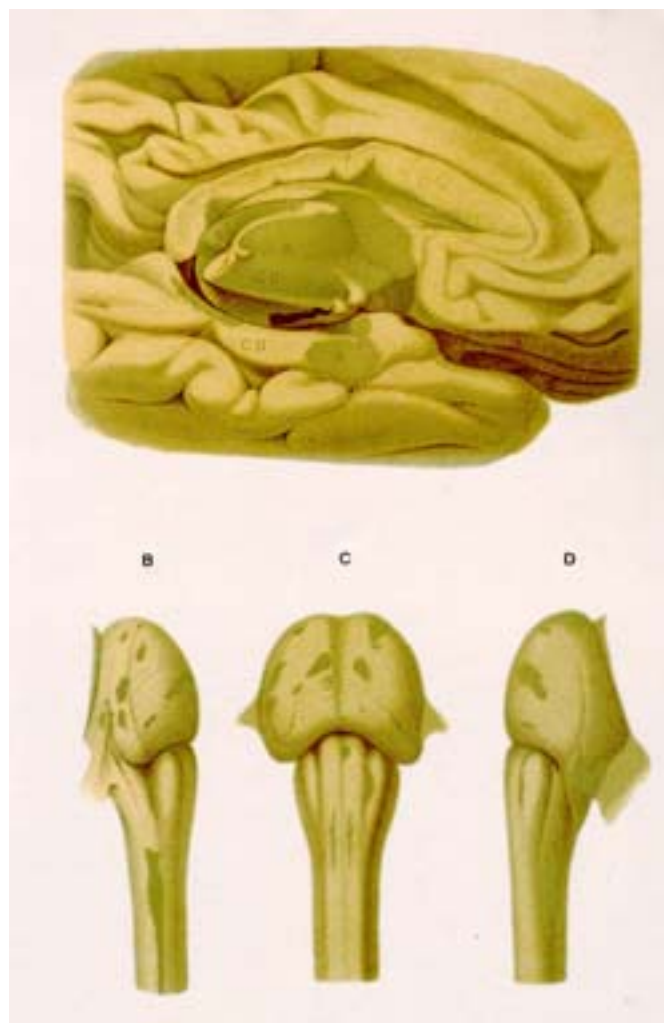Specific Lesion Features: Displayed first, **in the ventricular wall, a massive lesion can be seen to undulate outwards into the cerebral hemisphere; it embeds major venous blood vessels, apparently attended by uneven widenings of their perivascular spaces.**

According to the verbal description, **the spinal cord lesions extended everywhere primarily, and, in the lumbar section exclusively, into the organ's lateral flanks.**

Figs. 3 and 4 are representative of the specific involvement of, above all, the spinal cord's flanks. The lateral lesion wedges partly interconnect (fig. 4; B, B') and appear turned backwards (fig. 4: C, left side; cf. Plate I, fig. B, right side; Plate III, fig. 1'', left side).

Significance: This plate was the first to display specific ventricle-based lesion expansions into the cerebral hemispheres. In addition, it offers a unique synopsis of the specific post-mortem findings of multiple sclerosis of brain and spinal cord.

Plate V: Charcot's "Sclerosed Plaques Occupying the Corpus Callosum"



Charcot's "Sclerosed plaques occupying the corpus callosum"

shown, side by side, with classic brainstem and spinal cord findings.

Fig. A. Left cerebral hemisphere, medial aspect. "Sclerosed plaques occupying the corpus callosum" and other parts (a, a) of the ventricle wall (CC, Corpus callosum; CH, hippocampal gyrus; CO, thalamus).

Fig. B, C, D. "Sclerosed plaques" on spinal bulb and pons (dark, olive-green areas), as seen from the right side (B), left side (D), and anteriorly (C).

Distinctive pathological findings:

Fig. A. The section severing the two cerebral hemispheres shows **a series of partly peaked, partly rounded lesions, coherently surging up, like a wave, off of the undersurface into the substance of the corpus**

callosum. Cerebral cortex and paraventricular nuclei (grey matter compartments!) have not been spared.

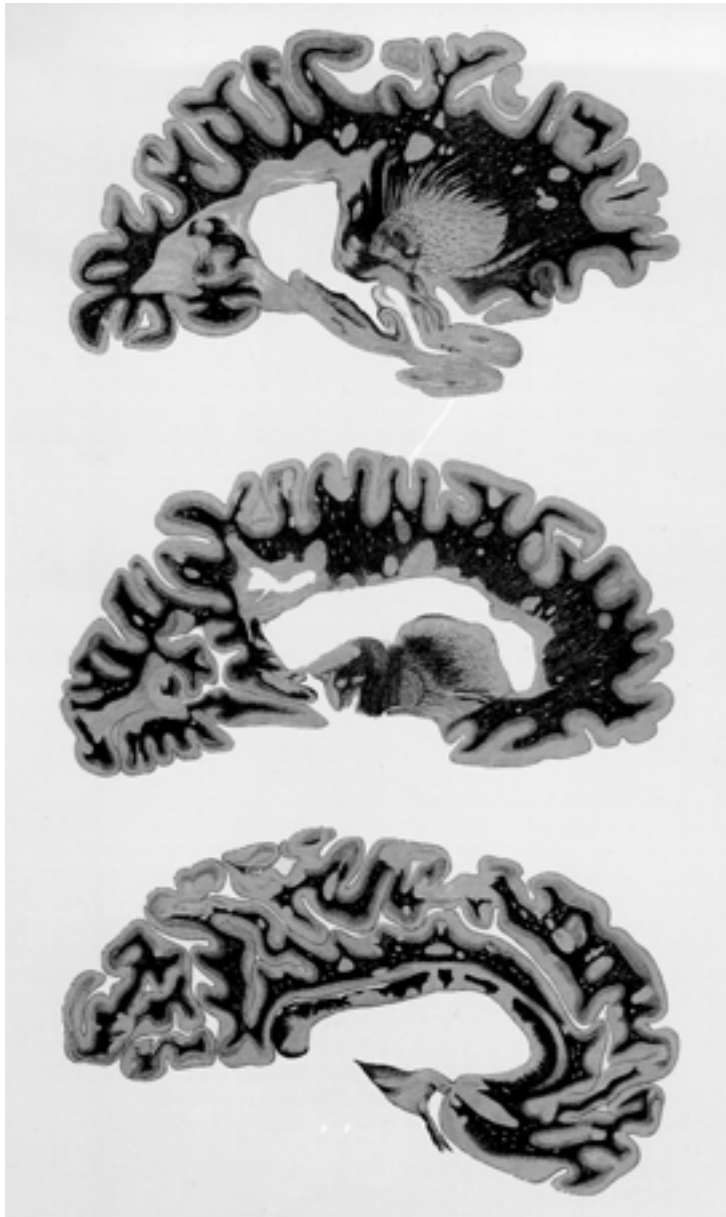
Significance:

Fig. A: This is the first illustration, peculiar to the specific instances of multiple sclerosis, of this singular form of lesion spread into the corpus callosum. The periventricular changes as a whole are here also seen to have emerged in exact conformity to the pattern of the central affluents of the straight sinus.

Fig. B and D focus on **the abrupt upper ending of the specific scarring of the spinal cord flanks in the form of a right and a left, thin, lengthwise extended lesion streak** (c.f. Plate I; Plate II, fig. 1; and especially Plate IV, fig. 3).

Fig. C shows a similar lesion streak on the lower part of the right and left pyramids, running along its anterior contour.

Plate VI: Siemerling and Raecke's "Plaques in Cerebral White Matter and Cortex"



Siemerling and Raecke's "plaques in the corpus callosum, cerebral white matter and cortex": These three paramedian sections through an entire cerebral hemisphere illustrate the specific pattern of spread of "extensive plaques, strongly involving, even going through, the corpus callosum" (lower figure) and "other plaques which affect both the cerebral white matter and cortex".

Otherwise, mere mention is made of the fact that spinal cord, brain stem, cerebellum, and optical nerves were also involved at all levels.

Significance:

This plate for the first time illustrated an emergence of **specific, apparently independent plaques in the periphery of the cerebrum**; the gradual peripheral detachment of

these lesions and the fact that the broad, mostly interconnected lesion zones abutting on the cerebral ventricles were the most scarred provide testimony to the specific plaques' outwardly directed spread. It is for this reason, and not for its minor myelin content, that the cerebral cortex may remain spared.

Special Lesion Characteristics:

Basally widely interconnected, the generally fairly compact lesions are seen to project off of the ventricular border into both corpus callosum and the entire cerebral hemisphere. The more peripheral lesions appear more or less detached and freely scattered into the white and sometimes also the grey matter of the cerebrum. Plaques in contact with the cortex preferably exhibit a striking peripheral flattening.

Plate VII: Putnam and Adler's Multiple Sclerosis



Putnam and Adler's multiple sclerosis observation:

General Lesion Description:

The lateral ventricles were lined with scar tissue in which lay large veins, many surrounded by blood pigment. The scarred tissue followed the radial veins for a variable distance and patches of scarring were found at intervals along these veins.

Comments on the Illustration:

A large, dilated vein leading toward the cortex was surrounded by a sleeve of plaque; separate plaques surrounded the larger vein trunks at intervals. Particularly striking was the tortuous, congested contour of the plaques' main veins (veins given in black; lesions in a darker grey, venous thrombus in a lighter grey; V, ventricle).

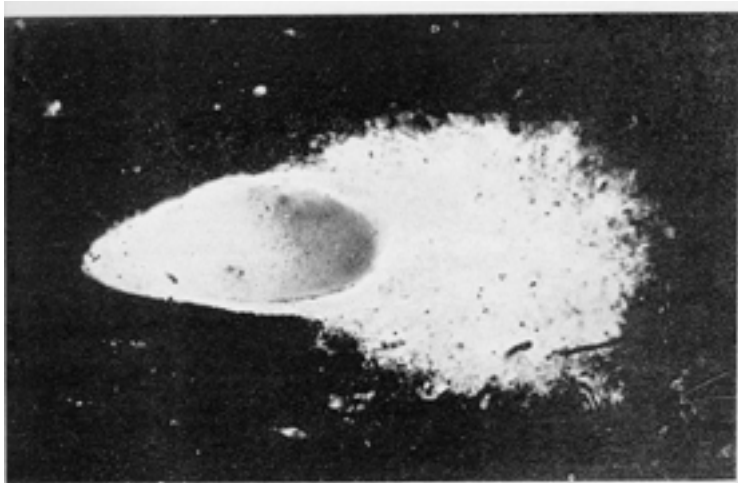
Documentary Significance:

By tracing the cerebral lesions' vascular relationships in a case of multiple sclerosis, striking observations were made of grossly distorted and distended veins. It was these veins coursing ventricle-wards from which the individual lesions were found to have emerged. According to the pattern of tissue scarring, the lesion veins also had to be considered as pathways for the process' progressive advance into the periphery of the cerebrum.

Lesion Specification:

The basal lesion, a "Dawson's finger", rises like a cone off of the ventricular border (V), wrapping itself around a large vein draining into another vein running along the lateral cerebral ventricle. The radial lesion vein shows massive, outwardly increasing distensions. Its grotesquely distorted main affluent, clogged by a thrombus (T), forms the point of exit of two "Steiner's splashes", i.e. isolated cerebral plaques. Another plaque, close to the ventricle, straddles a small venous trifurcation.

Plate VIII: Scheinker's "Perivenous Plaque", Steiner's "Foci of Demyelination"



Keyhole view of multiple sclerosis: Fragmentary pieces of evidence.

Fig. A. Scheinker's "Perivenous plaque formation", appearing as an "area of myelin loss in the vicinity of a distended ... blood vessel":

Lesion Specifics: Particularly striking is the tissue destruction's bursting forth to the one side of the lesion vein.

Documentary Significance: This is a lucid illustration of the dynamics of the vein-dependent lesion formation (observed in the brain).

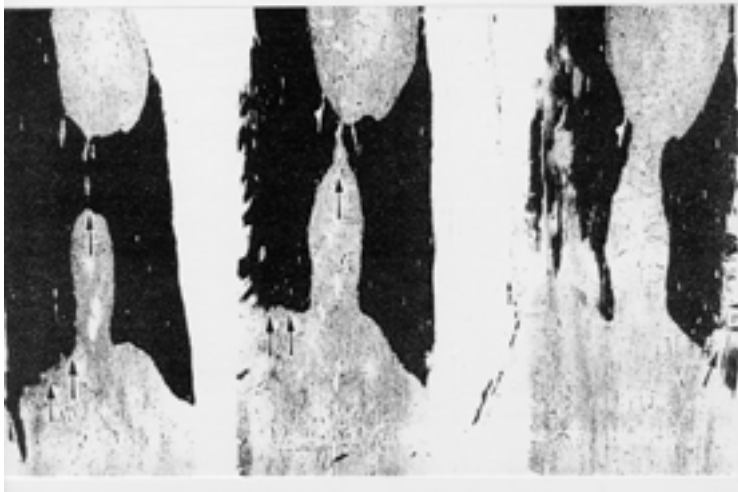


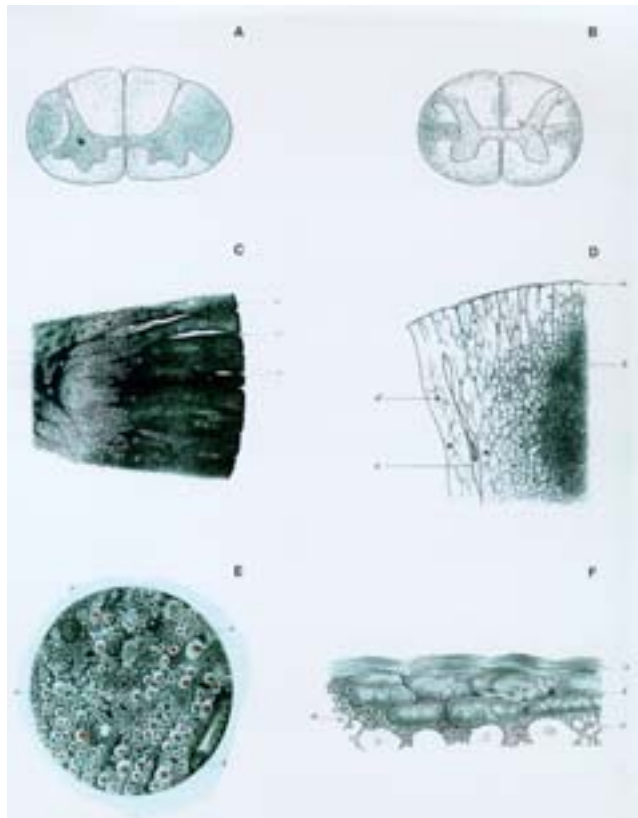
Fig. B. Steiner's p.-a. series of three frontal sections through the lower thoracic cord, picturing

"the union of an upper and lower (lesion) focus by a bridge of demyelinated tissue, emerging from the posterior median septum" and "smaller, irregular **foci of demyelination**" to the cord's sides.

Specifics of Fig. B: The larger lesion's closeness to the posterior median septum is important. But what seems more revealing are the saw-toothed damages to the second section's left side, and the rhomboid or flame-shaped lesions on the third section's right and left sides.

Significance of Fig. B: The serrated and crenelated lesion patterns to the spinal cord's sides contradict their attribution to a random spread of blood vessel-related damages. Such lesion forms typically result from certain mechanical forces, i.e. tensile impacts.

Plate IX: Frommann's "Grey Degeneration"



Frommann's "grey degeneration of the spinal cord":

Fig. A, B. Spinal cord, cross-sections through its cervical (A) and lumbar (B) enlargements: The figures show the pattern of the scars encroaching upon the spinal cord's flanks (the darkness of the shading reflects the intensity of the tissue changes).

Specifics: The scarring of the spinal cord's sides forms an outwardly based wedge. It involves the grey matter as well (fig. A, on the left). Another lance-shaped lesion embraces the posterior median septum of the cord (fig. B).

Fig. C, D. Stronger magnification. The changes spread along normal fibrous structures in the form of a progressive broadening (a, fibrous cover of the cord; a', broad tissue clefts running along blood vessels; b, tight scar of the lesion core; c, tissue cleft outside the lesion proper; d, d', blood vessels.)

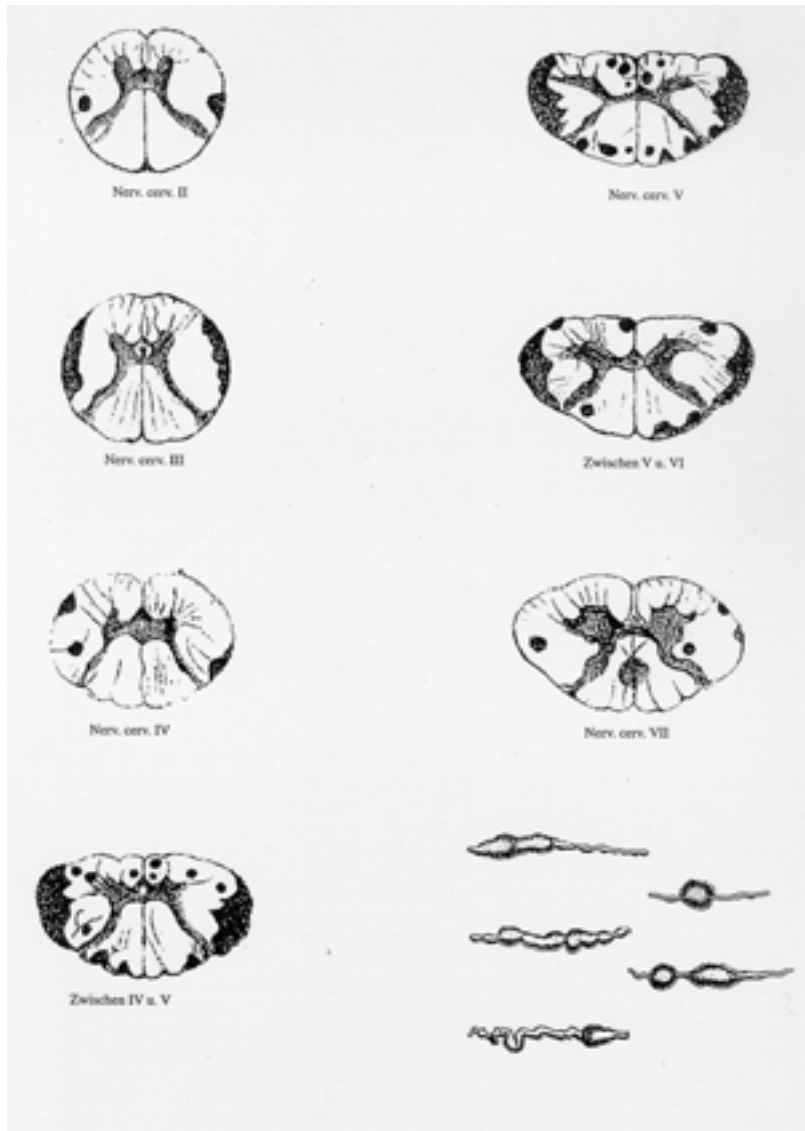
Fig. E, F. Microscopical findings (lesion spread from above downwards). **Fig. E.** Lesion edge. Broadened fibrous structures (a, a) and thickened vessel walls (b) prevail everywhere; with the disappearance of nerve fibers, defects in the fibrous meshwork also become evident. **Fig. F.** Spinal cord surface: a, fibrous cover; b, clumped tissue; c, decaying fibrous meshworks; d, swollen axons, one lacking its myelin sheath.

Crucial Findings:

The wedge-shaped flank affections of the cord spread consistently inwards and eventually involve the central grey matter. They consist of a progressive broadening of the concerned fibrous structures, ending in a replacement of the nerve fibers. But this tough scar tissue proves prone to degenerative changes, occurring even in the presence of nerve fibers and myelin sheaths. The thickened blood vessels show, along their insertion into the spinal cord's sides, a striking tendency to separate themselves from both normal and scarred tissue by way of gaping perivascular tissue clefts.

Conceptual relevance: According to these findings, multiple sclerosis was a "primary sclerosis".

Plate X: Lauenstein's "Acute Myelitis"



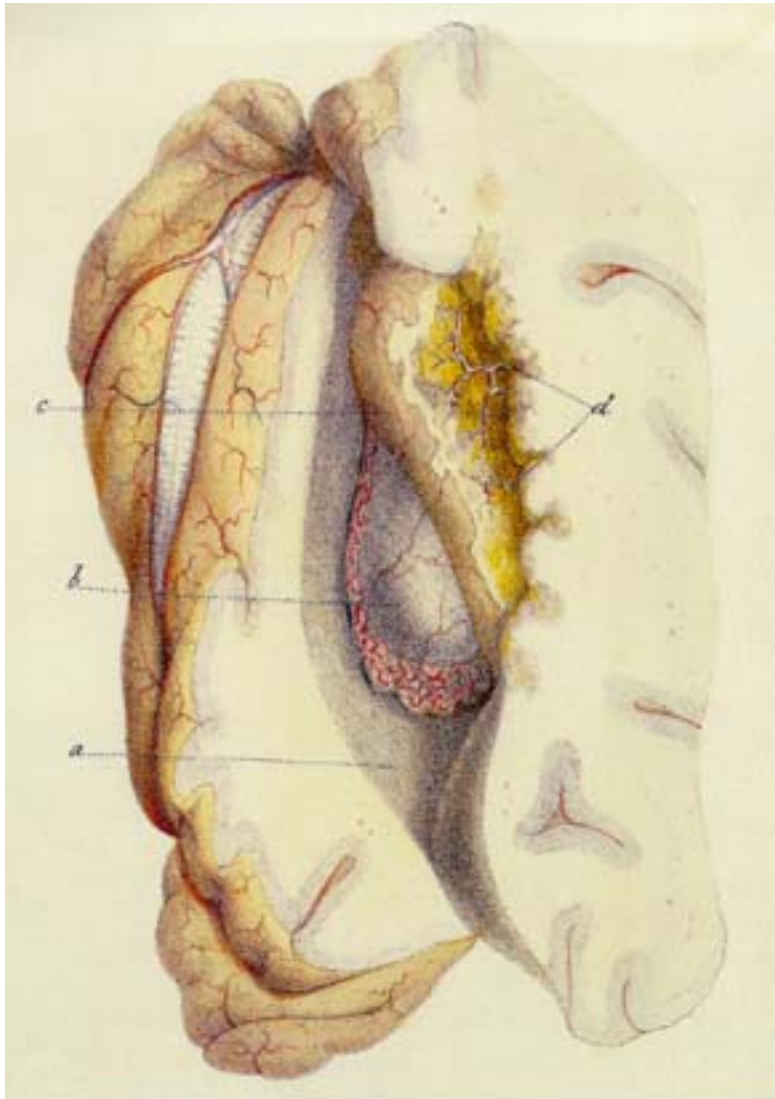
Lauenstein's "Acute Myelitis":

From the fourth to the sixth cervical segment, the spinal cord's flanks prove to be evenly affected, on either side to the same extent, by a well demarcated zone of a massive tissue softening (shown in black). From here the damage tapers off, cranially to the second and caudally to the seventh cervical segment, where a lance-shaped region embracing the spinal cord's posterior septum appears equally affected. The plate's lower right hand corner shows the highly uneven axon swellings and distortions which characterize the lesions' microscopical picture.

Lesion Nature: The pathological changes appear specifically defined by their continuous encroachments, in the form of symmetrical, as a whole coarsely boat-shaped and inwardly jagged lesion extensions upon the cervical spinal cord's flanks.

Significance of the Observation: This account apparently constitutes the only report on a spontaneous softening exhibiting the pattern of Carswell's "remarkable spinal cord lesion", or spinal multiple sclerosis.

Plate XI: Carswell's Earliest Depiction of an Arterial Infarction of the Brain



Carswell's earliest depiction of a deep, periventricular, intracerebral lesion, spread in conformity to the obstructed arteries' area of supply:

Softening inside a cerebral hemisphere from arterial obstruction (a, lateral ventricle laid open; b, thalamus; c, corpus striatum, corresponding to the obliterated arteries' (d,d) areas of supply converted into a soft pulp).

Differentiation from Multiple Sclerosis:

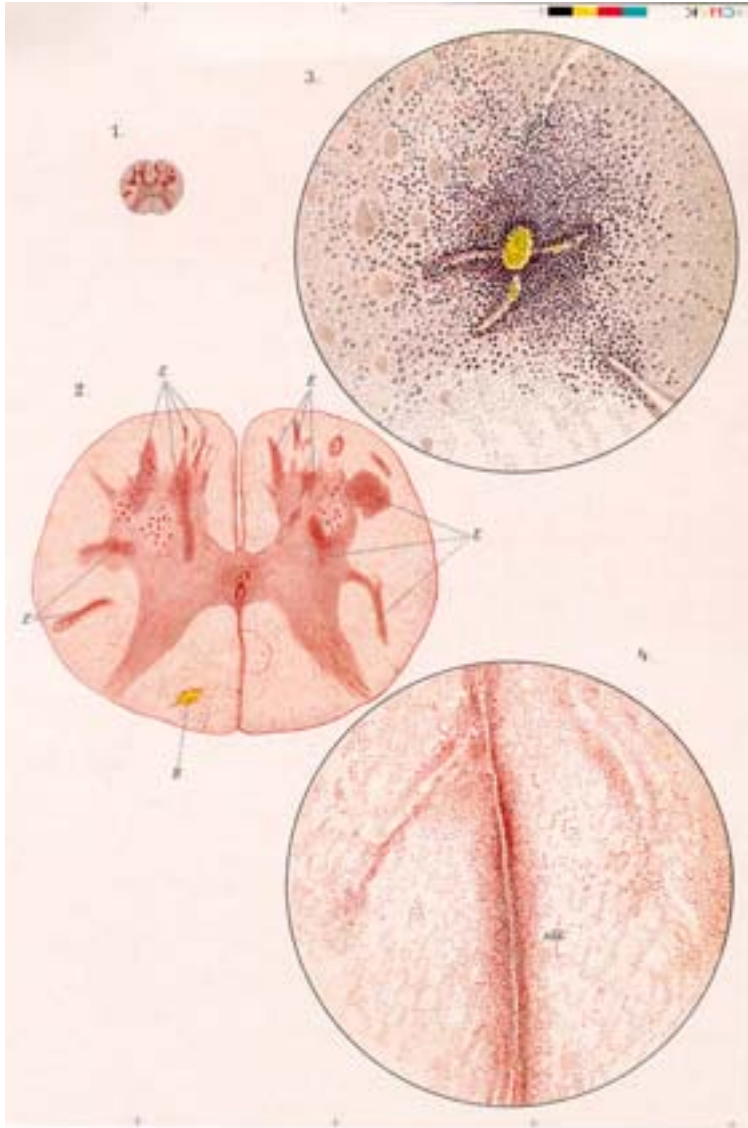
In keeping with the local arteries' domains of ramification, and contrary to the surging up of "Dawson's fingers" directly off of the ventricular border, periventricular lesions caused

by arterial obstruction characteristically either bluntly abut onto, or end at a certain distance from, the cerebral ventricles.

Historical Relevance:

This drawing inaugurated a progressive refinement in the delimitation of different cerebral (and spinal) vascular territories and of the corresponding cerebral (and spinal) lesion patterns, thus paving the way to a clearer discrimination and understanding of the genesis of the diverse vessel-related damages to brain and spinal cord.

Plate XII: Eichhorst's "Inflammatory Foci"



Eichhorst's Characterization of Multifocal Myelitis in a case of infection by smallpox virus.

Fig. 1,2. Spinal cord cross-sections at weak and stronger magnifications: The lesions appear as densely dotted points and stripes, infiltrates of mostly mononuclear white and red blood cells (fig. 2. E, E); fig. 2, B, slight bleeding.

Fig. 3,4: Microscopically, the cellular infiltrates spread consistently along minute blood vessels (fig. 4, sld, "inflammatory infiltrate" seaming a blood vessel of the spinal cord's posterior median septum).

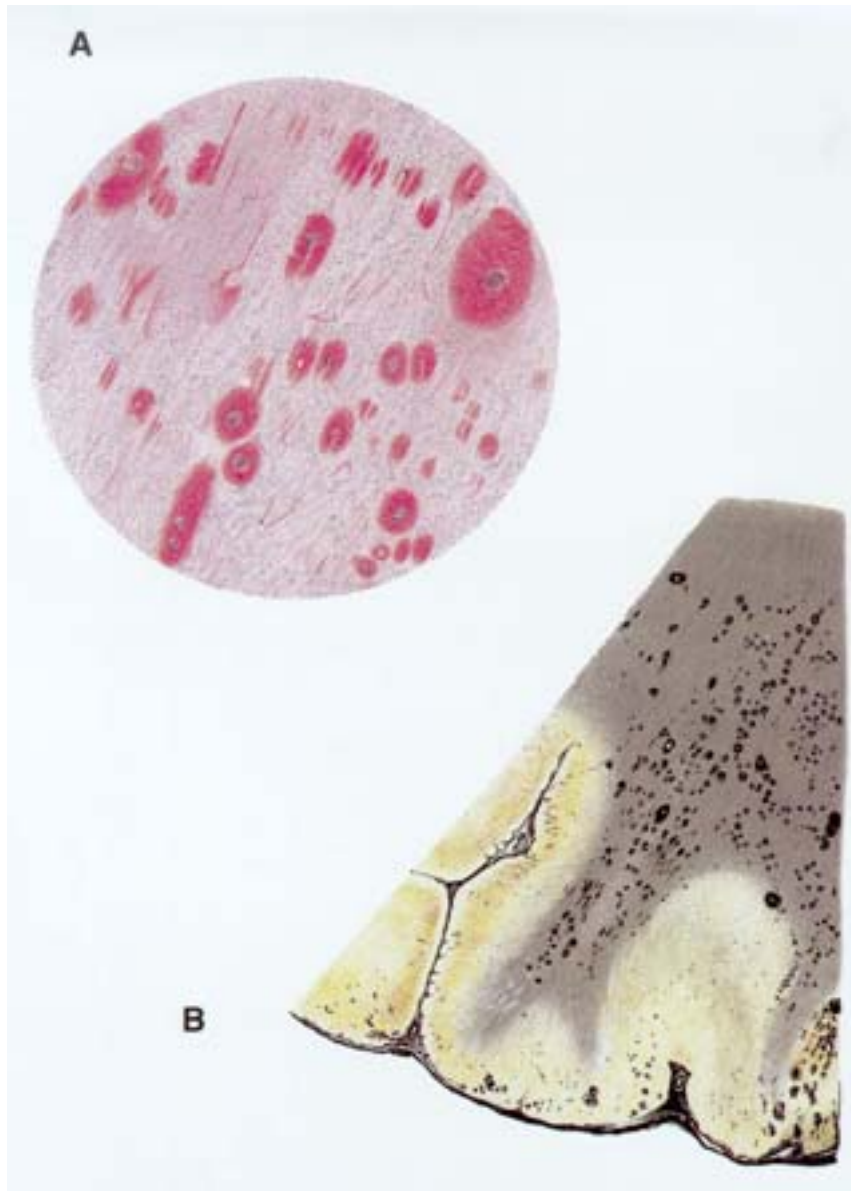
Lesion Characteristics:

Although macroscopically indiscernible, microscopically the spinal cord shows an abundance of up to millet-seed size,

"inflammatory" lesions spread throughout especially its central grey matter. Such lesions also appear in certain parts of the white matter. Most of them relate to foci in the central grey matter – few lying entirely in the white matter, and even fewer reaching its outer covering. Overall, the lesions are so irregularly scattered that their pattern of spread is, even on closely adjacent cord cross-sections, hardly ever comparable.

Relevance of the Documentation: This was not the first illustration of a "disseminated myelitis", i.e. multifocal "inflammatory" spinal cord injury originating in a blood-borne agent's dispersion into the spinal cord. But Eichhorst provided a particularly apt characterization of this affection. In the aforementioned documentations on multiple sclerosis of the spinal cord, a comparable scattering of originally perivascular "inflammatory lesions" was never observed - either in the classic flank affections, or along the posterior septum, or otherwise.

Plate XIII: Oppenheim and Cassirer's Multifocal Encephalitis



Oppenheim and Cassirer's **Multifocal Encephalitis:**

Fig. A. (Hemorrhagic) white matter foci at microscopic magnification. The vascular origin of the "dot-shaped" and streaky "inflammatory foci" is obvious.

Fig. B. The "inflammatory foci's" pattern of spread in cerebral cortex and subcortical white matter at weak magnification.

Lesion Character:

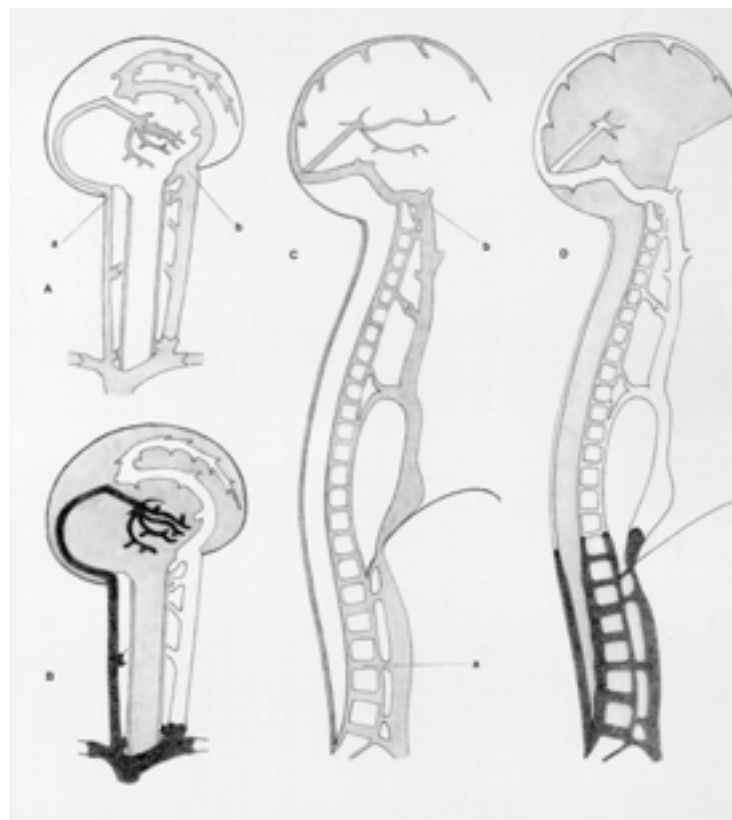
The damages to cerebrum and cerebral white matter appear to be mainly subcortical. In both the white and the less patently affected cortical grey matter, the

"inflammatory foci" have spread according to a random involvement of minor blood vessels. The lesion evolution through intensified effusions from transitional vessels is obvious. Massive, directed lesion expansions from veins are not apparent.

Significance of the Evidence:

The authors pointed out that larger "encephalitic lesions" may originate in a confluence of small "inflammatory foci". Such aggregate lesions are to be recognized from an increasingly dense clustering of perivascular infiltrates at their periphery. Thus the large "encephalitic" lesions are seen to develop in a principally different way from the Dawson's fingers of multiple sclerosis.

Plate XIV: Venous Predisposition to the Emergence of “Dawson’s Fingers” and of Carswell’s “Remarkable Spinal Cord Lesion”



Individual venous dispositions which explain the emergence of “Dawson’s-fingers” (Figg. A,B) or “Carswell’s remarkable spinal cord lesion” (Figg. C,D).

Ominous patterns of spread of the occasionally fast, high rises in central vein pressure (in black), spaces in which low basis pressures prevail in grey, veins allowing the compensatory escape of blood from the craniovertebral space in white.

Fig. A, predispositions to venous back-jets into brainstem and periventricular cerebral veins: a, a narrow and strictly

confined pathway of regurgitation along an internal jugular vein not guarded by a competent venous valve; **b**, opportunities for a compensatory venting of blood from other veins of the cranial cavity, particularly via the contralateral internal jugular vein.

Fig. B. Path of venous backjets into central cerebral veins (in black); leeway for volume-shifts inside the craniovertebral space, allowing for the intracerebral vein expansions (in grey); path for the compensatory venting of the craniovertebral space by an intensified escape of blood from, above all, separate cerebral venous drainages (in white).

Fig. C. Individual predisposition to gross backjets from abdominal veins into the veins cushioning the lowest part of the spinal dural sac: a, extreme widening of the involved vein connections, such as the lumbosacral intervertebral veins;

Fig. C, continued: b, opportunities for a rapid and massive compensatory escape of blood from the upper craniovertebral space.

Fig. D. Spread of venous back-jets from abdomen into lower spinal canal (in black); leeway for subarachnoid fluid shifts, allowing for the expansion of lower spinal epidural veins (in grey); venous drainages providing for the compensatory venting of the craniovertebral space by prompt, massive evacuations of veins of the upper spinal canal and cranial cavity (in white).

About the Author

What first spurred the author on to his critique of the conventional understanding of multiple sclerosis was, admittedly, not the desire to point out the inadequacies which prevent a real success in the treatment of multiple sclerosis.

Neither was it a special acquaintance with neuropathology, immunology, or other related fields of knowledge that enabled him to find out how the multiple sclerosis-specific lesion developments are to be explained.

The story began in 1973, at the University of Innsbruck, when F. Alfons Schelling, M.D. began investigations into the causes and consequences of the enormous individual differences in the widths of the venous outlets of the human skull. The results of this study appeared, in 1978, in the official organ of the German-speaking Anatomical Societies, the "Anatomischer Anzeiger".

F.A. Schelling's 1981 discovery, at the Hospital for Nervous Diseases in Salzburg, of a striking widening of the main venous passageways through the skulls in victims of multiple sclerosis were to occupy the author's thoughts through the following decades of his quite diversified medical career. And in putting together, bit by bit, all the observations on the venous involvement in the emergence of the specific, and, in particular, cerebral lesions of multiple sclerosis, he was able to recognize their causes.

In this book, all of the relevant results of the author's comprehensive re-evaluation of the literature on multiple sclerosis are made public for the first time.

Born in Austria in 1945, Dr. Schelling is married and has four children. He lives in the western Austrian town of Dornbirn.

Contact

This presentation aims at contributing towards resolving some of the most burning issues of multiple sclerosis research. Of central importance is the pathogenic relevance of flow inversions pushing back into particular venous drainages of the brain or spinal canal. The author is wholeheartedly convinced that by demonstrating the impact of these venous flow-inversions and their cerebrospinal fluid displacements, directly in vivo and/or at post mortem, the relevant venous anomalies can better be understood and remedied. Any feedback on the part of the reader would be very highly appreciated, including critical commentaries which might help to clarify many of the issues surrounding multiple sclerosis.

Dr. F. Alfons Schelling, M.D.

Arlbergstr. 3

A-6850 Dornbirn

dr.franz.schelling@aon.at